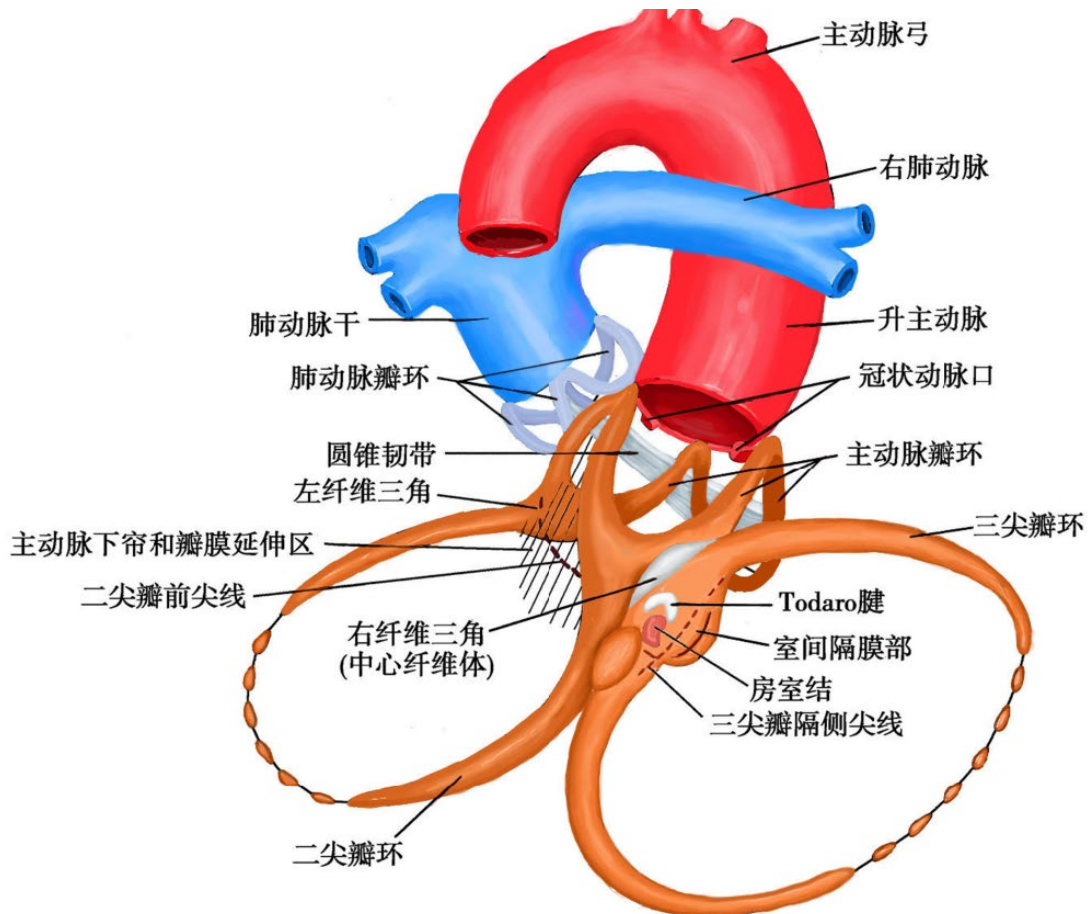
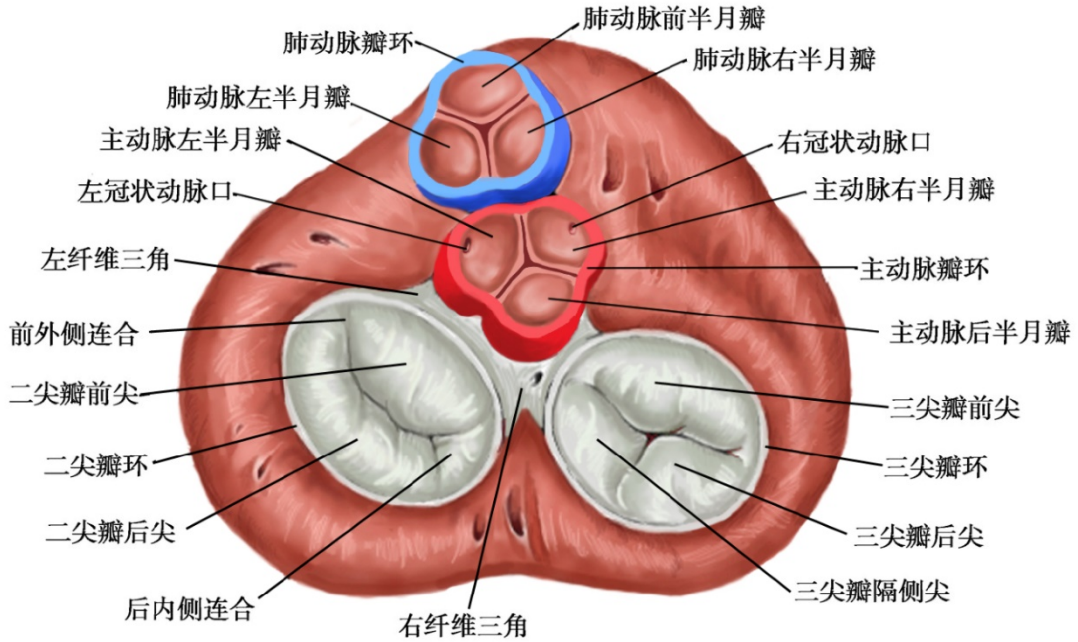
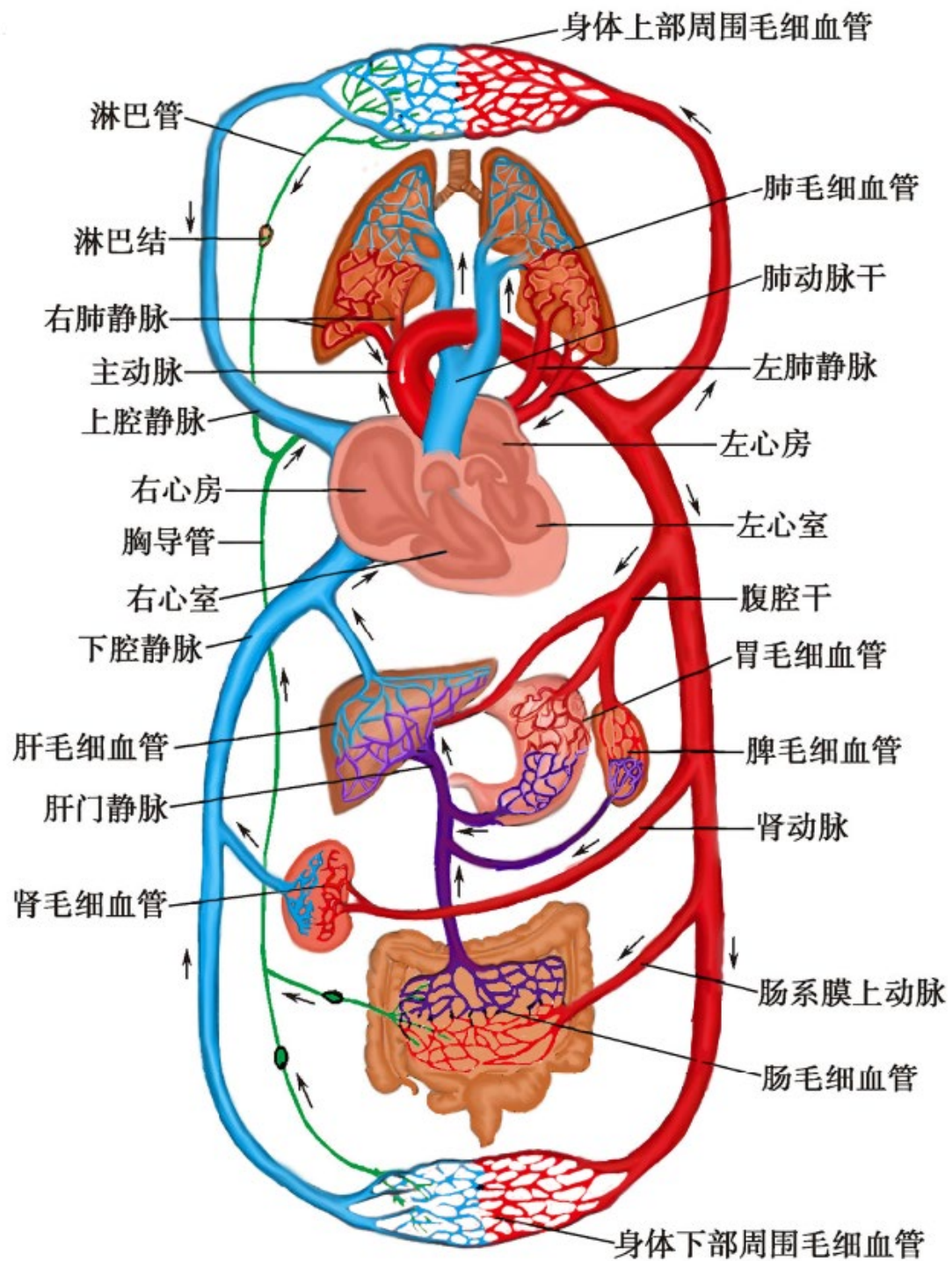
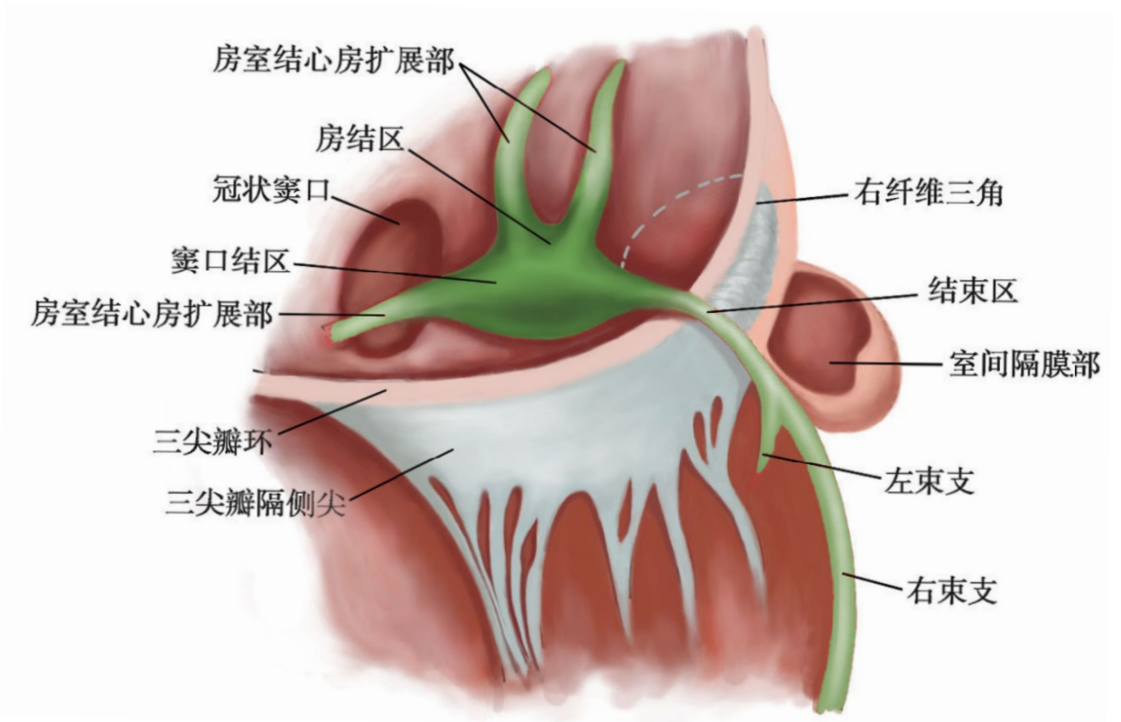
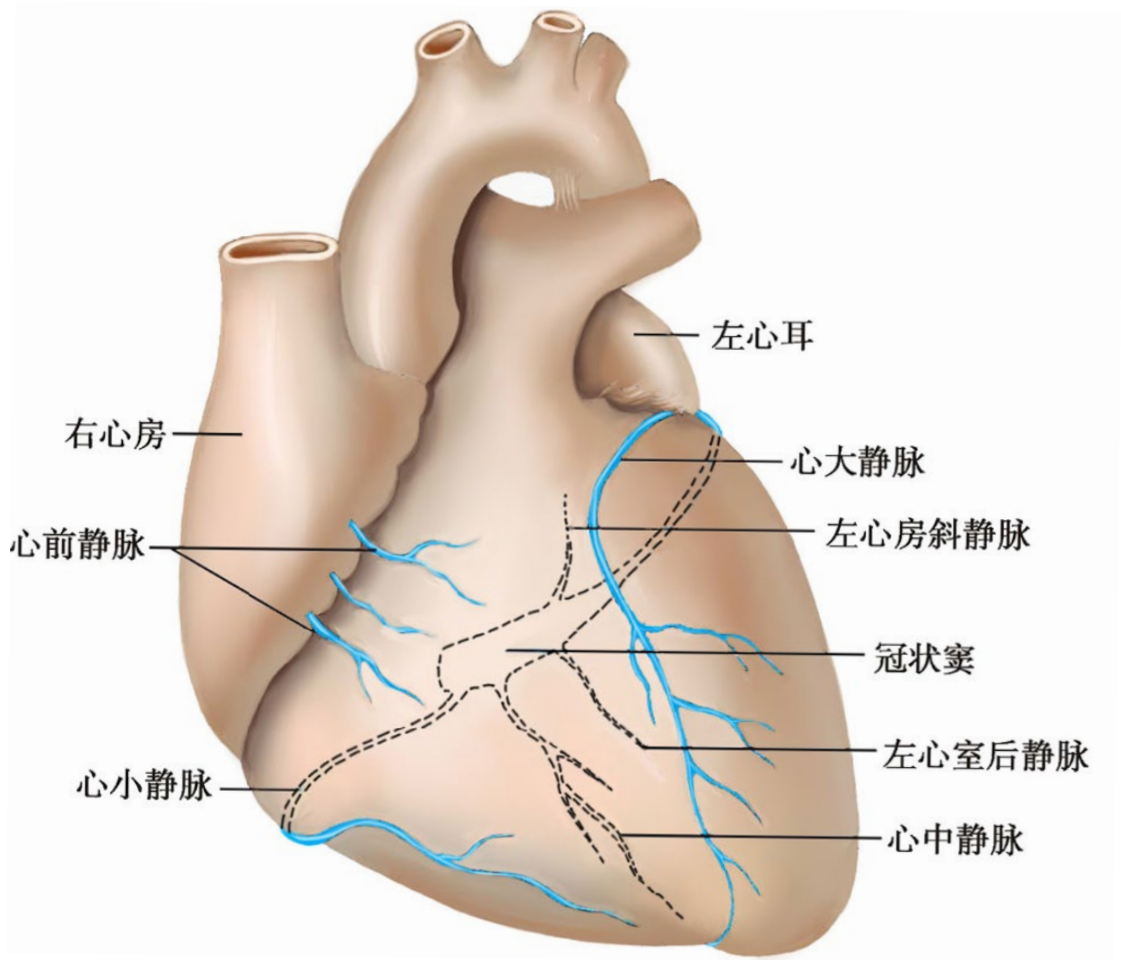
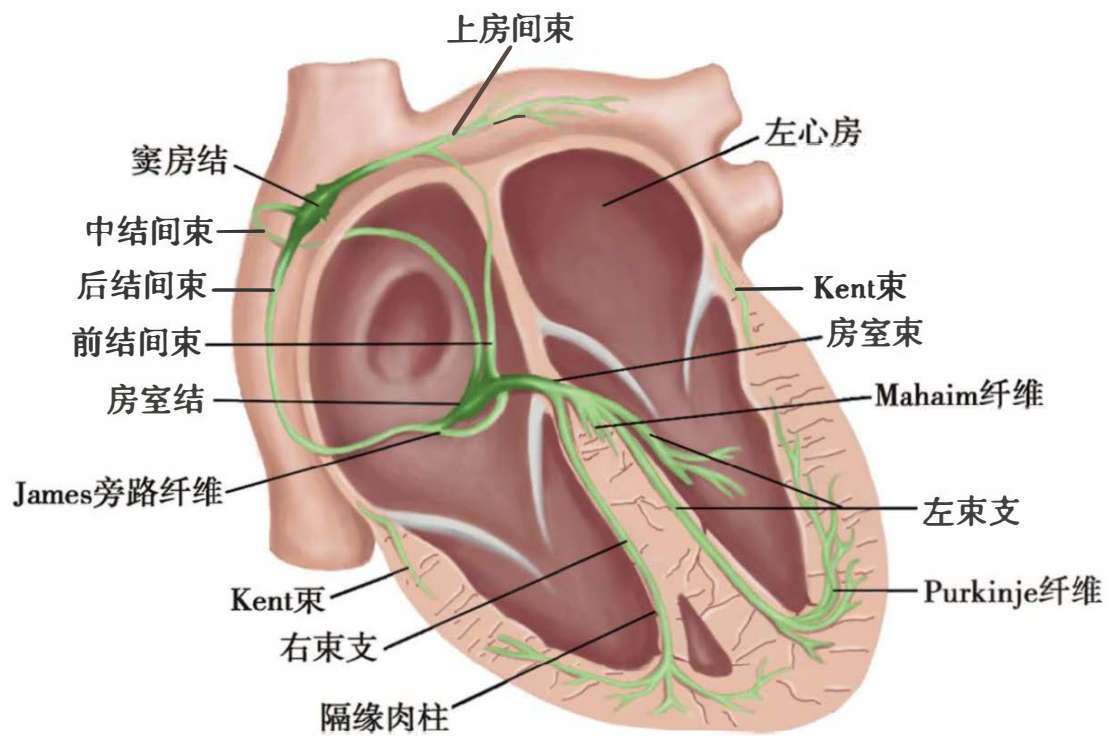
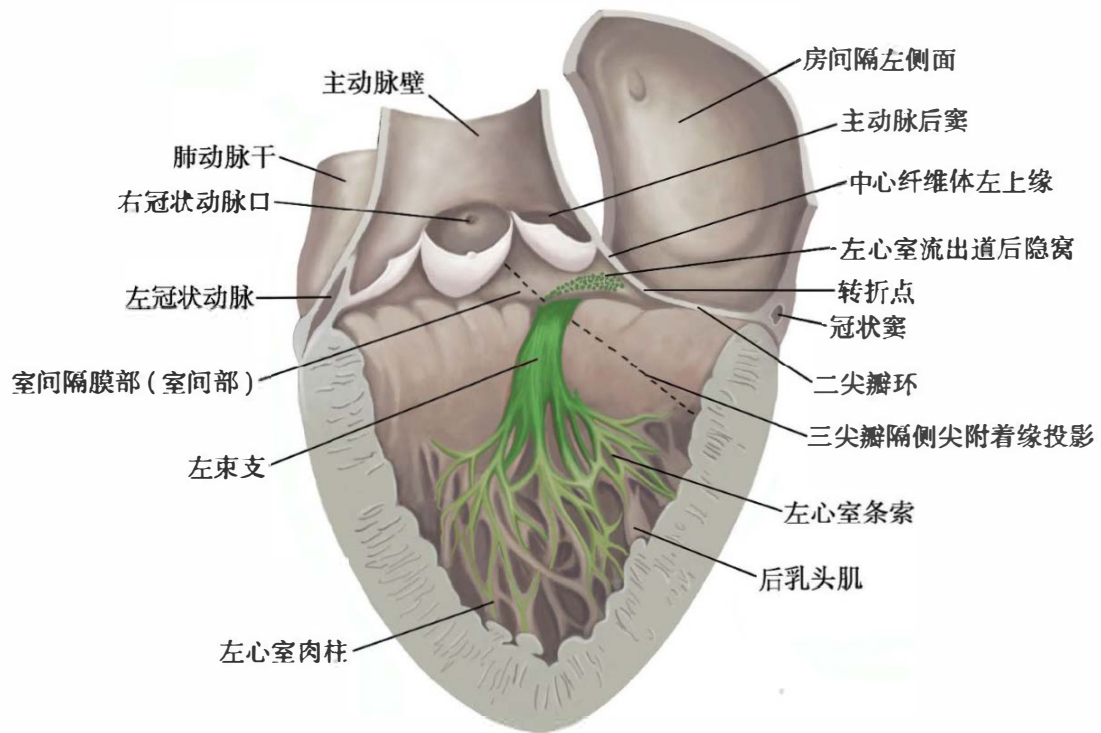


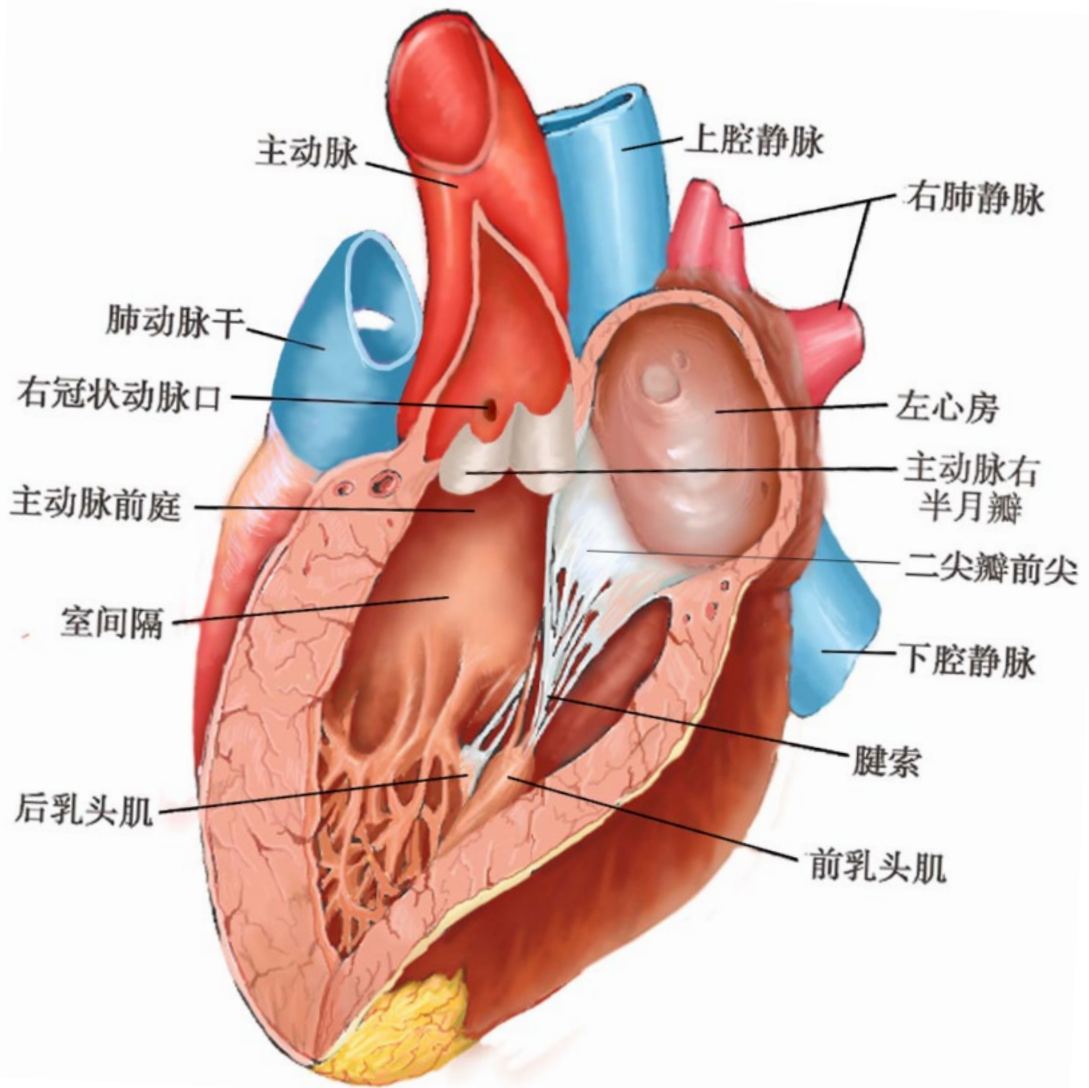
心血管

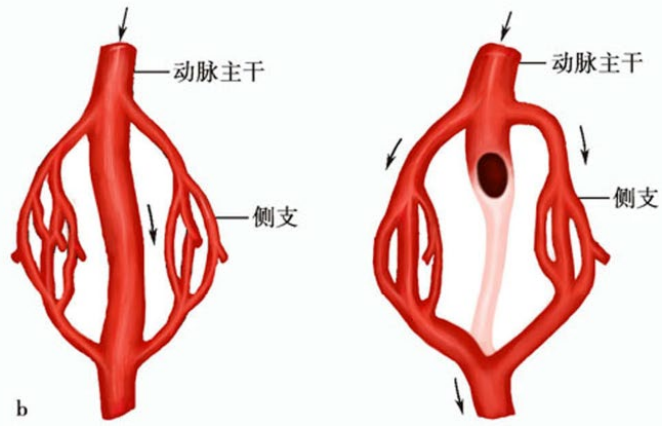
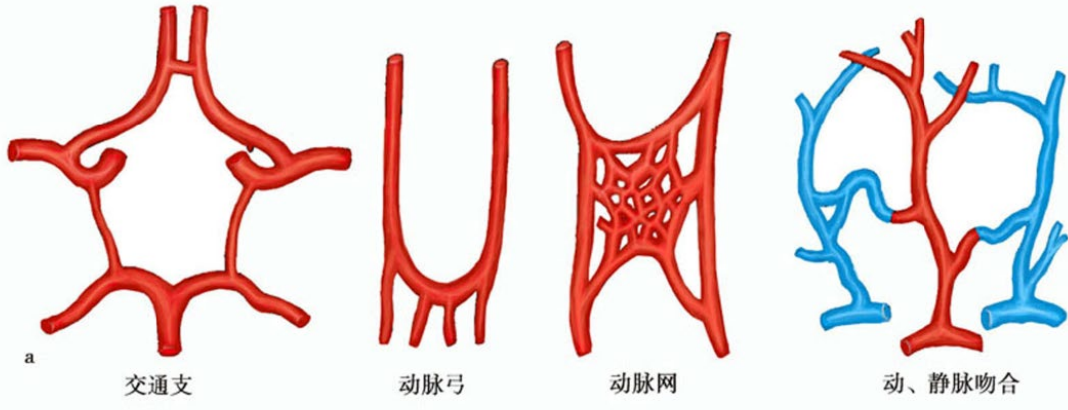


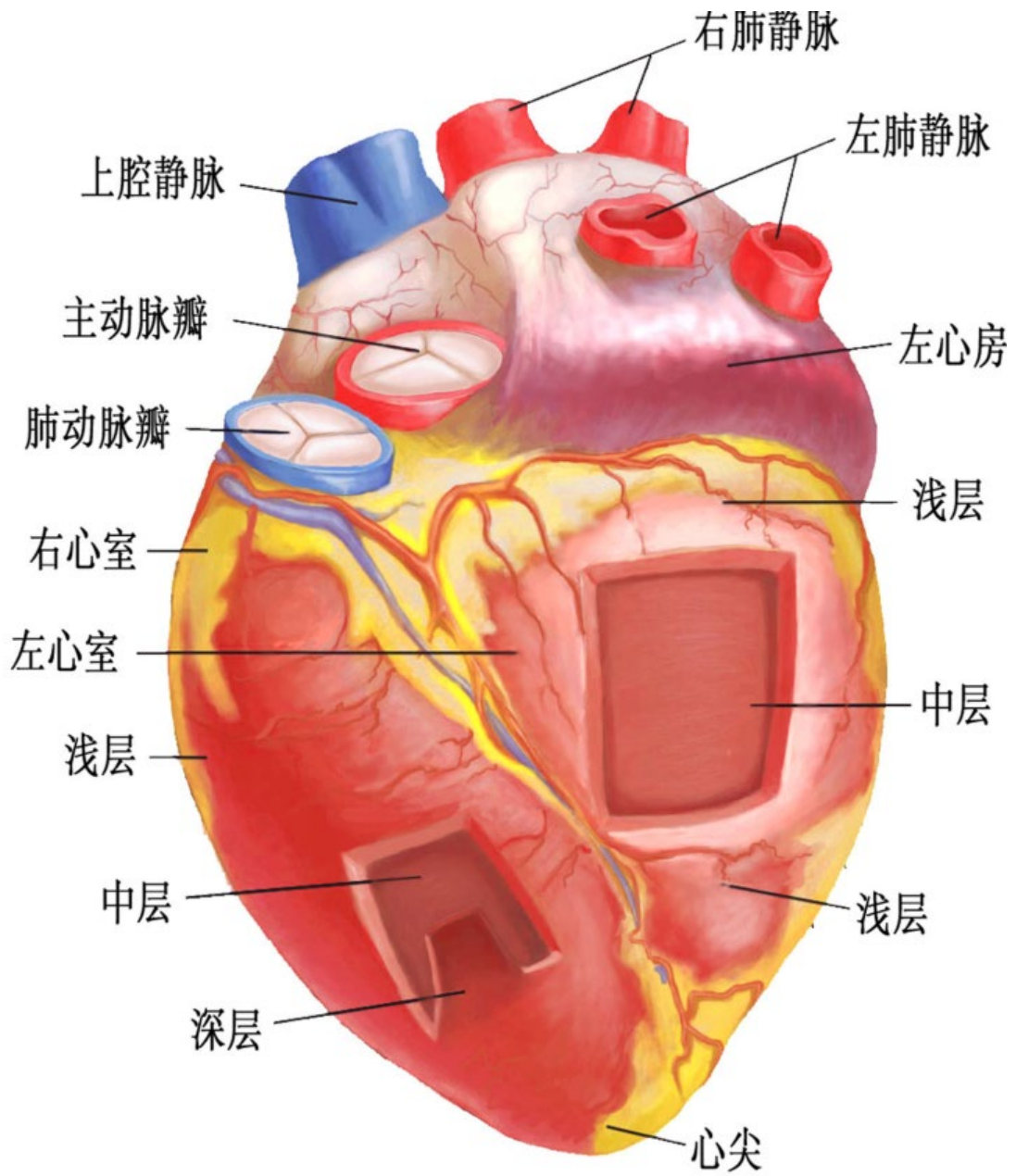


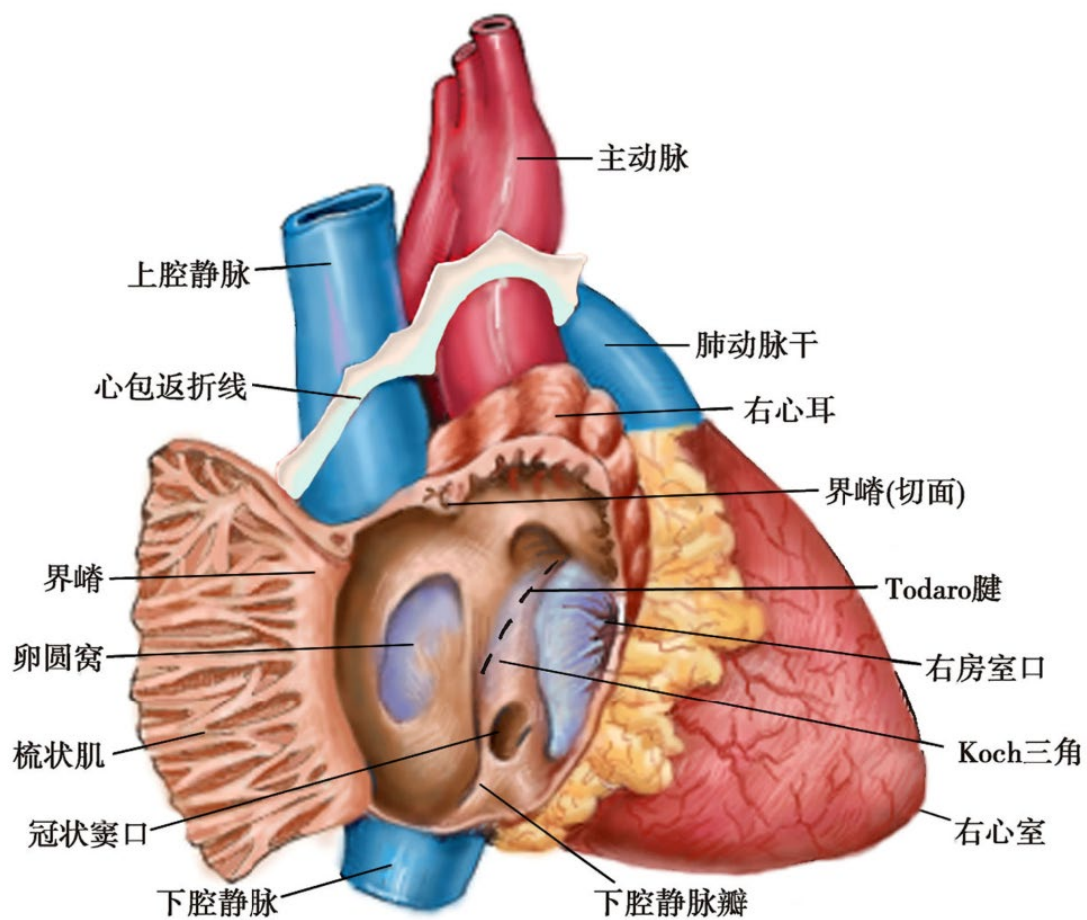


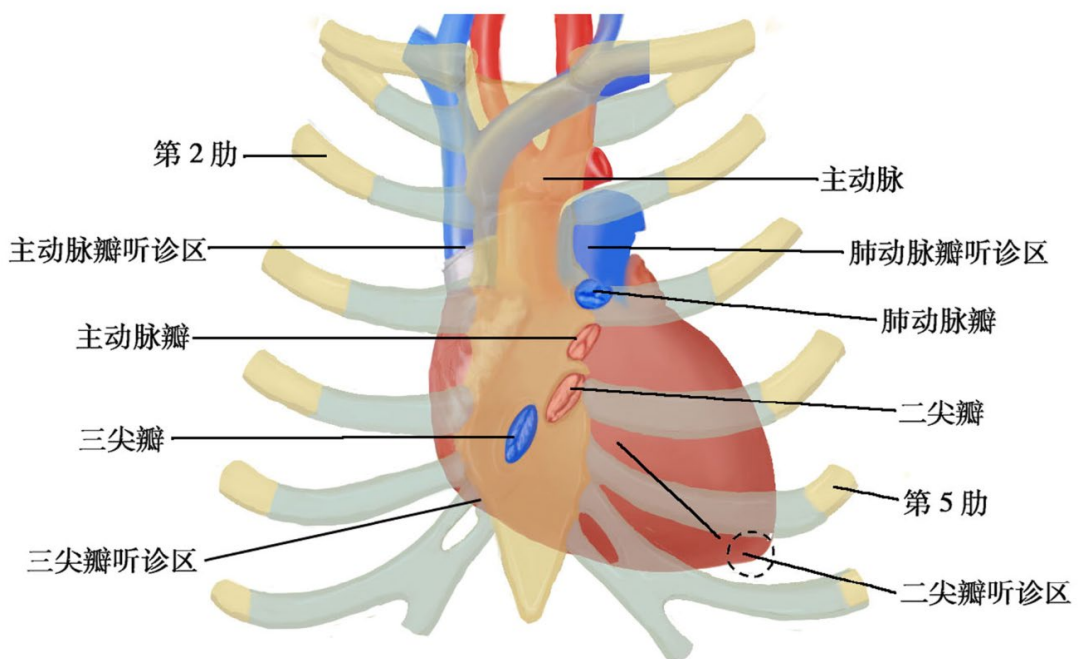
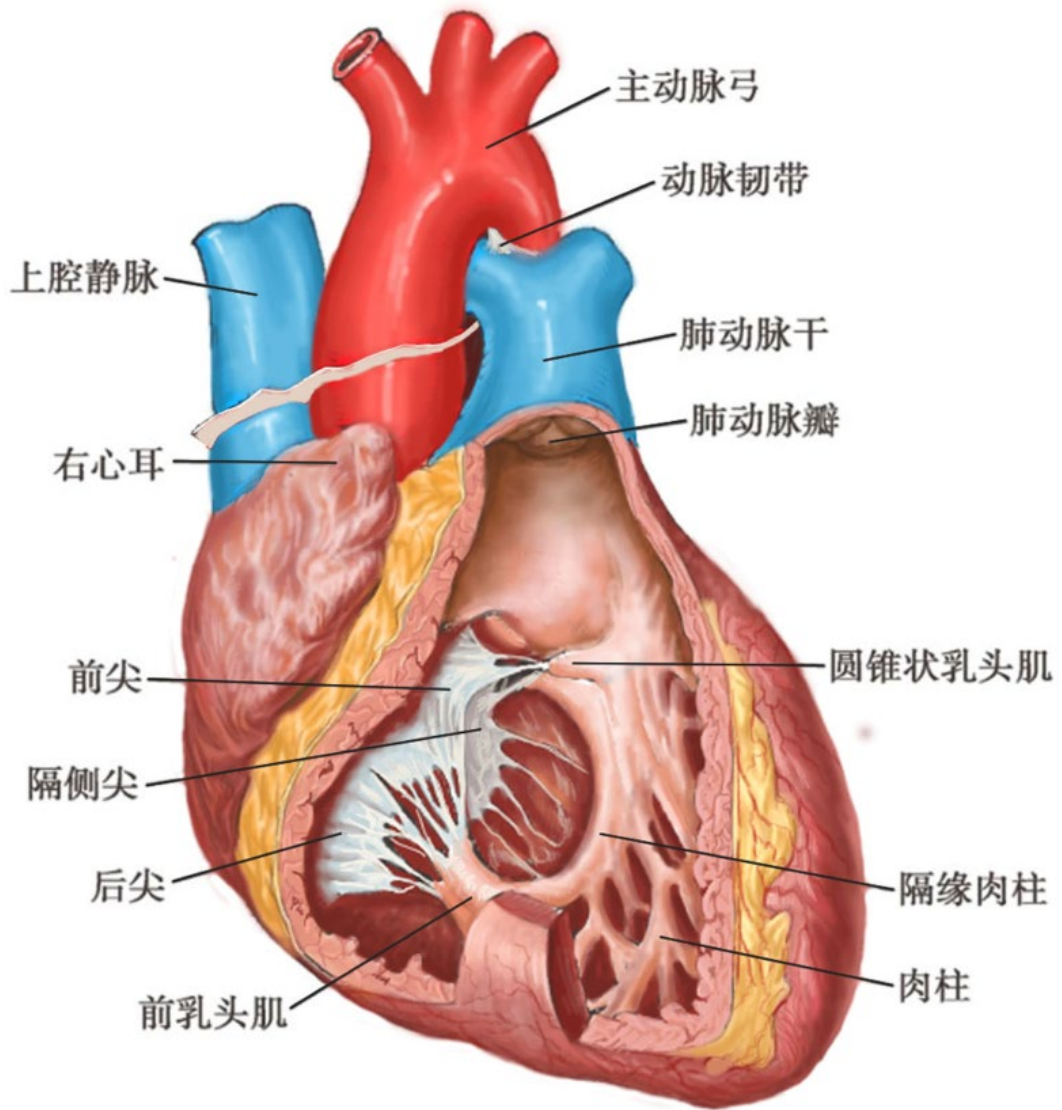


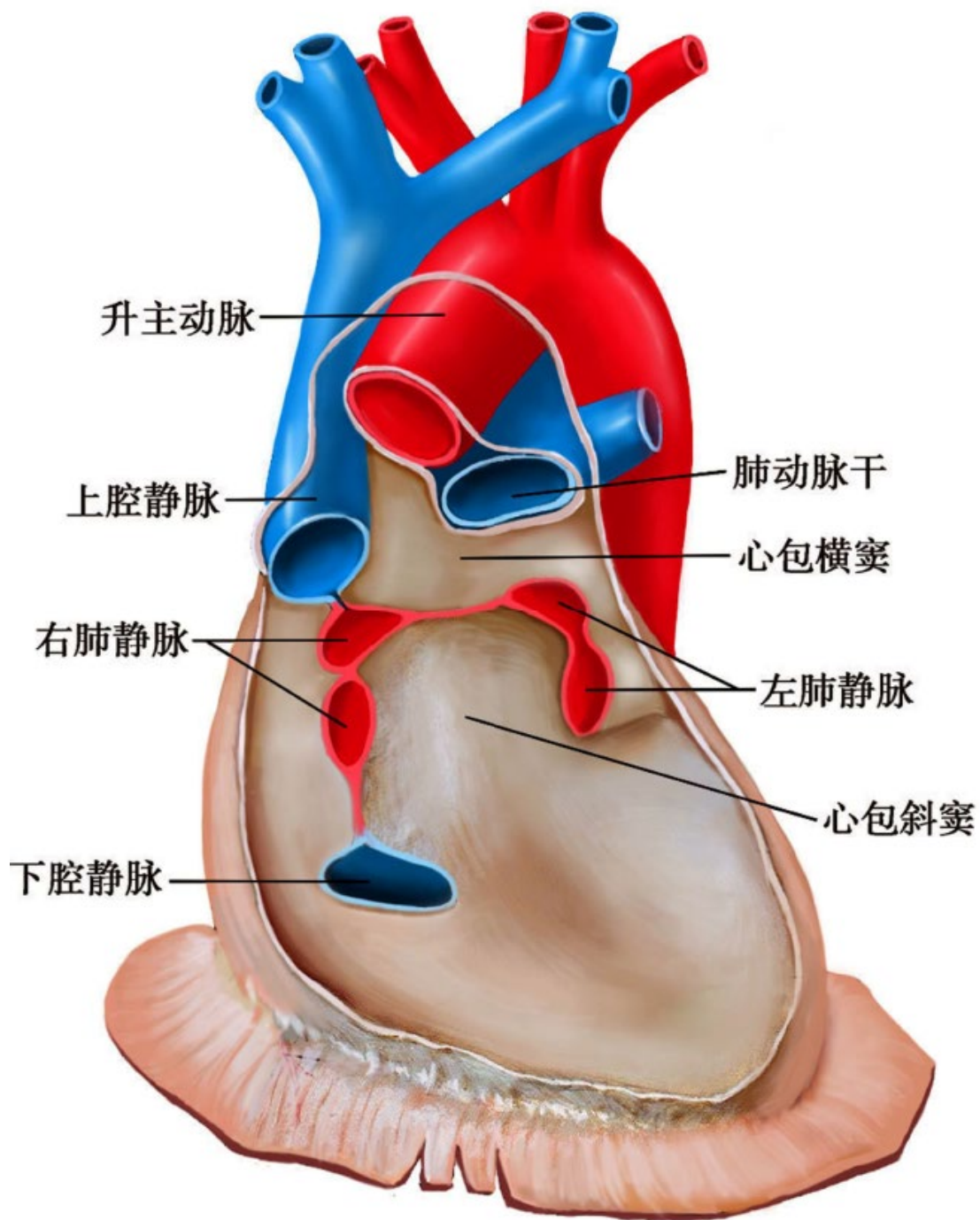


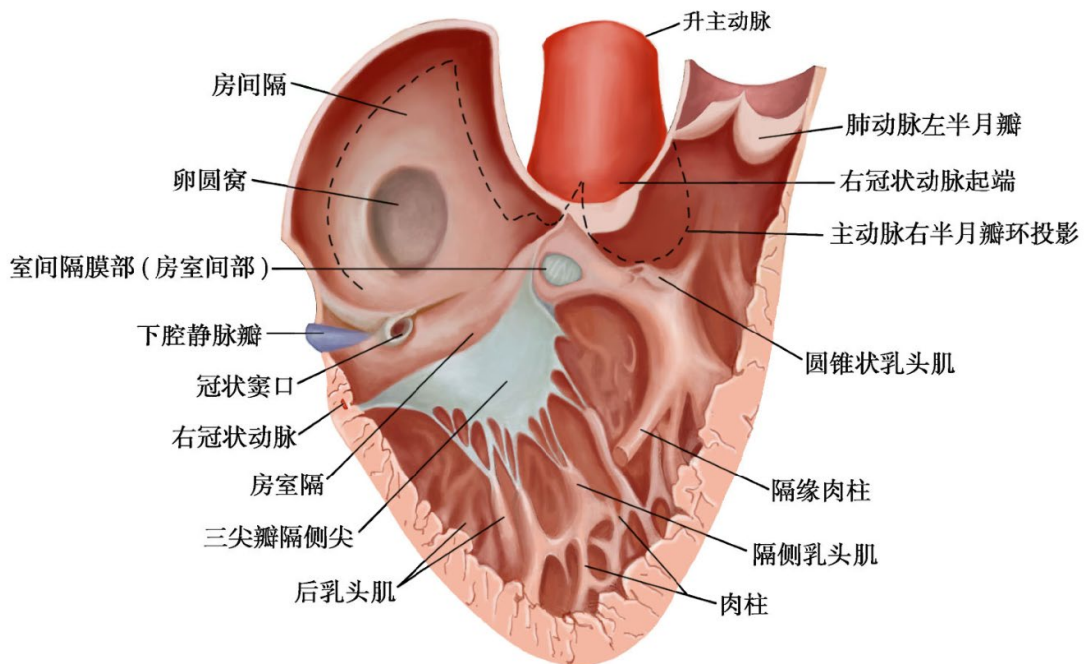
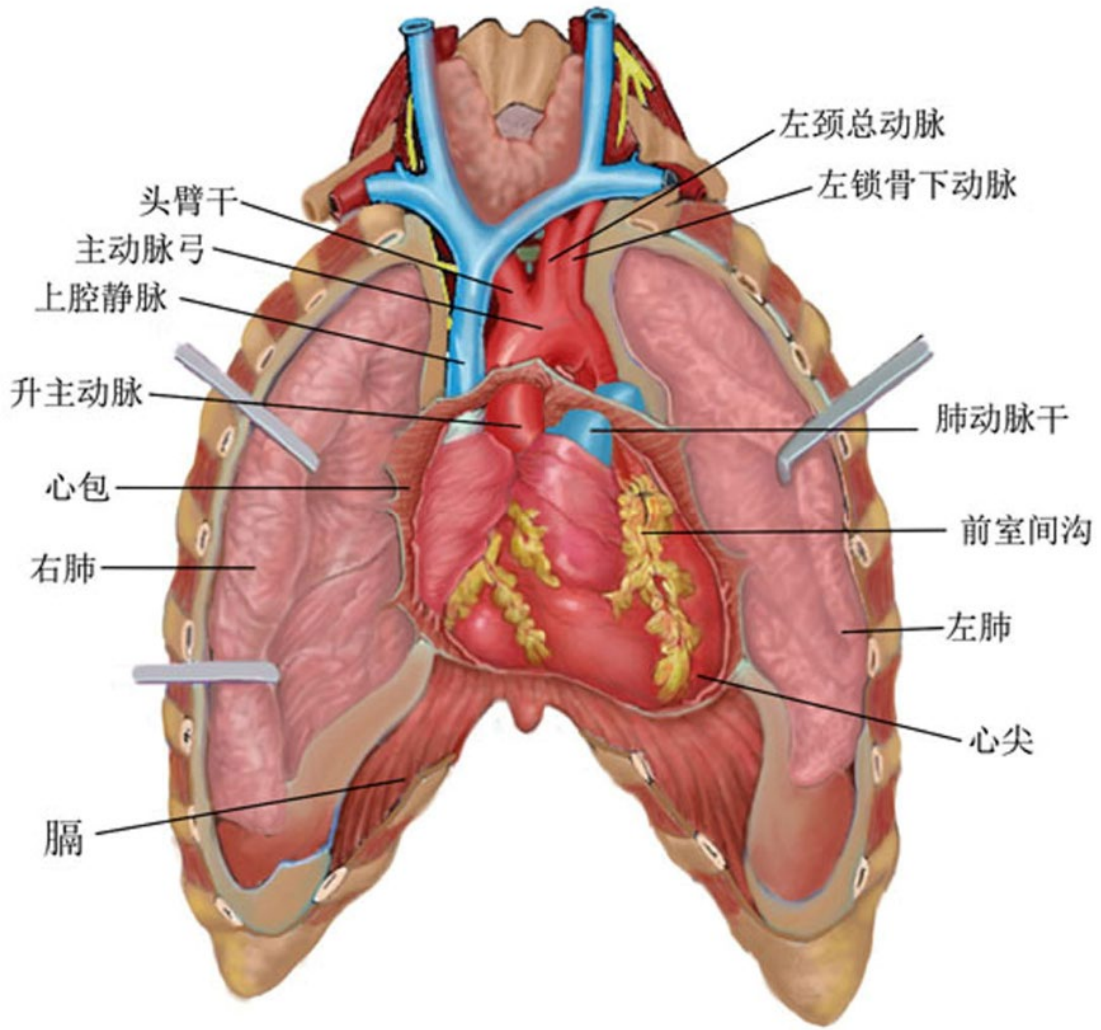


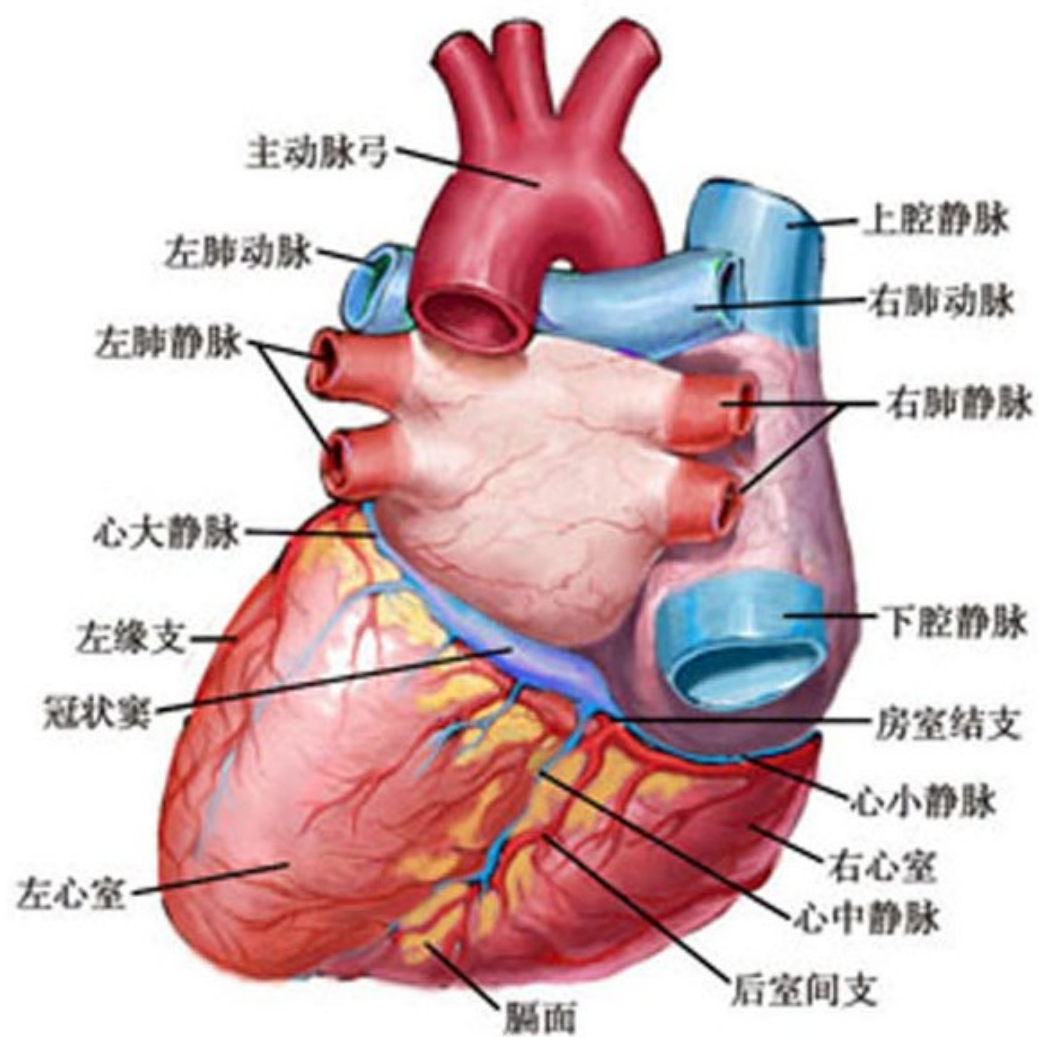


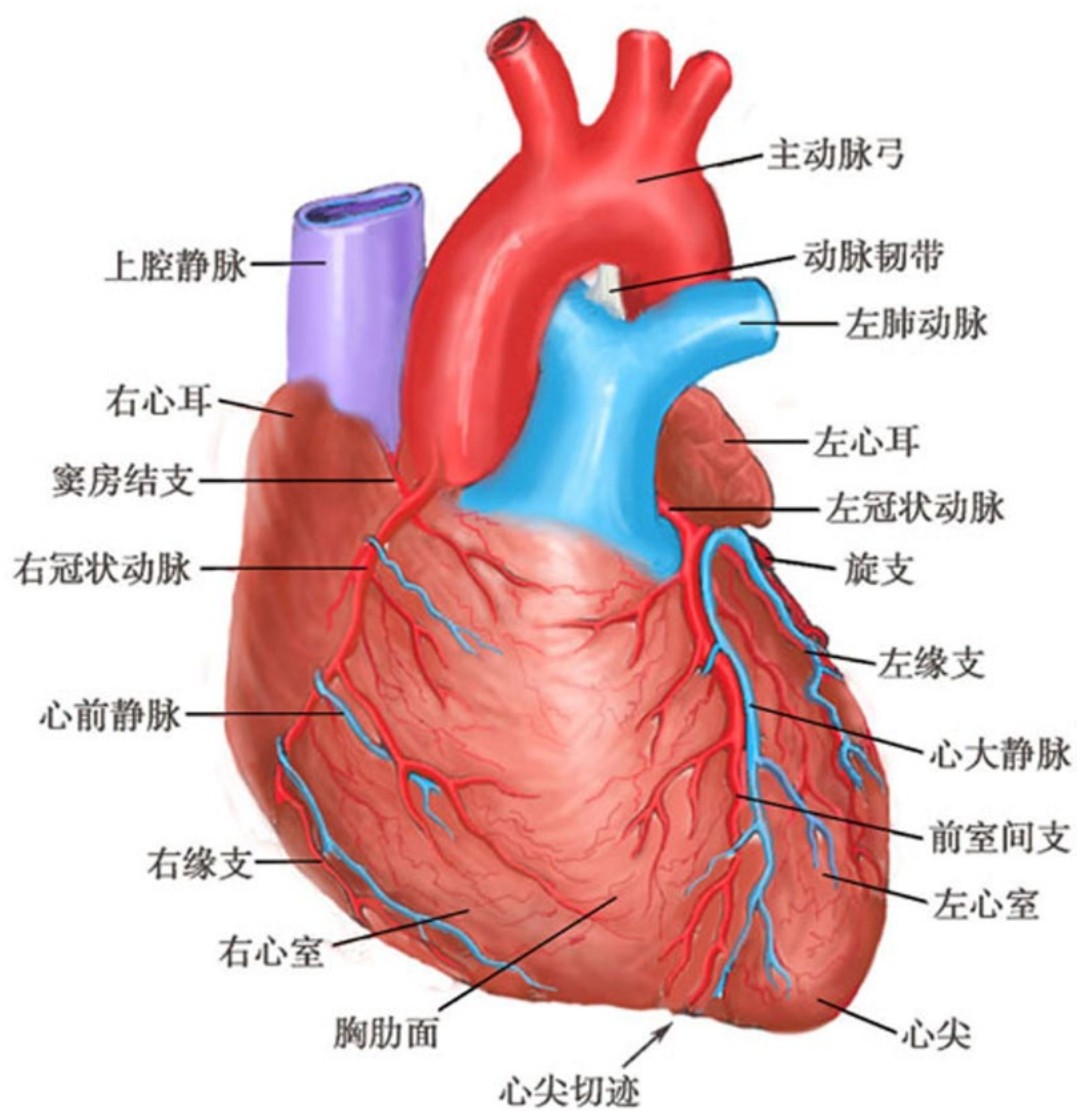


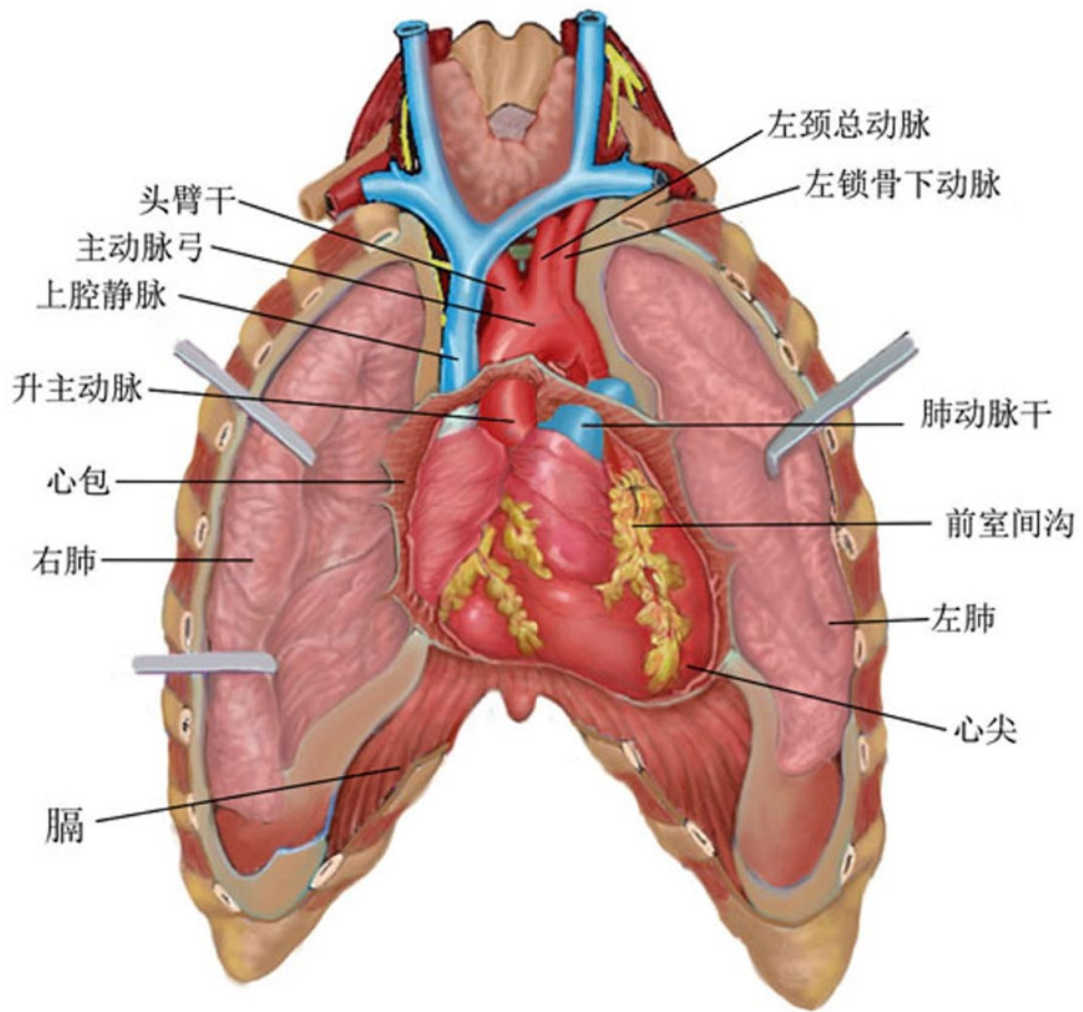




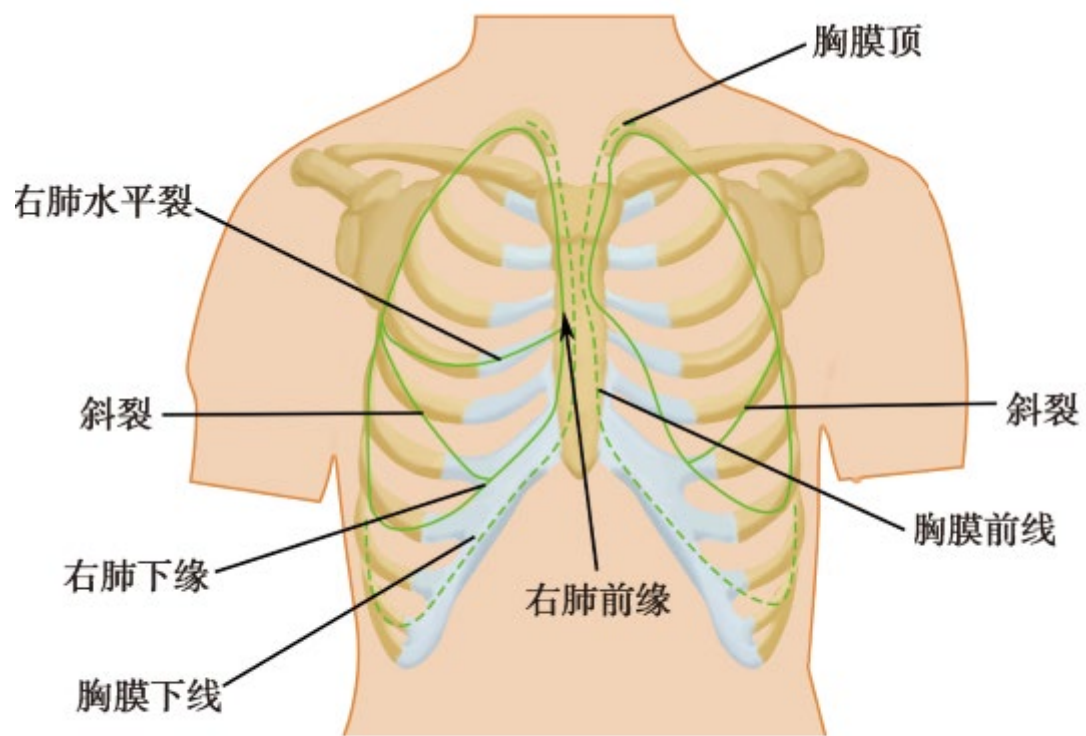




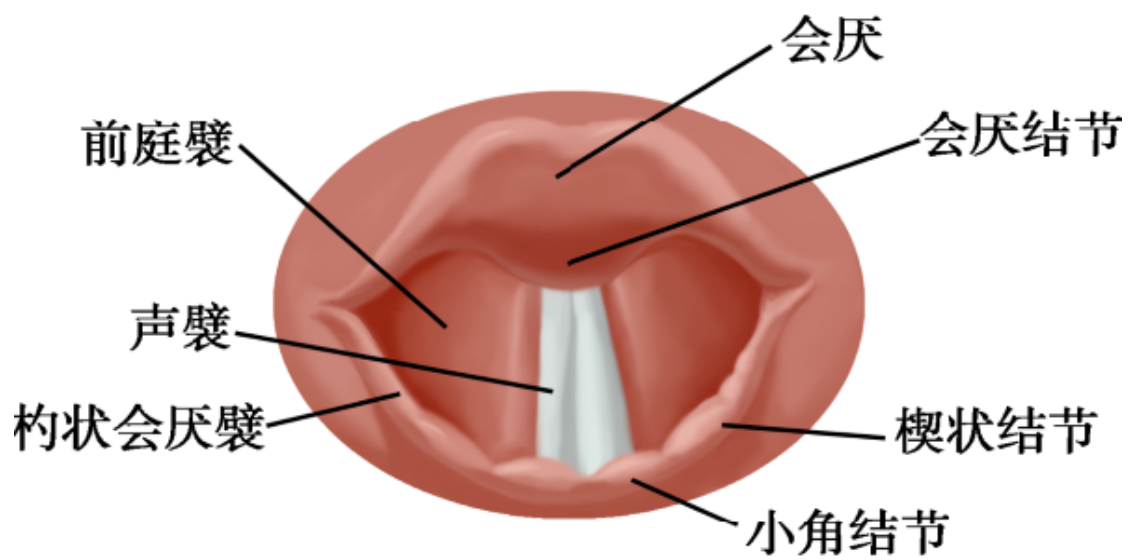




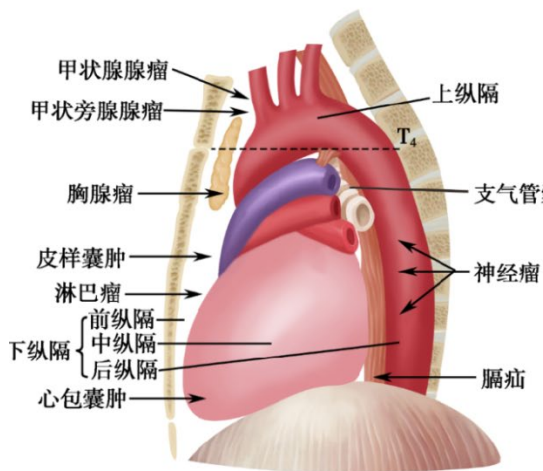
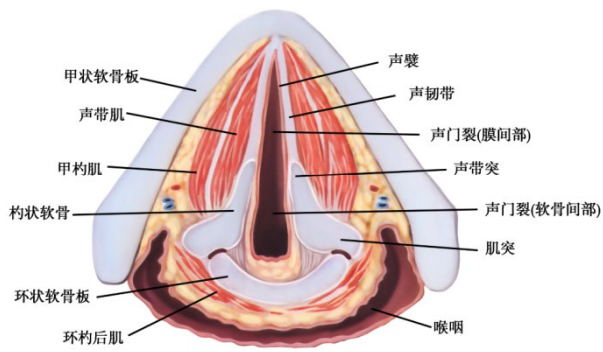
呼吸



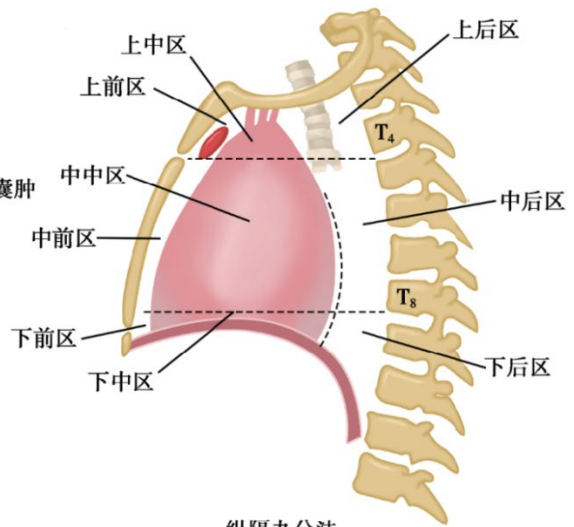
前面



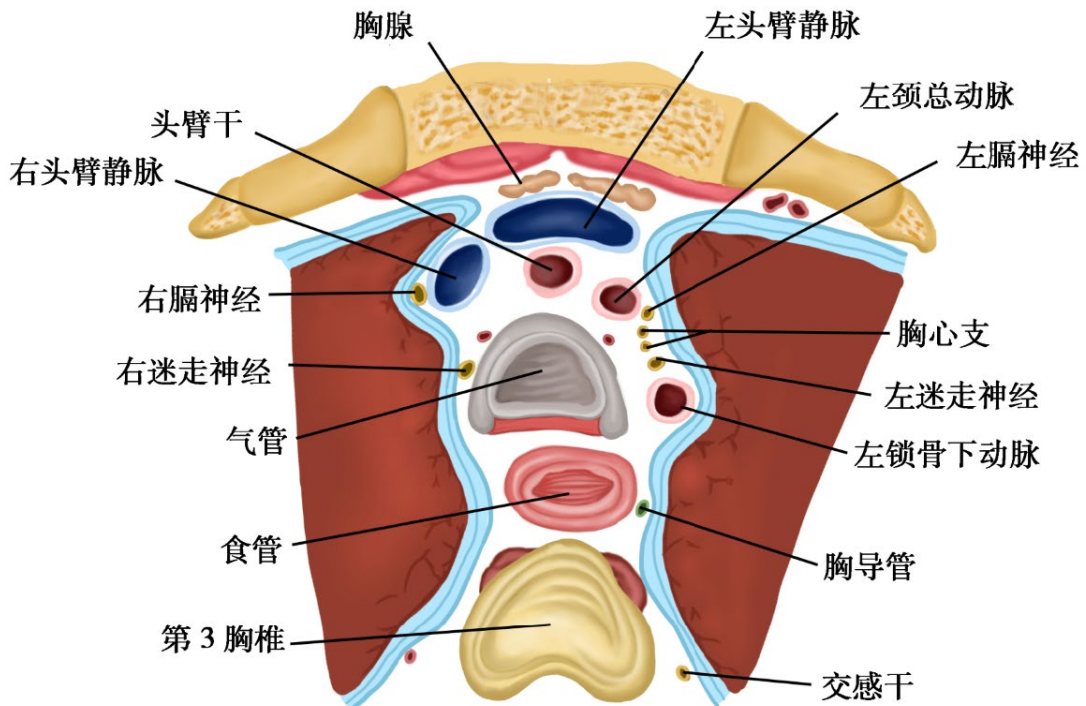
发声时



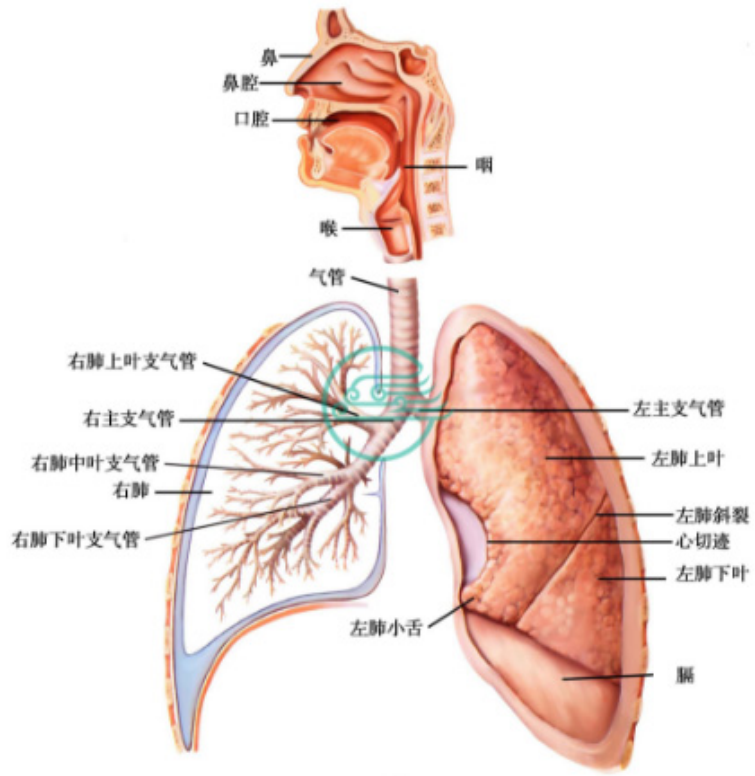
纵隔四分法



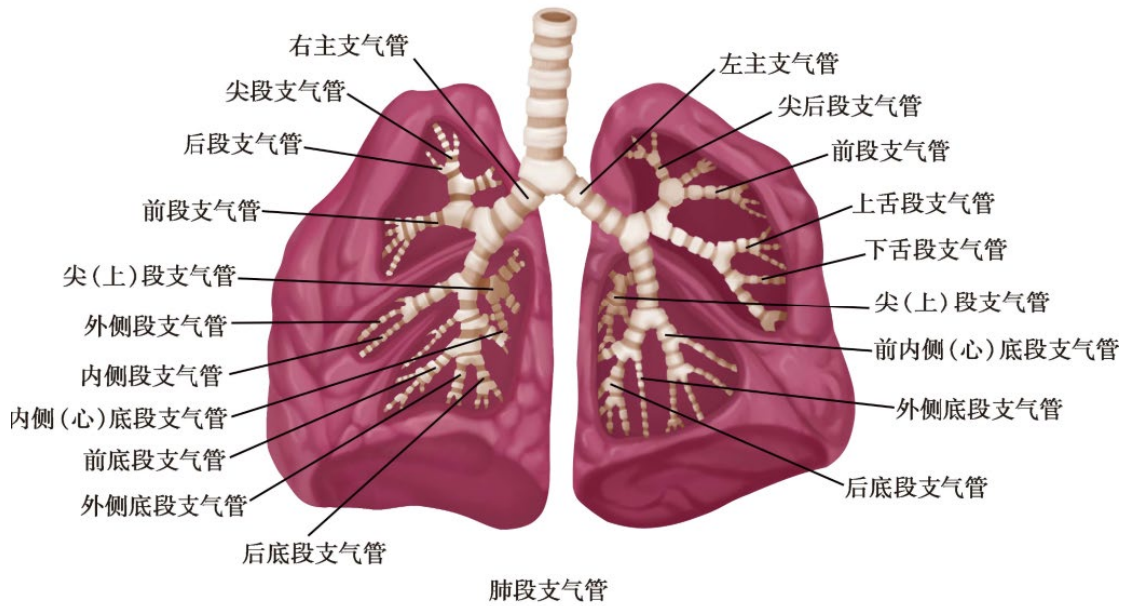
纵隔九分法

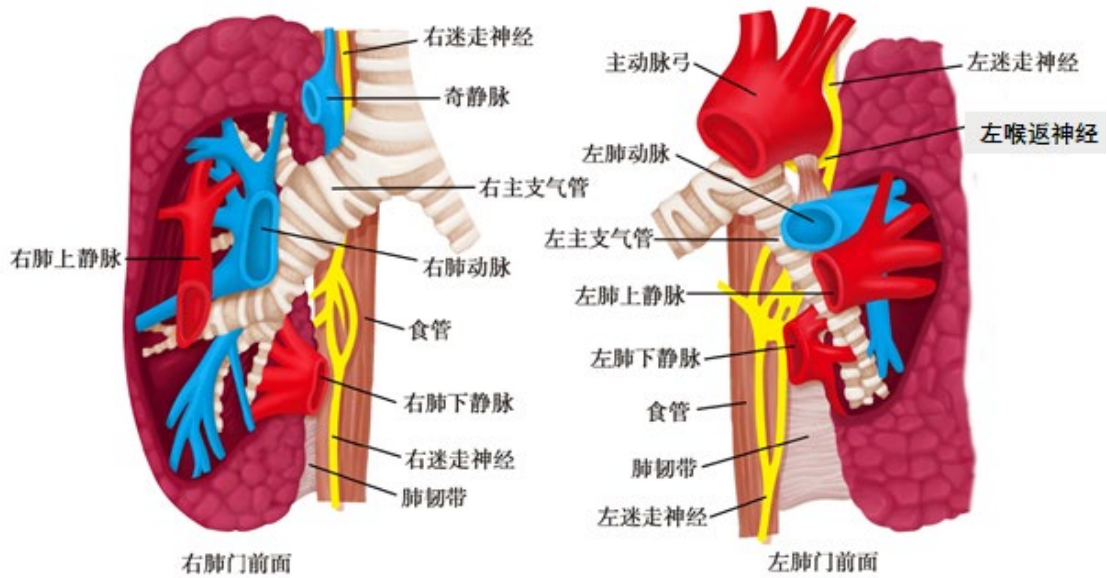
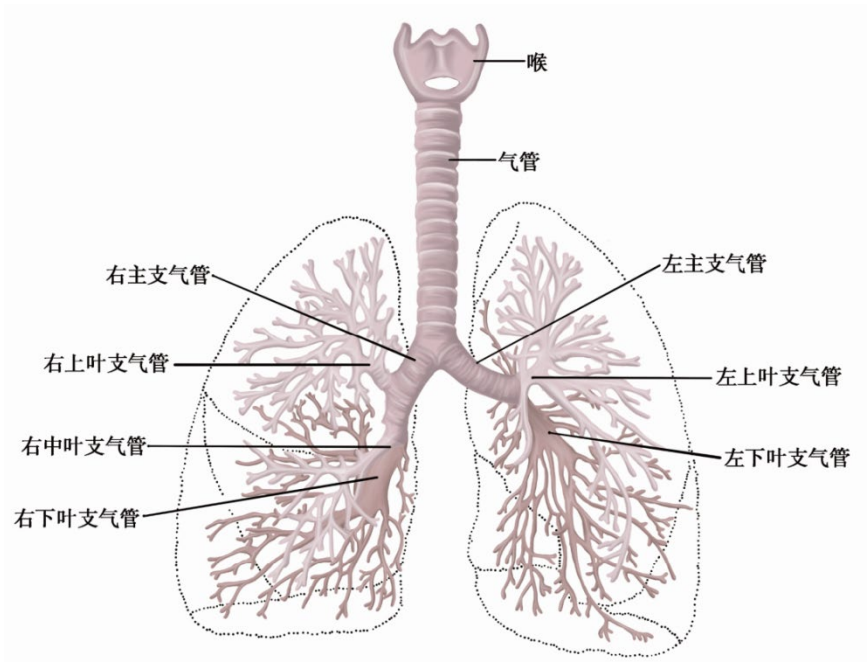


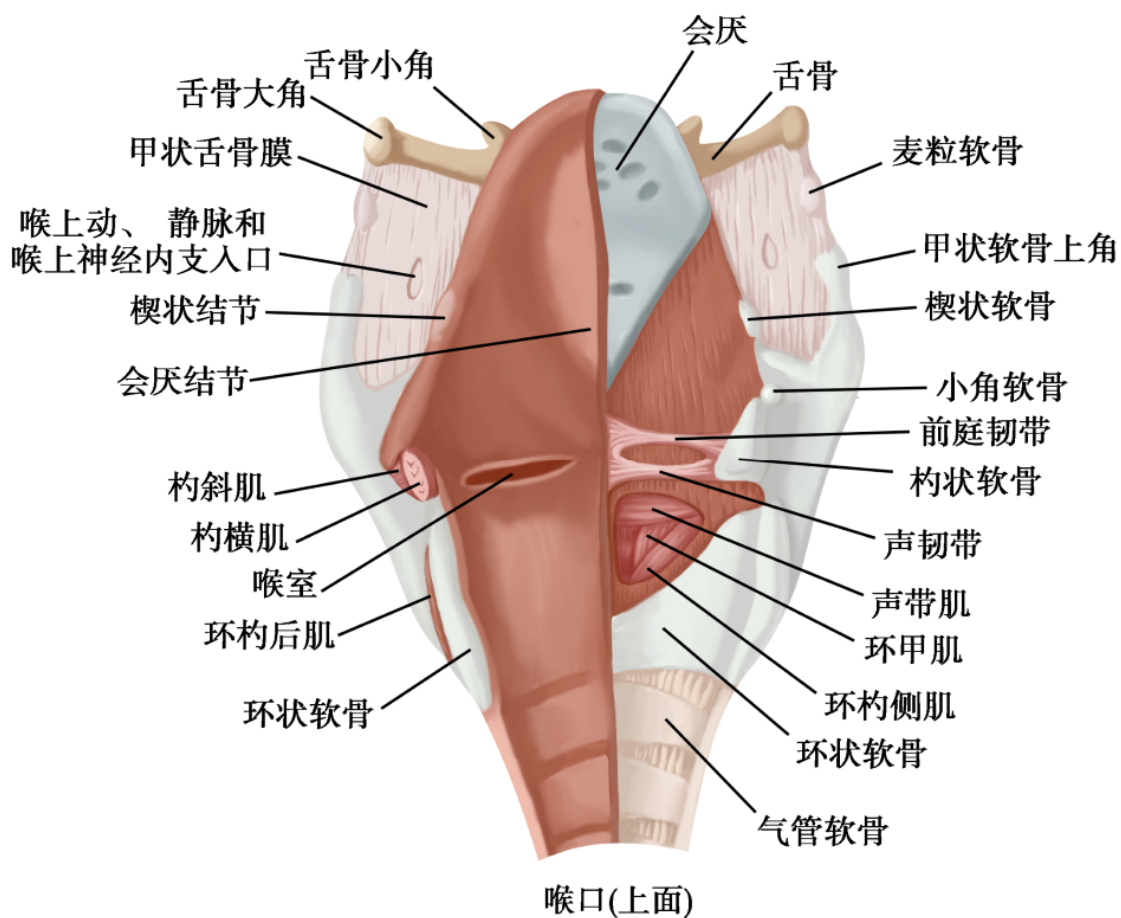
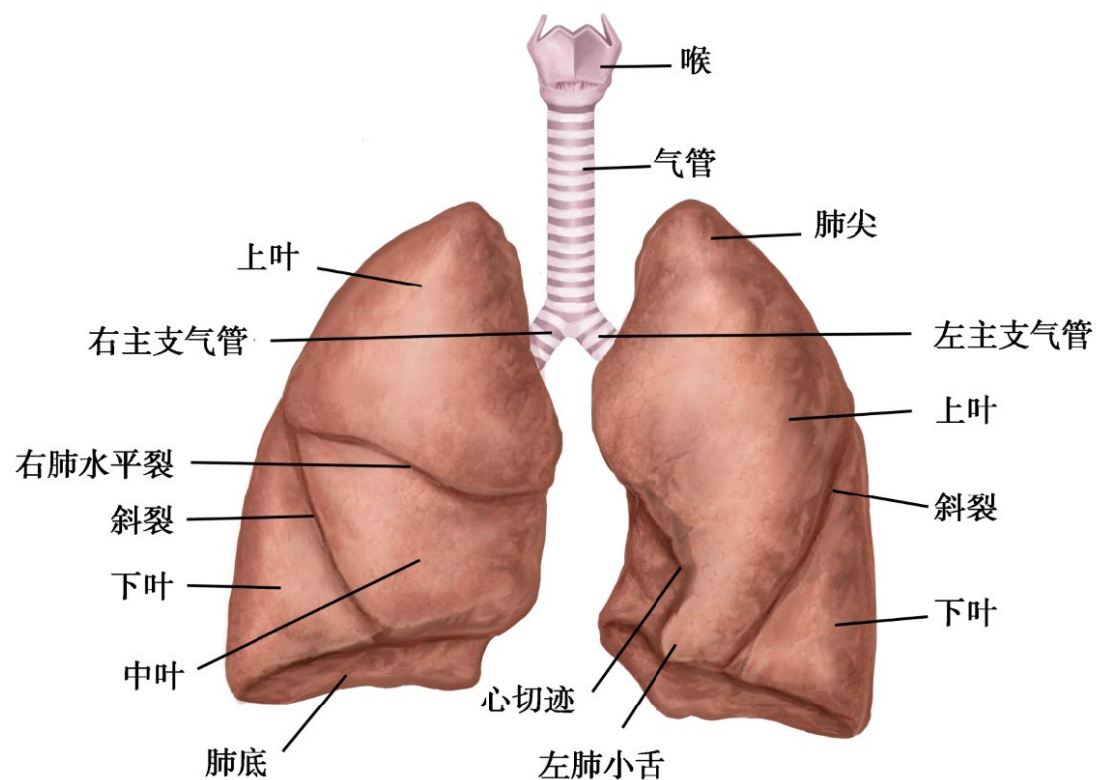
6-1 呼吸系统全貌 【资源ID】 757973



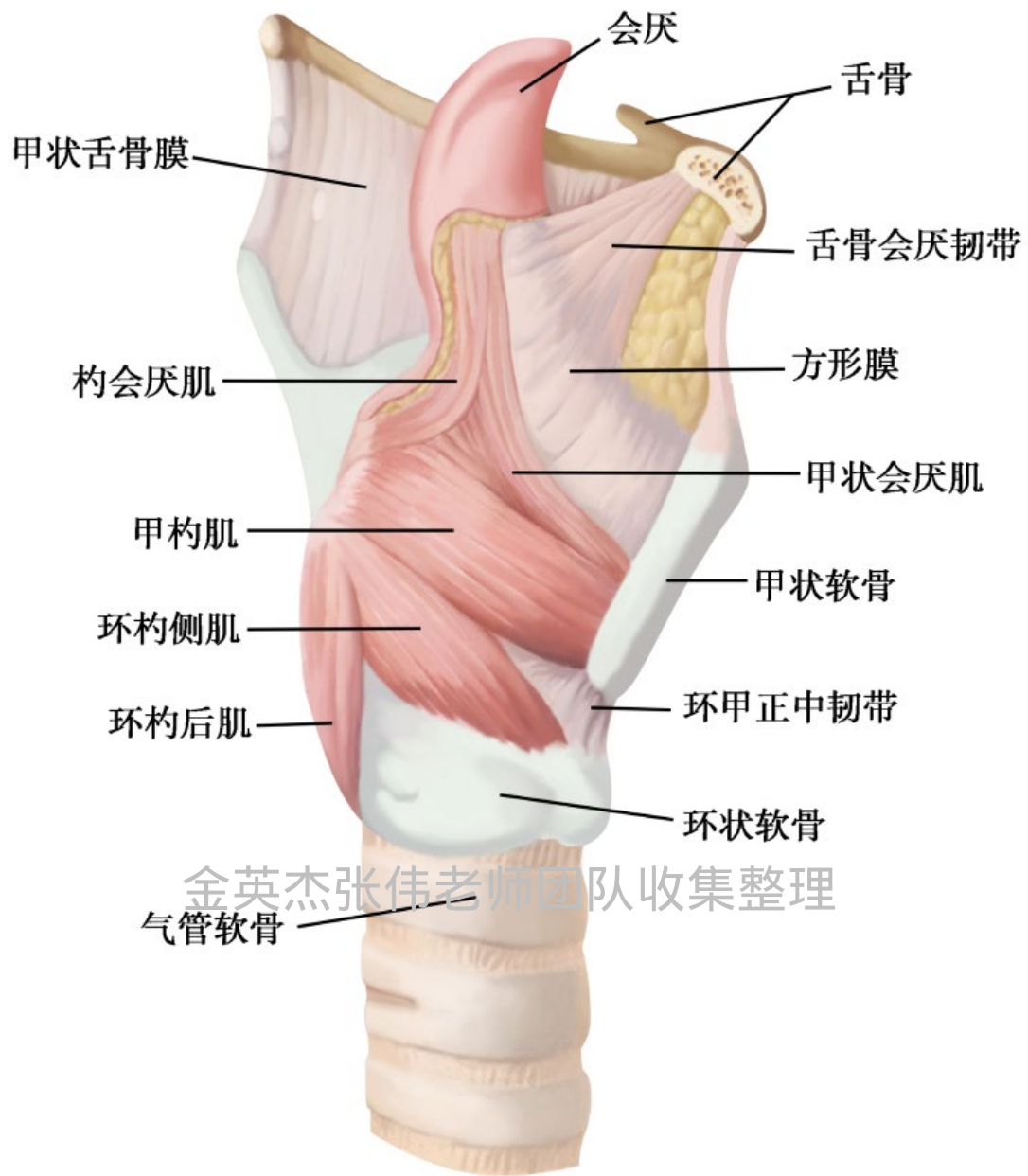
B

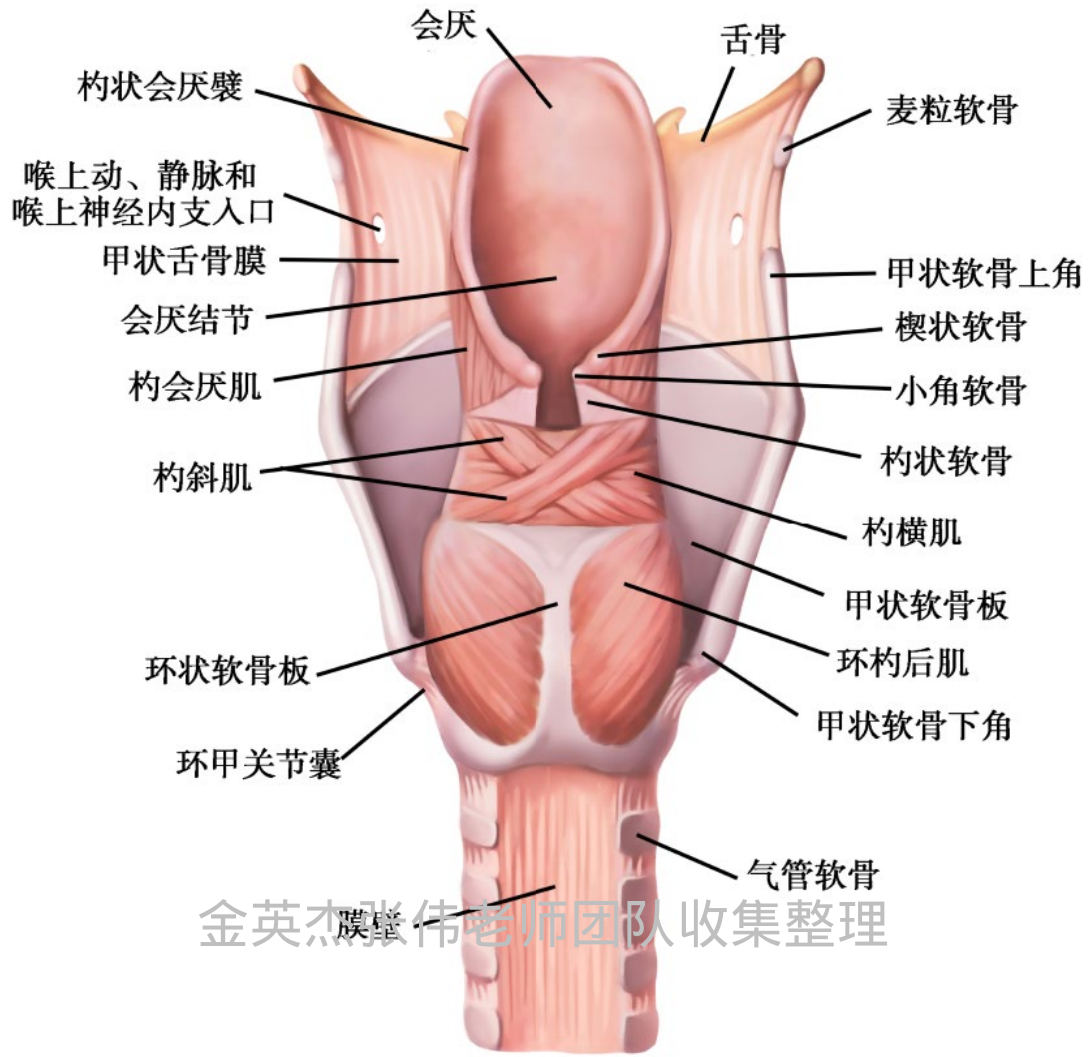




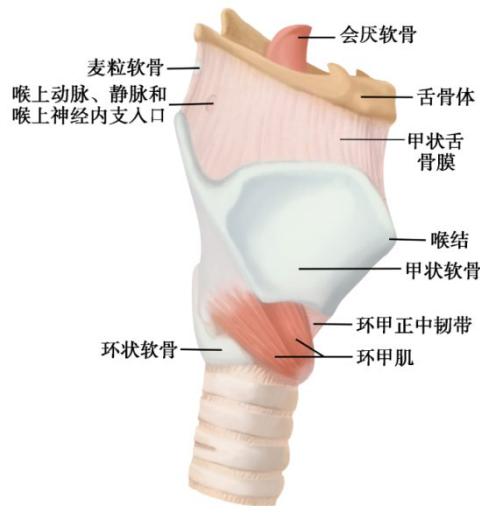


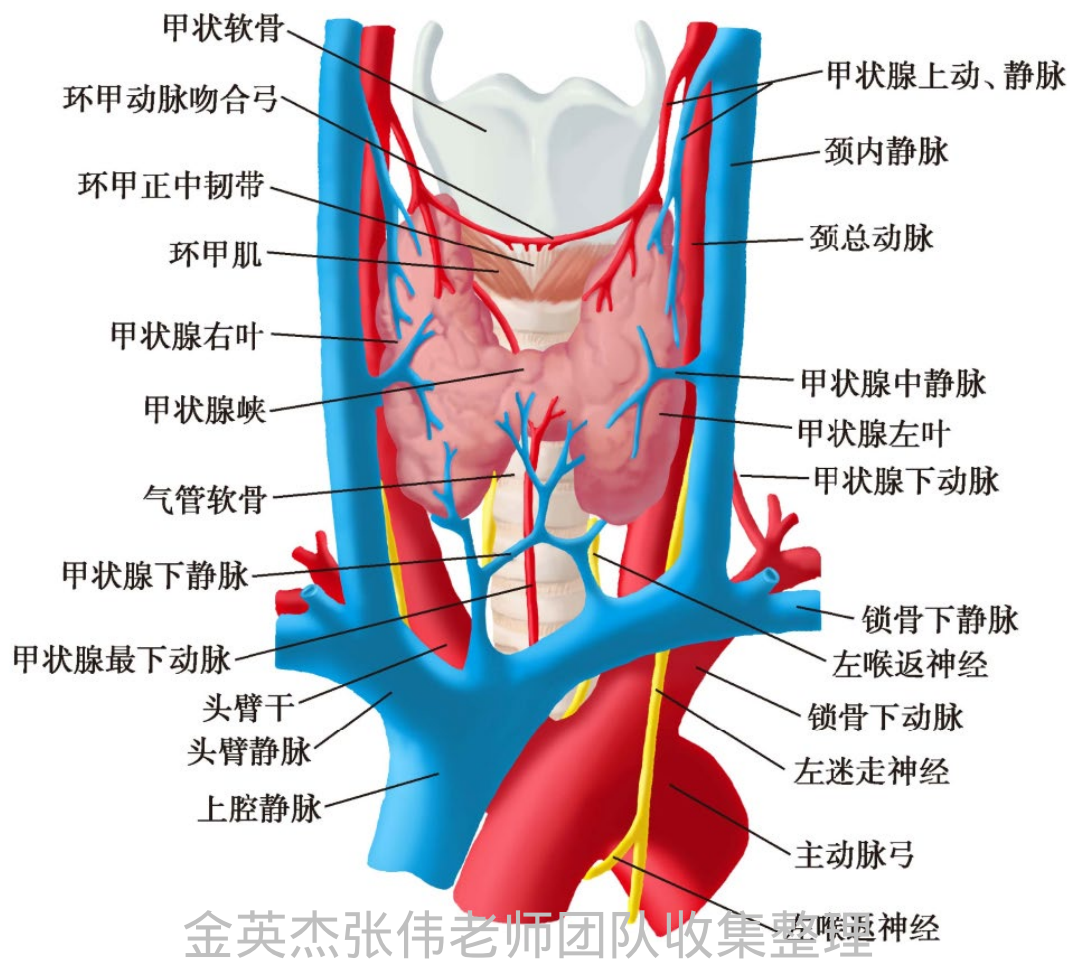
喉口(上面)

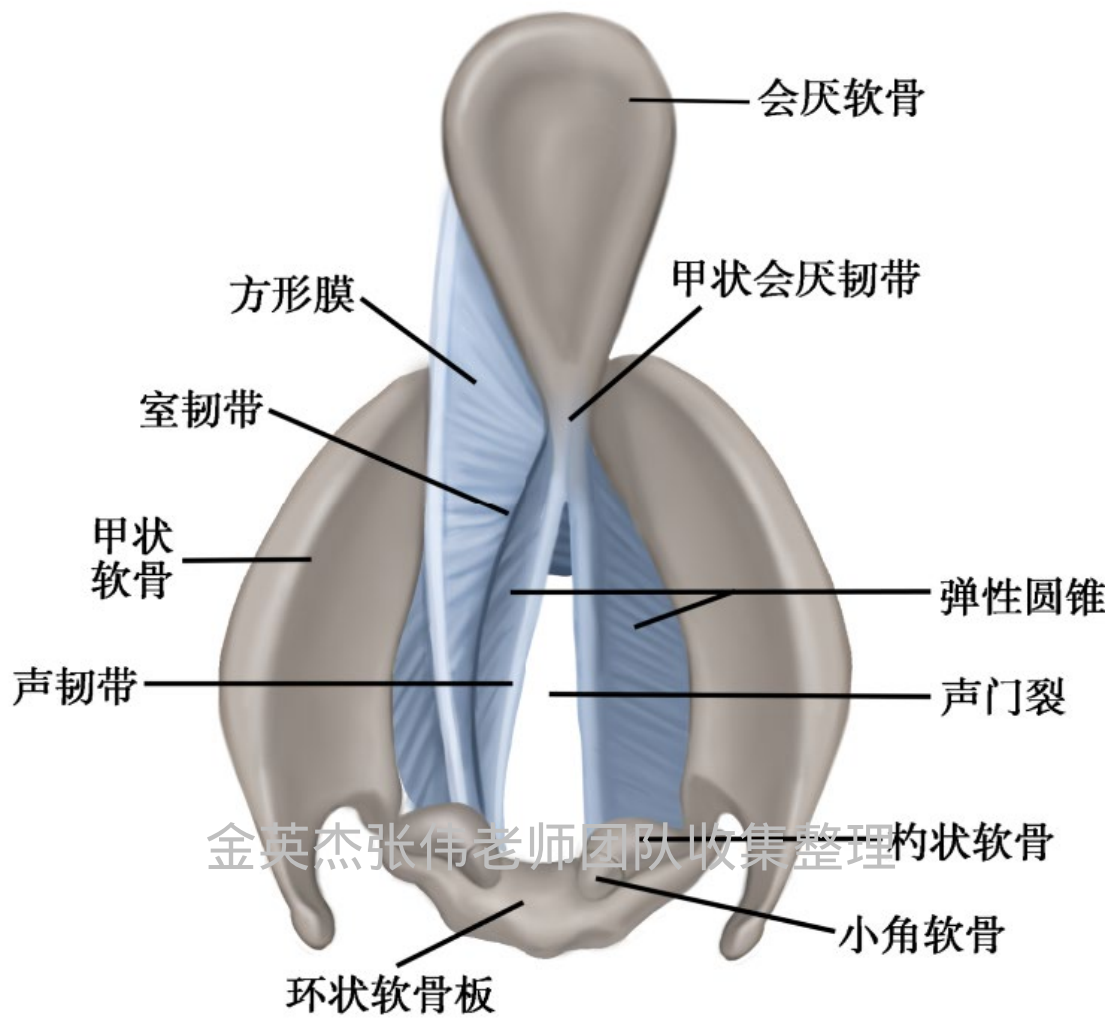


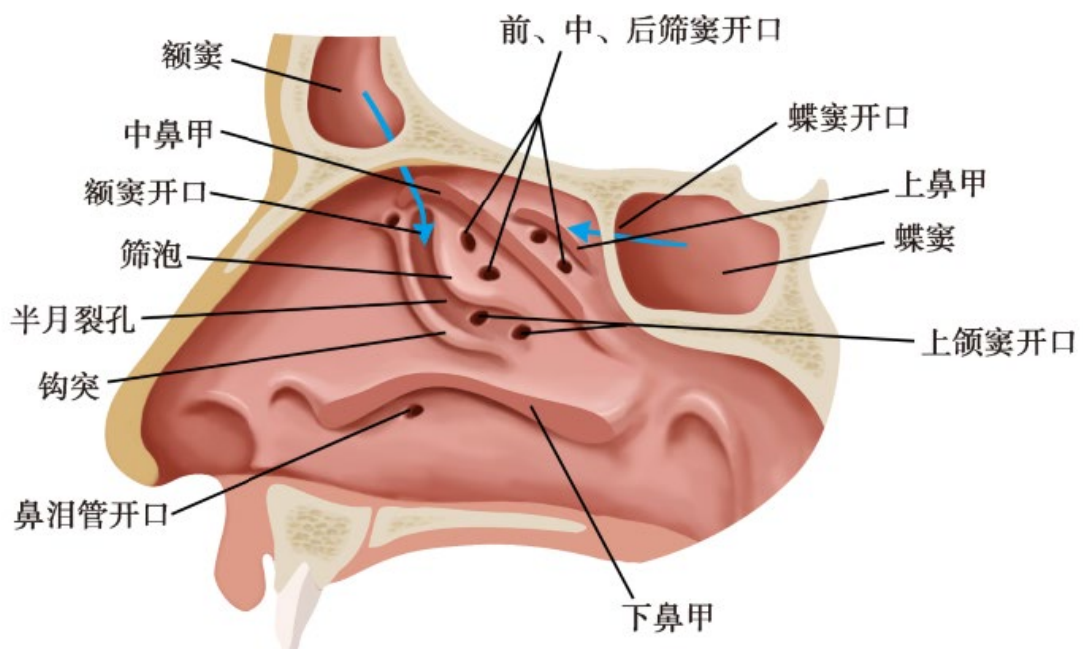
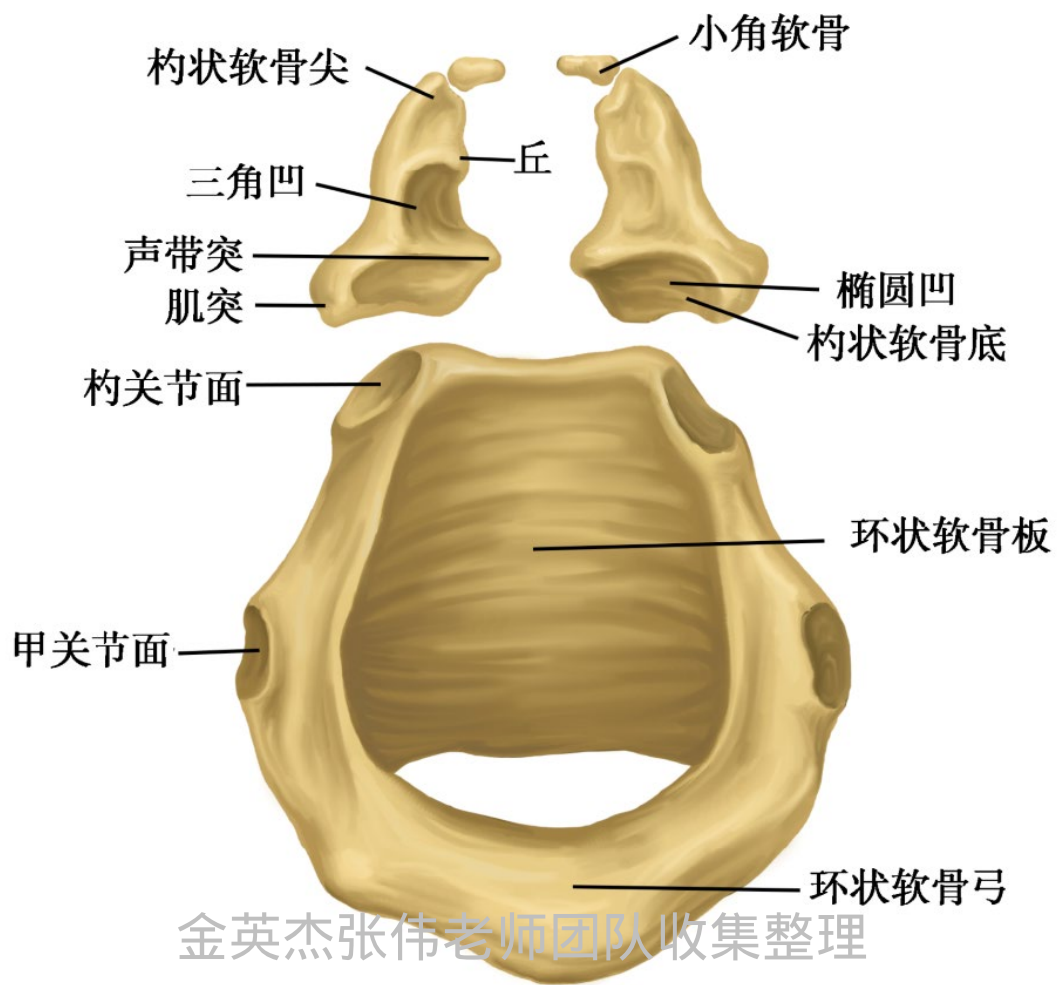


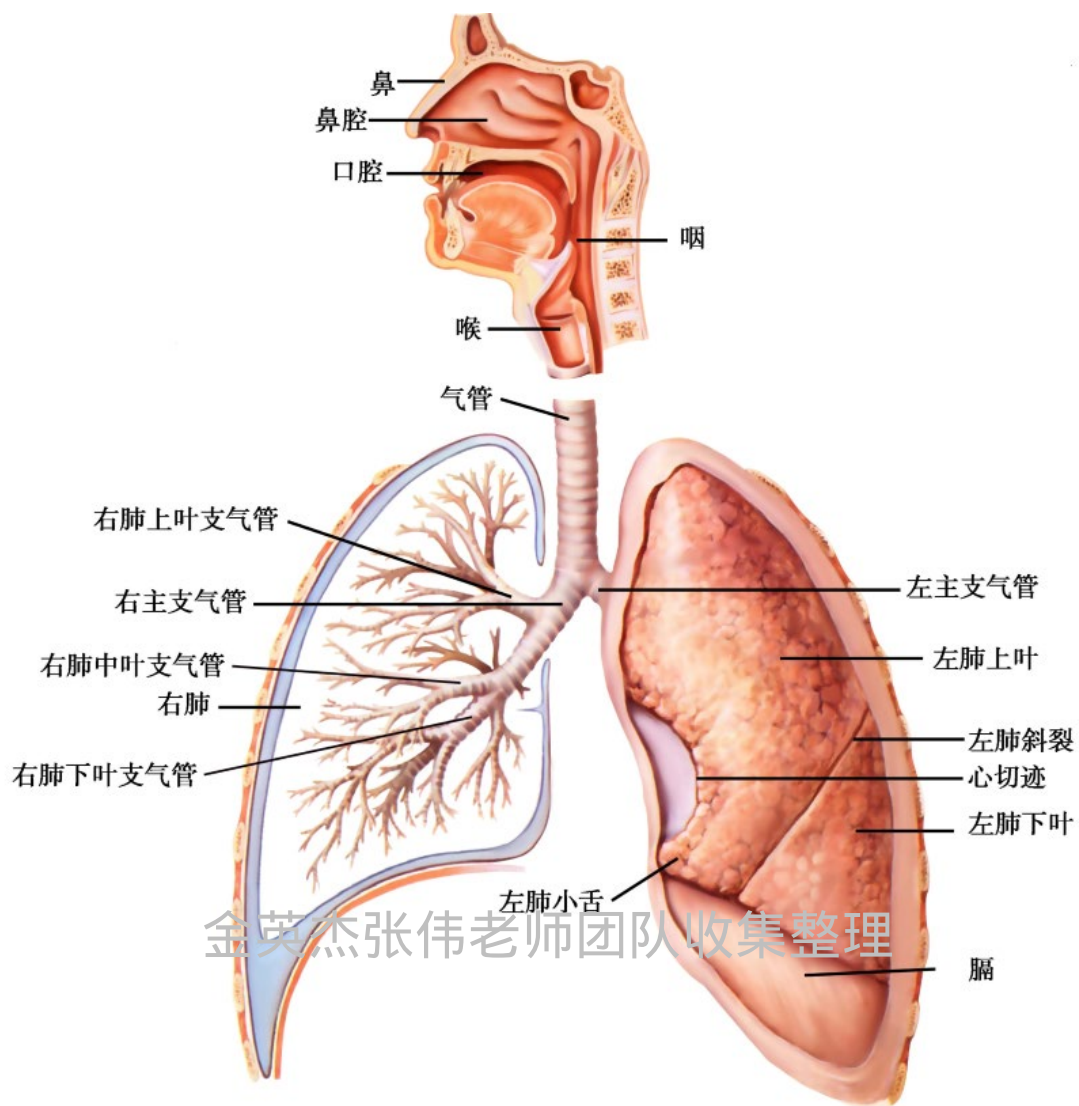
金英杰老师团队收集整理



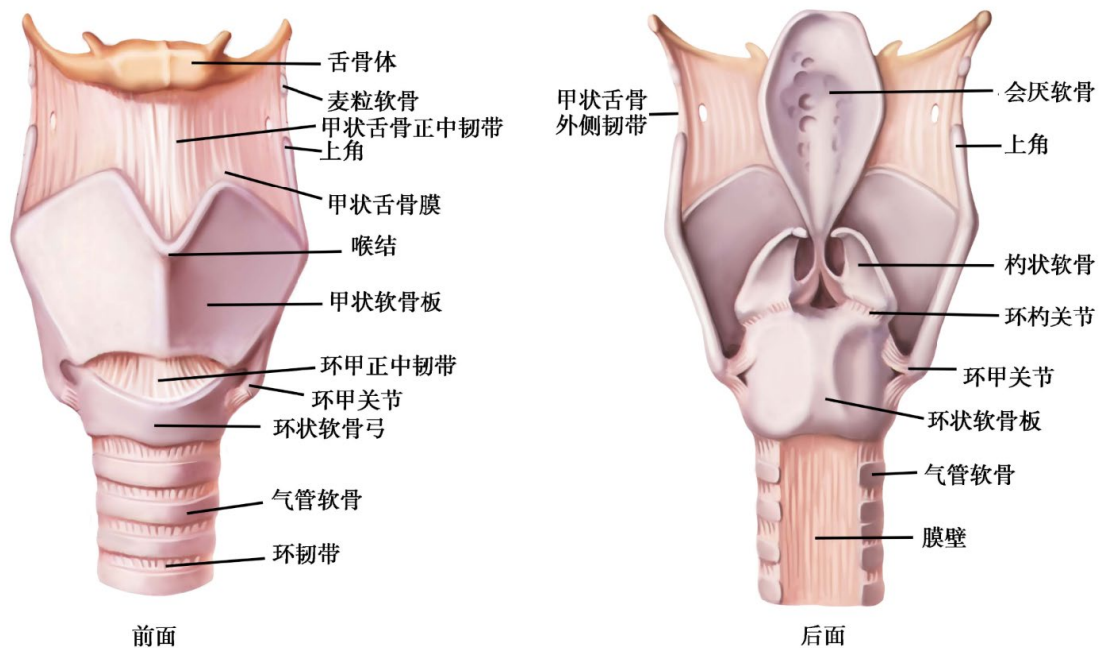


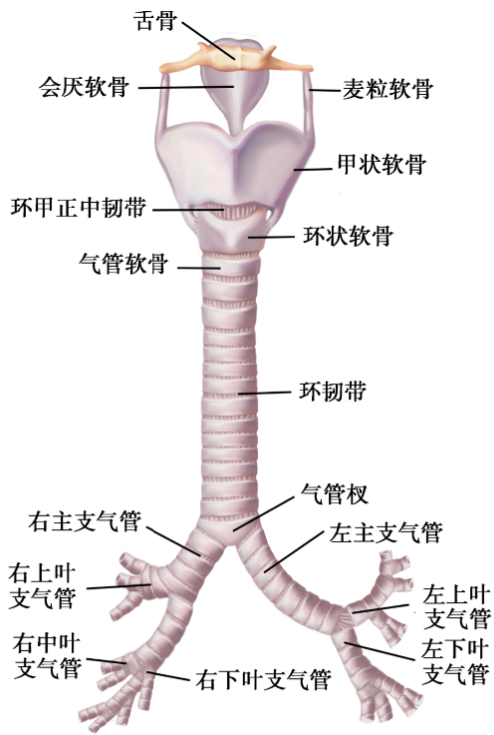




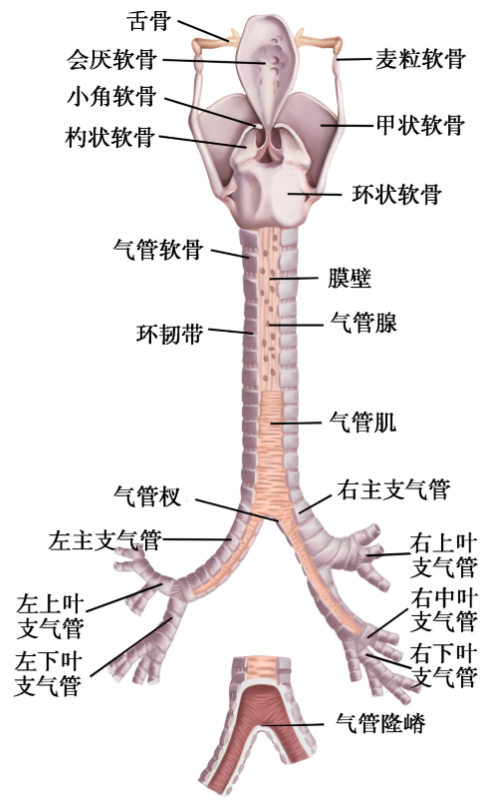


金英杰张伟老师团队收集整理



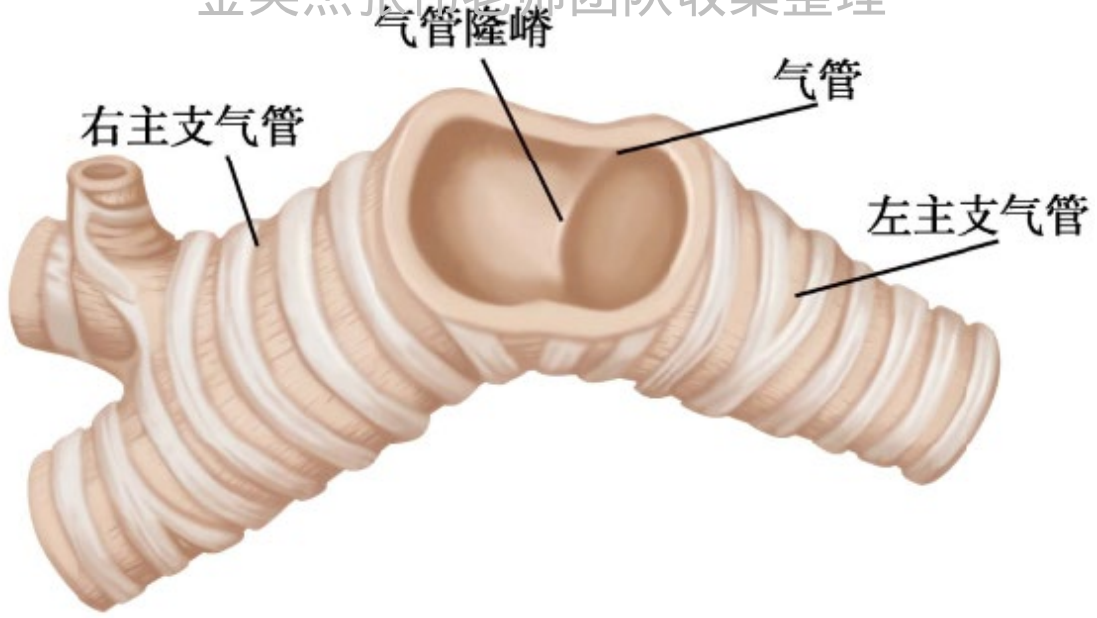


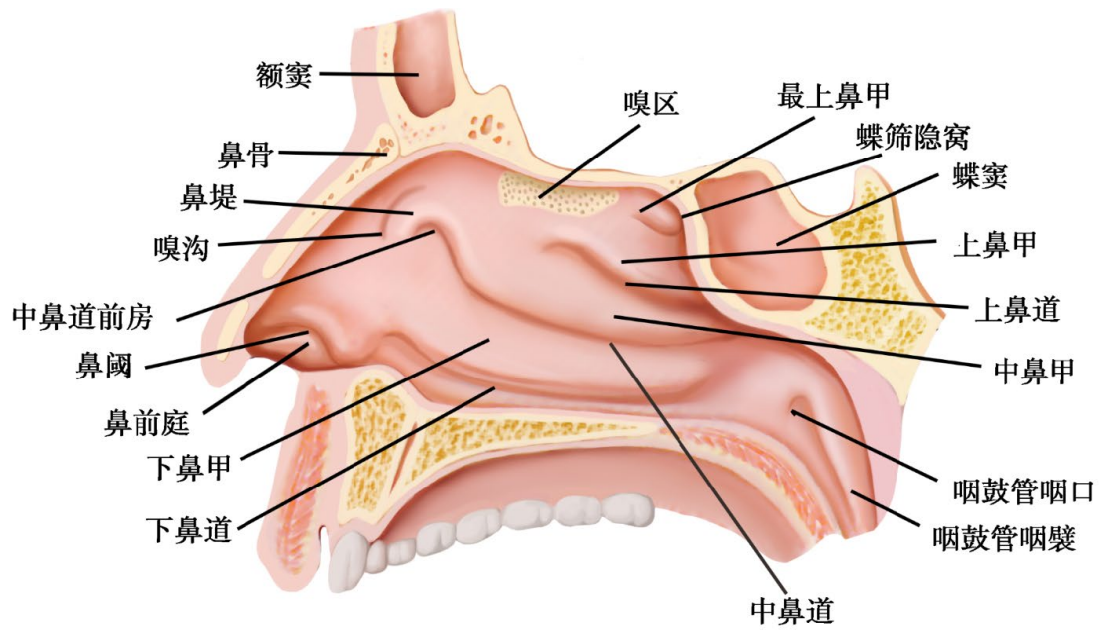
前面



后面

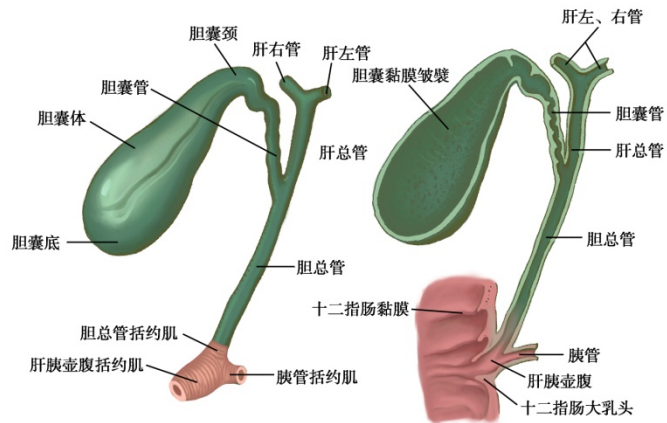
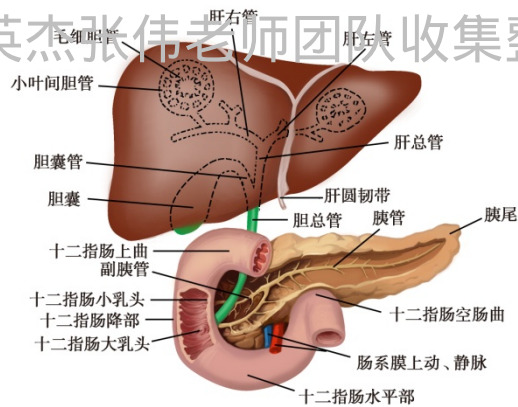
金英杰张伟老师团队收集整理

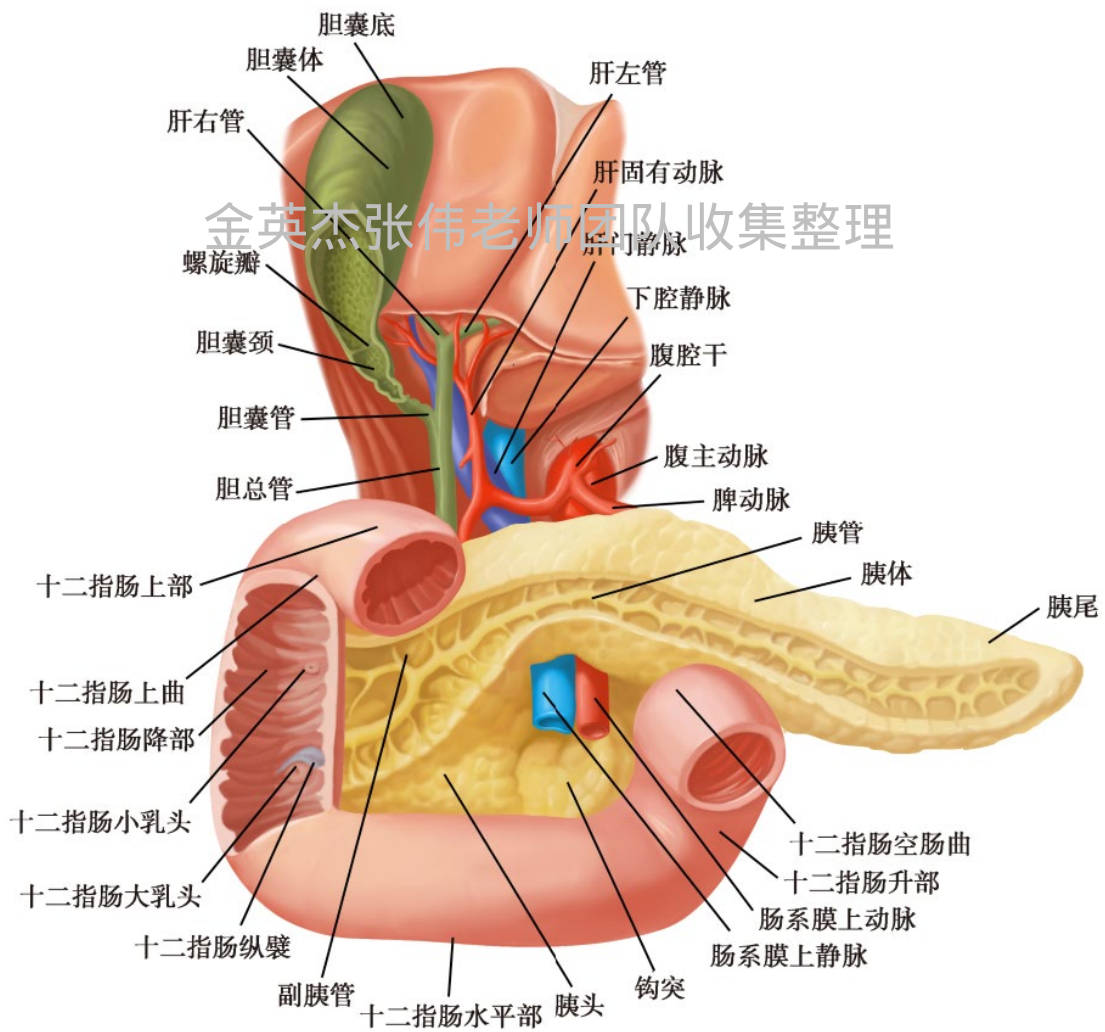
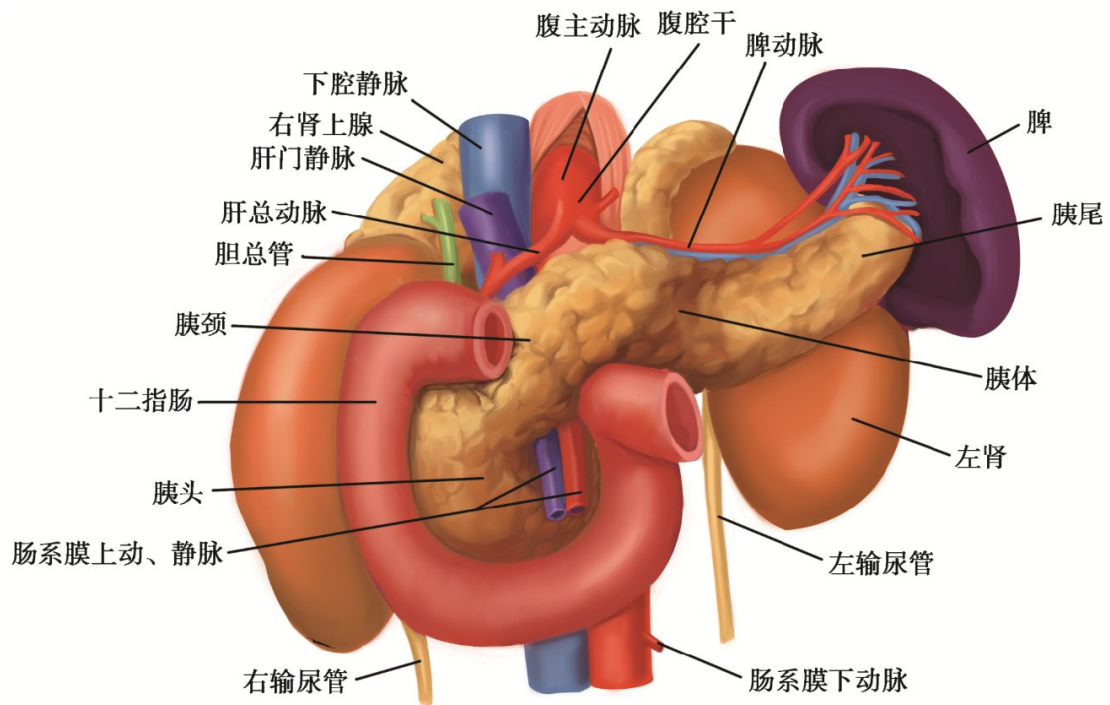




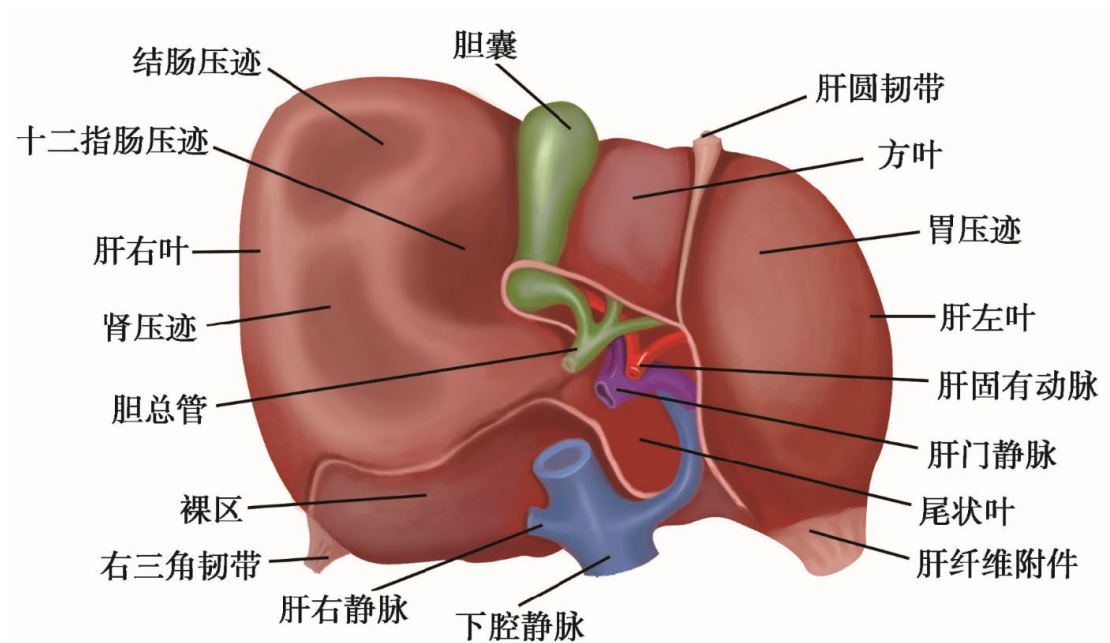
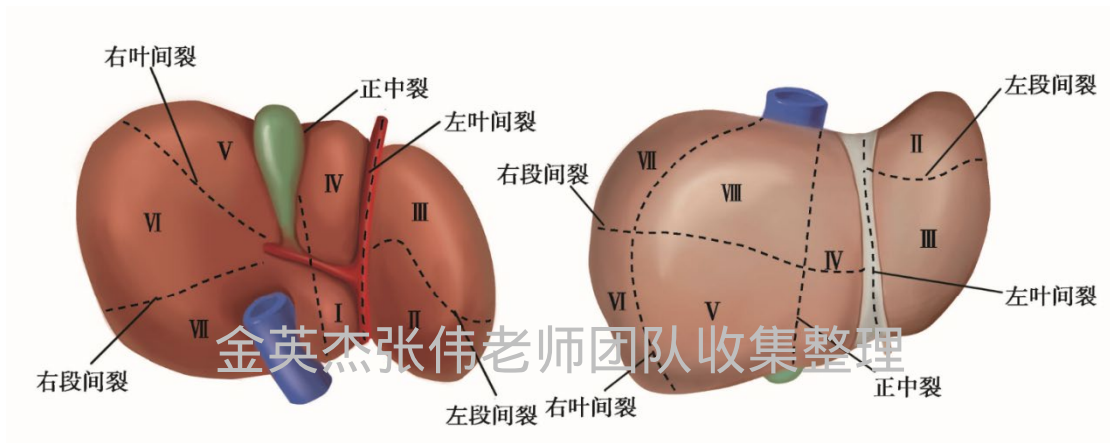
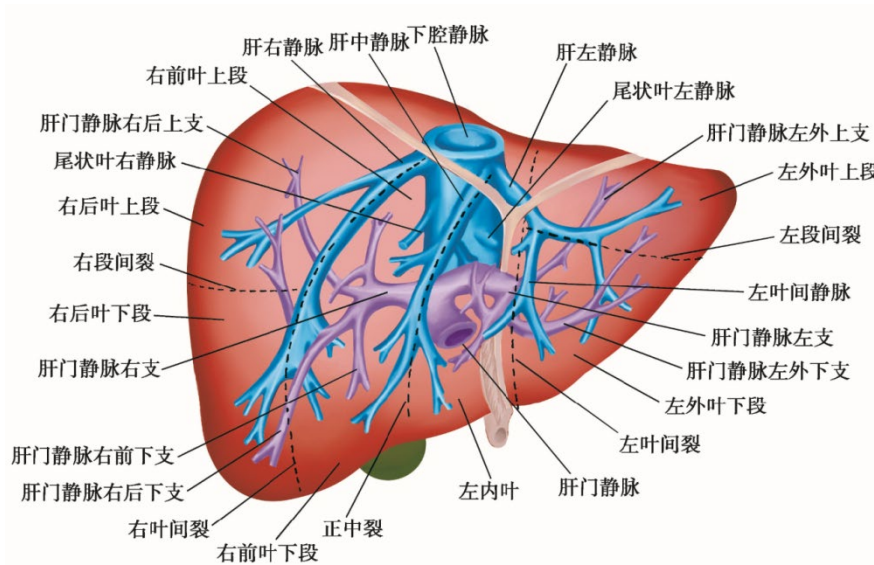
消化

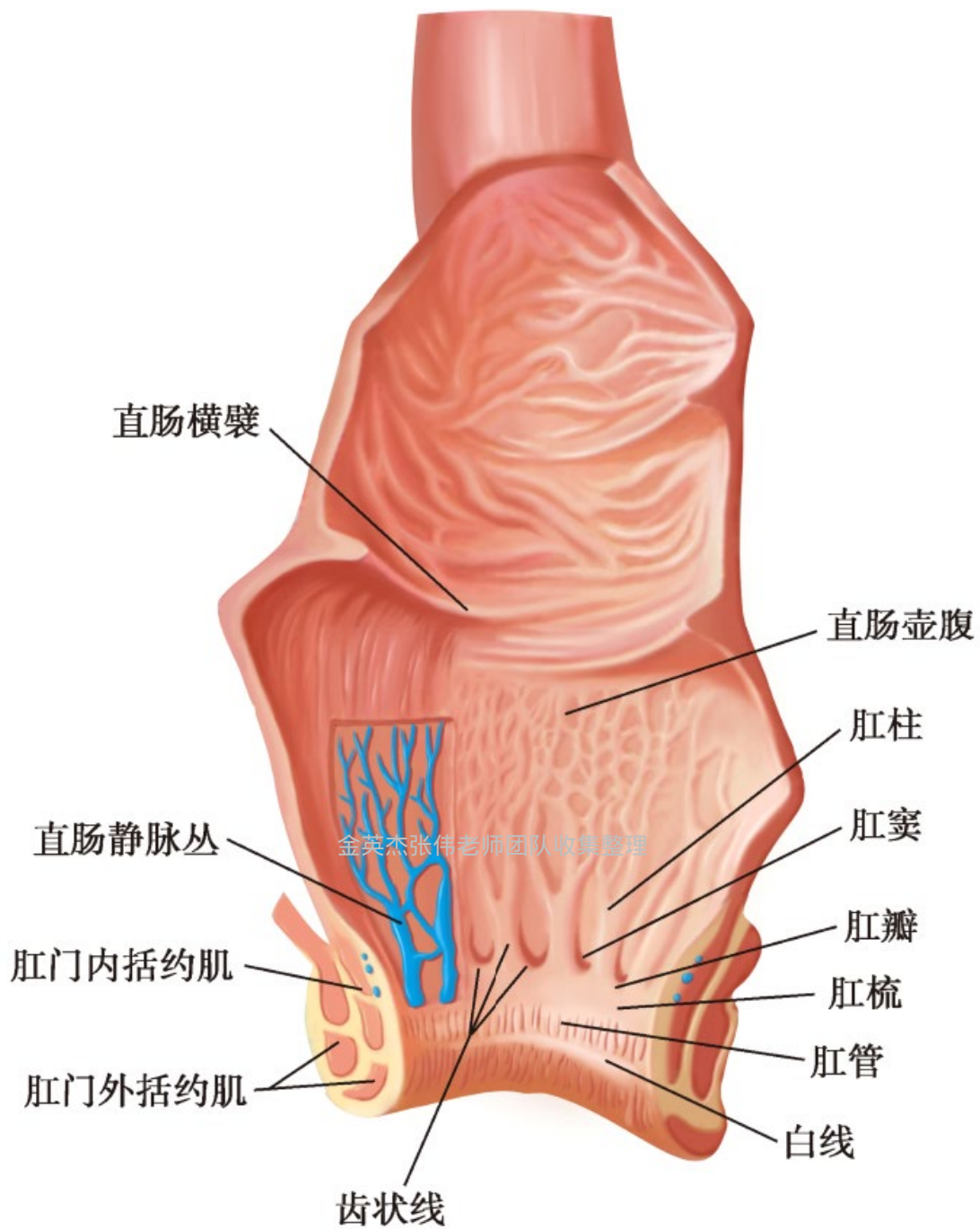
金英杰张伟老师团队收集整理





金英杰张伟老师团队收集整理

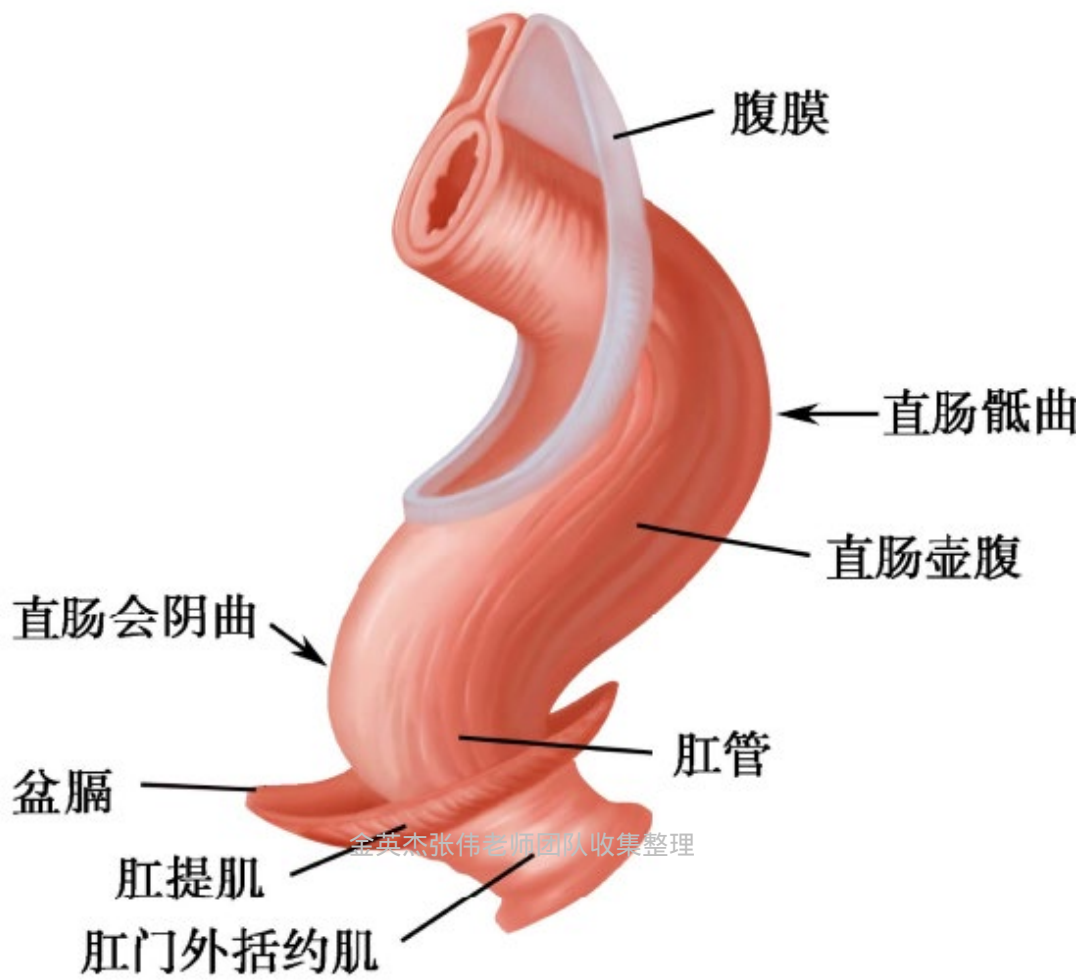




金英杰张伟老师

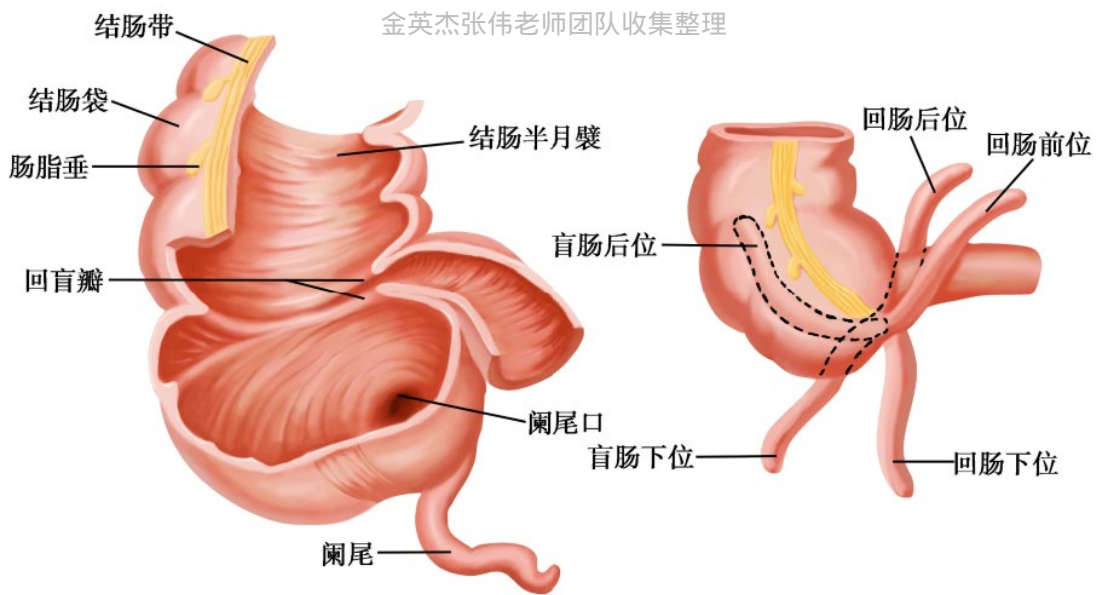
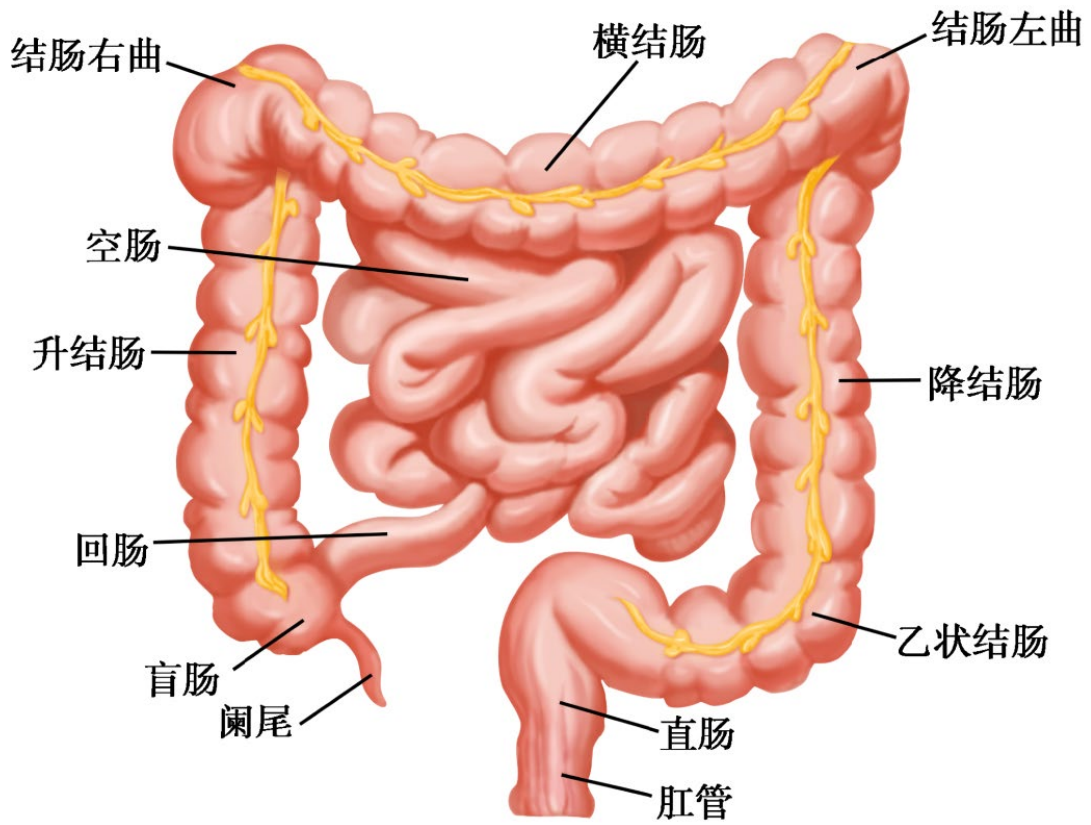
获取更多医考资料请关注





获取更多医考资料请关注





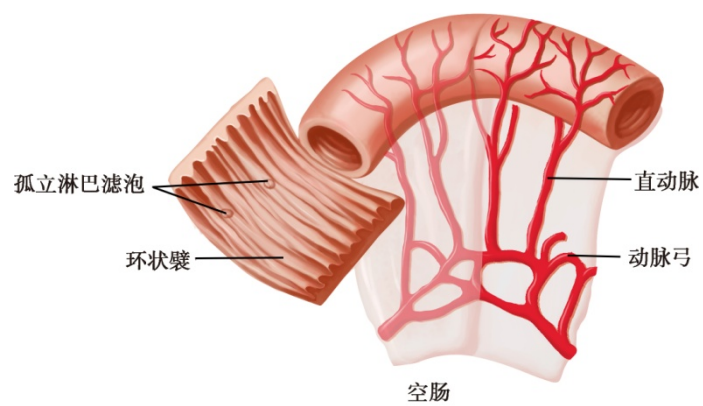
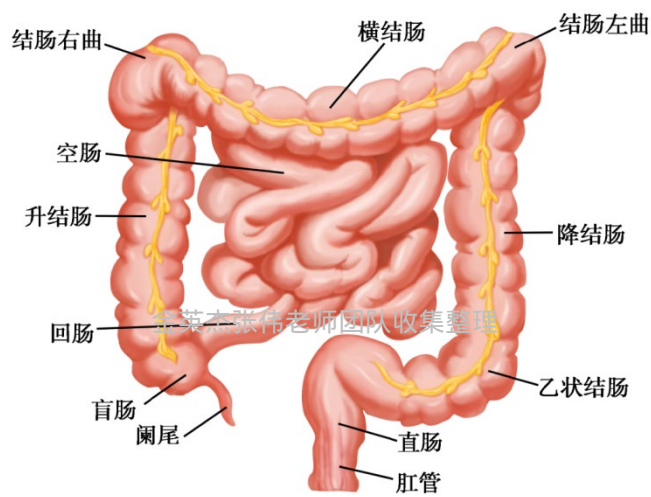
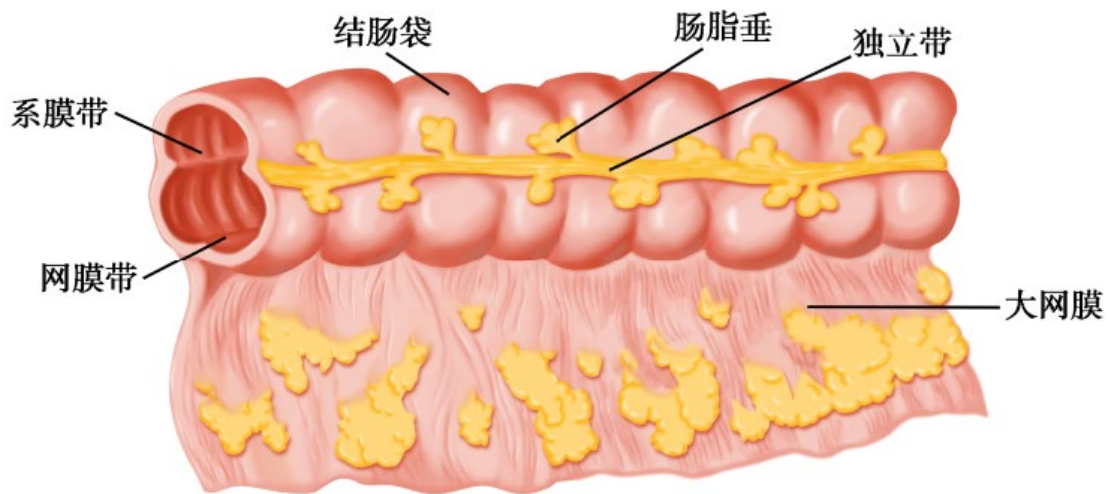
金英杰张伟老师团队收集整理



金英杰张伟老师

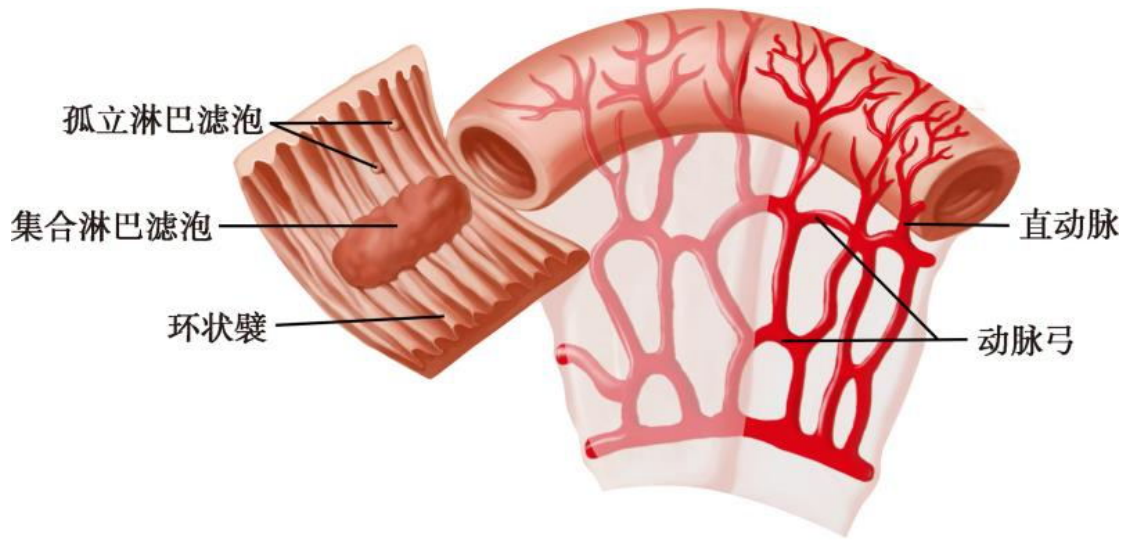
获取更多医考资料请关注



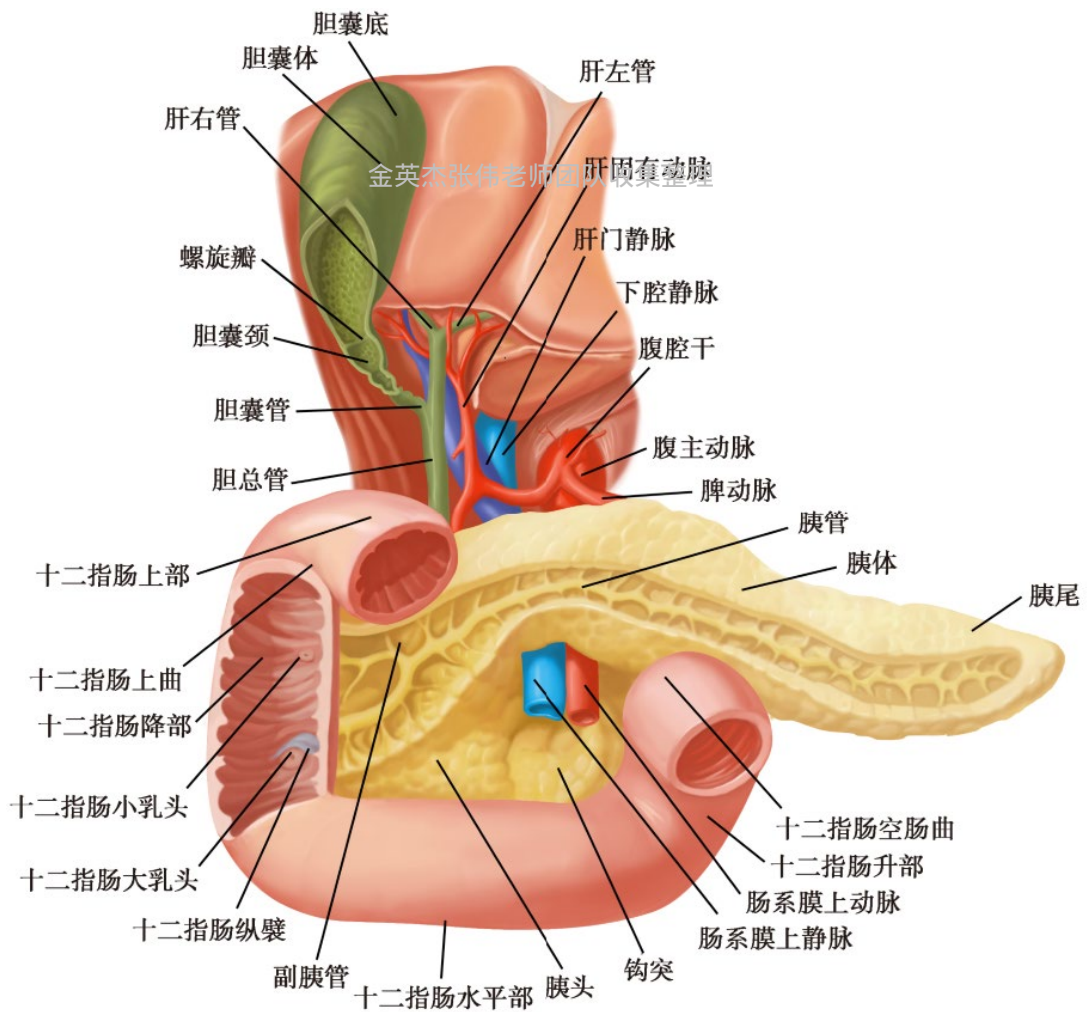


获取更多医考资料请关注





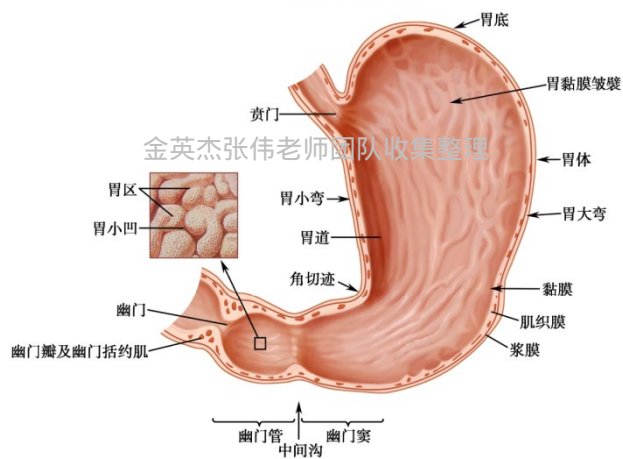
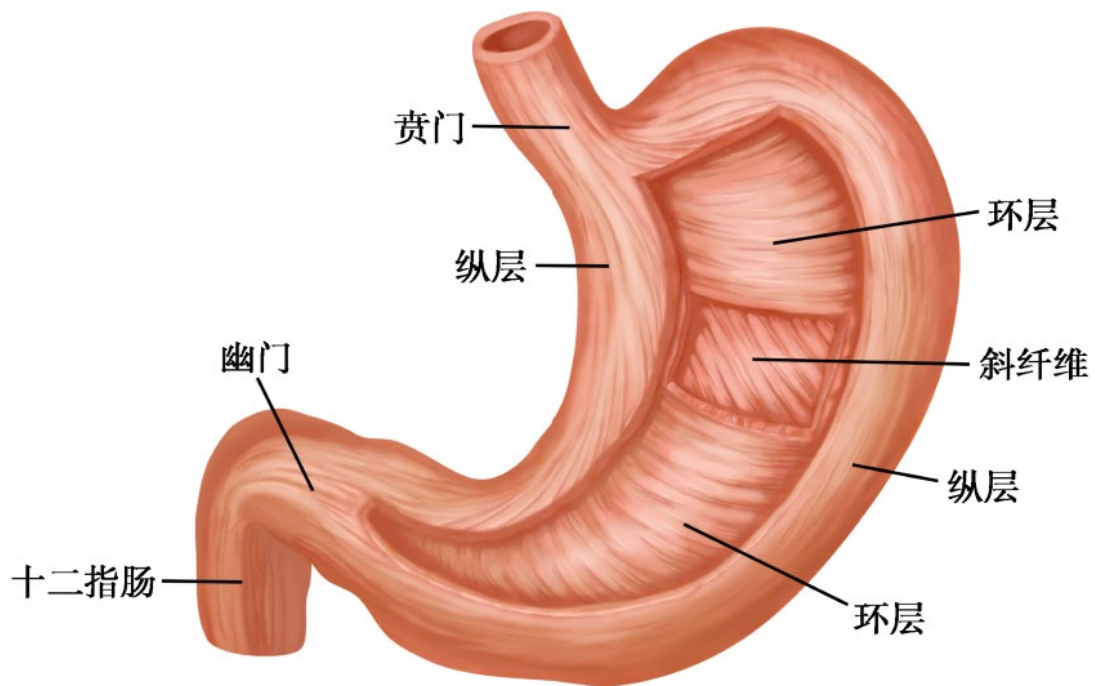
回肠



金英杰张伟老师

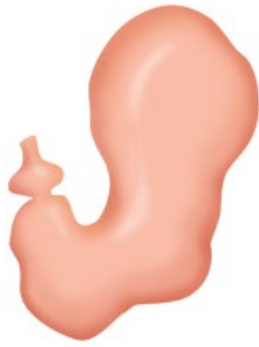获取更多医考资料请关注



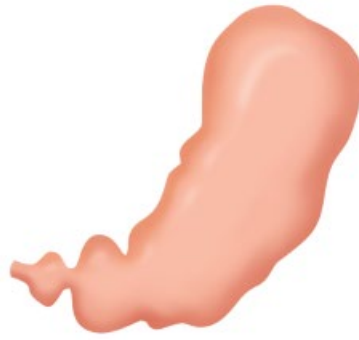

获取更多医考资料请关注

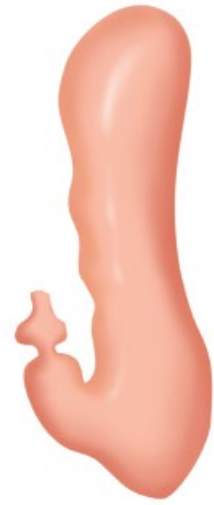



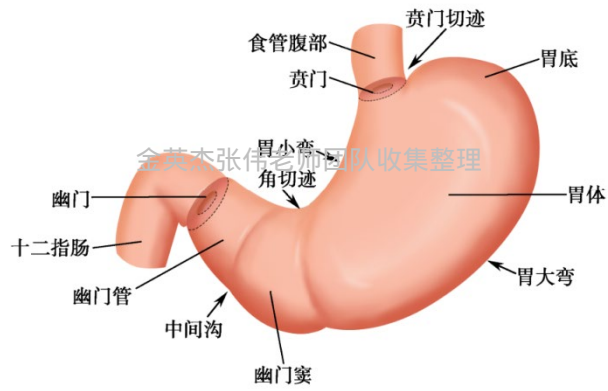
钩型胃



角型胃



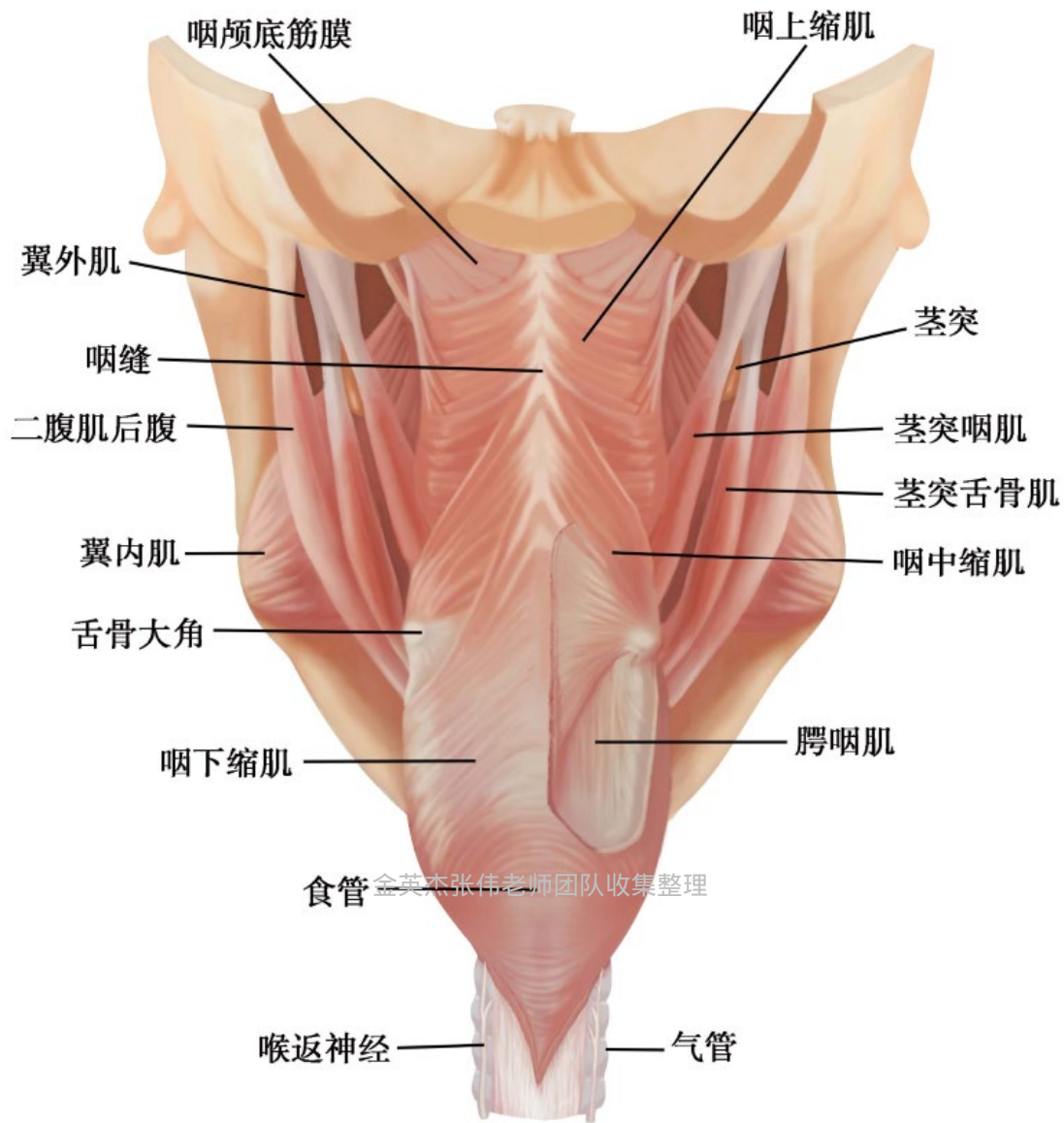
长胃



金英杰张伟老师

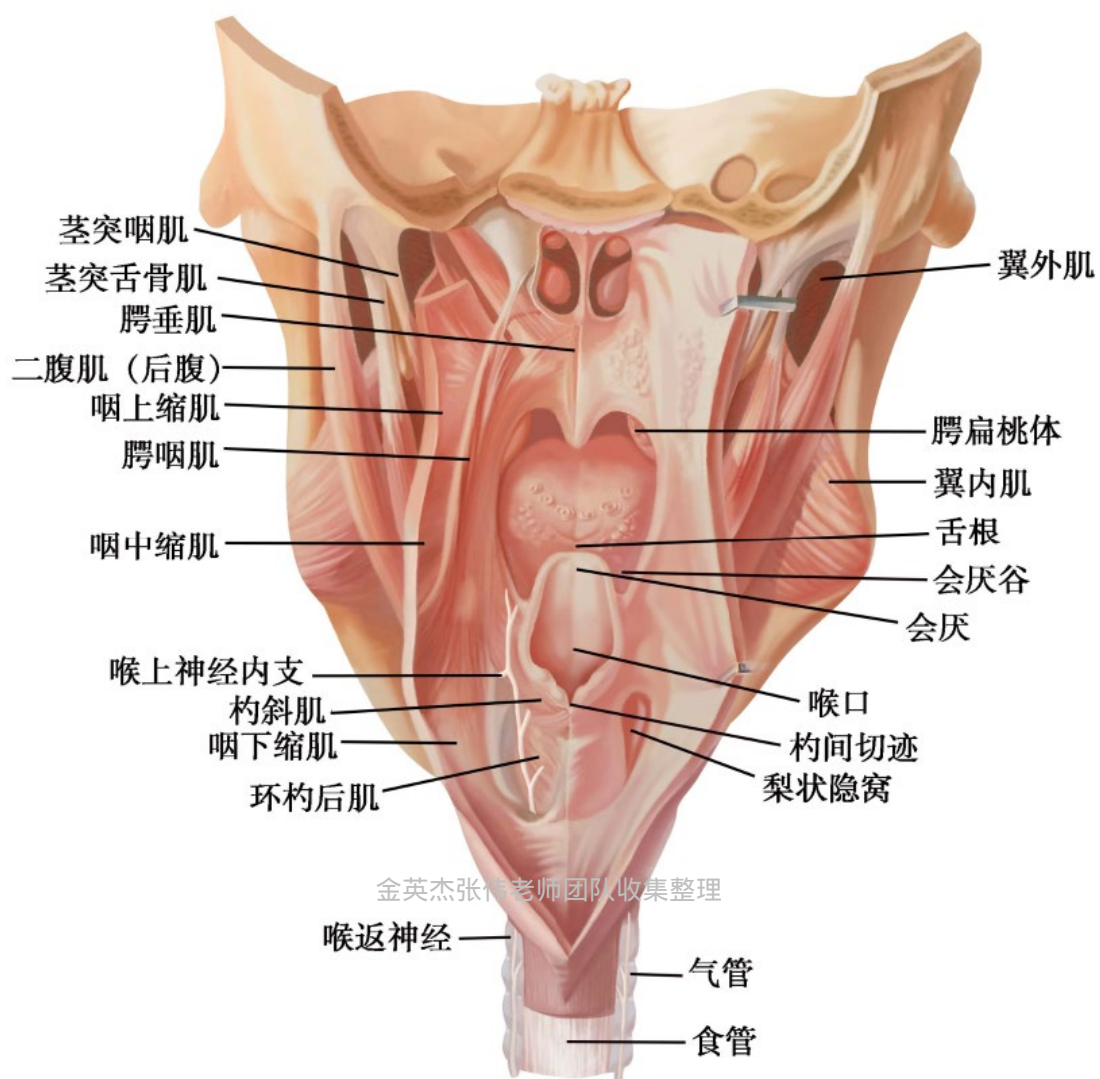
获取更多医考资料请关注





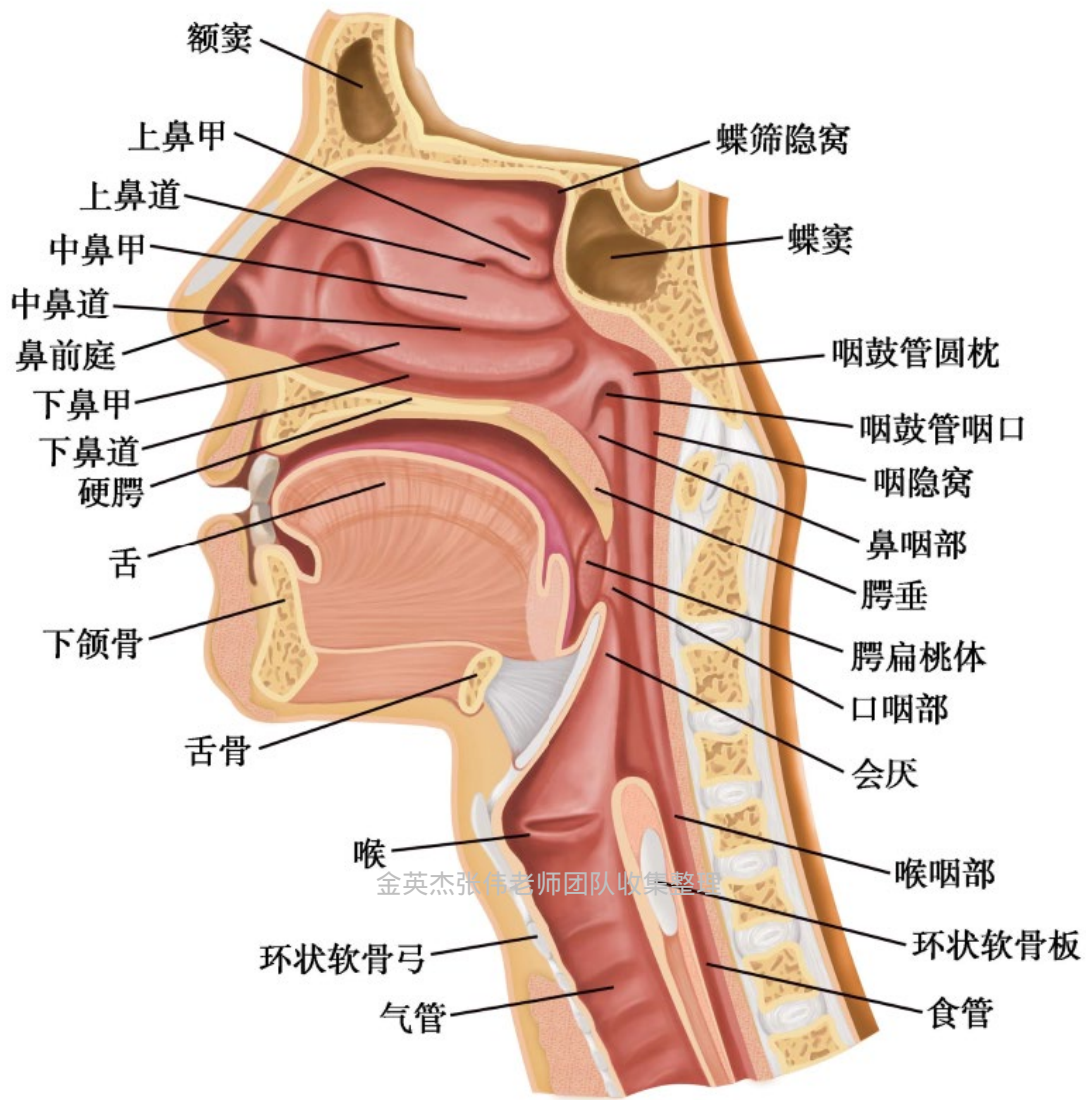
获取更多医考资料请关注



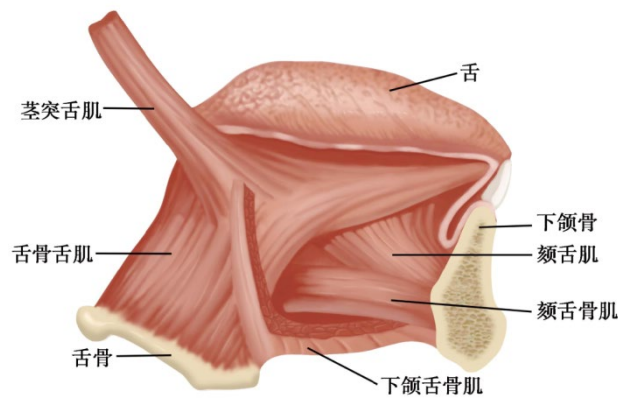


获取更多医考资料请关注



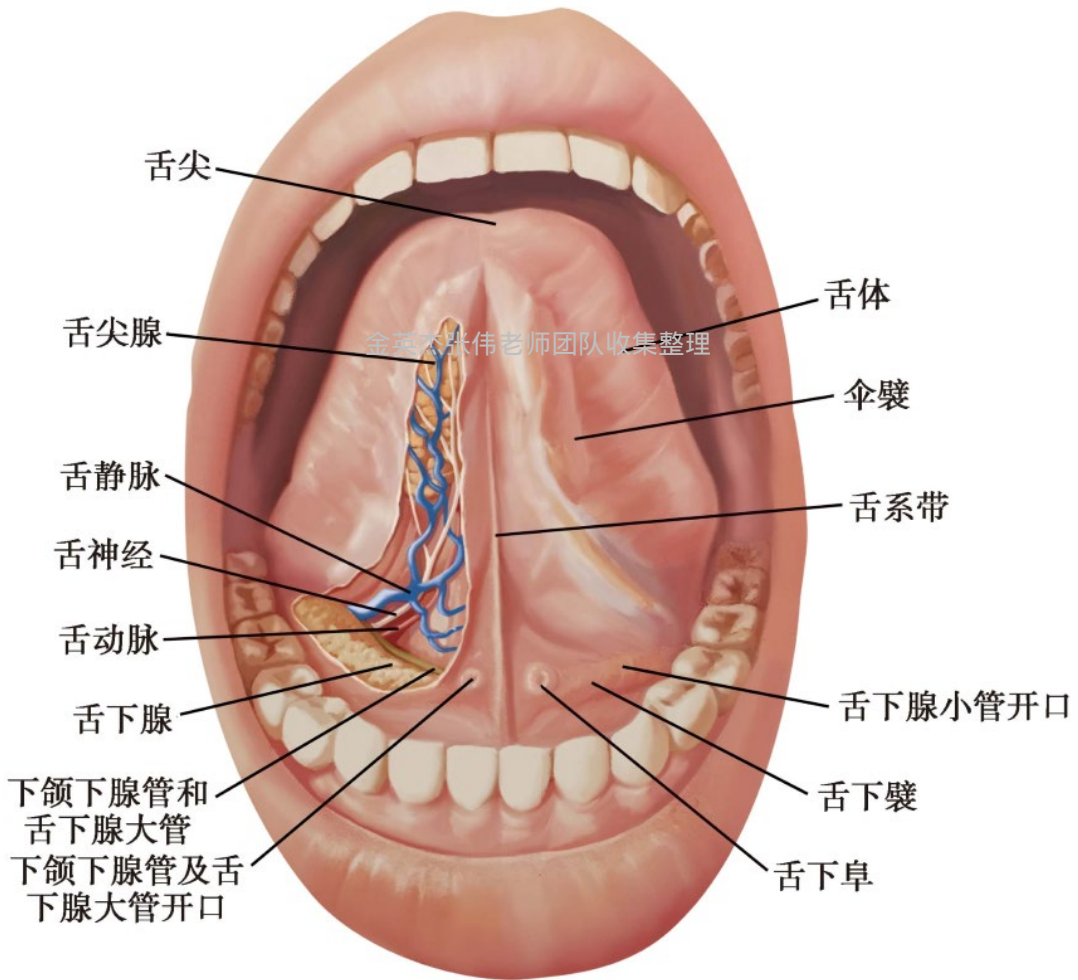
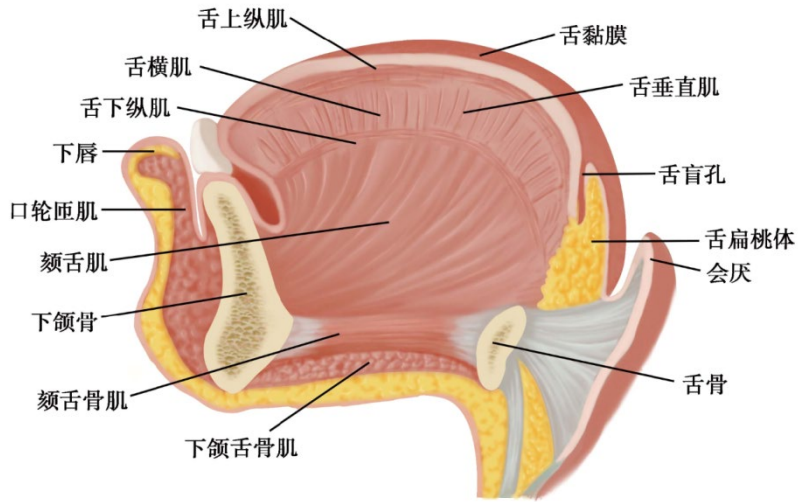


金英杰张伟老师

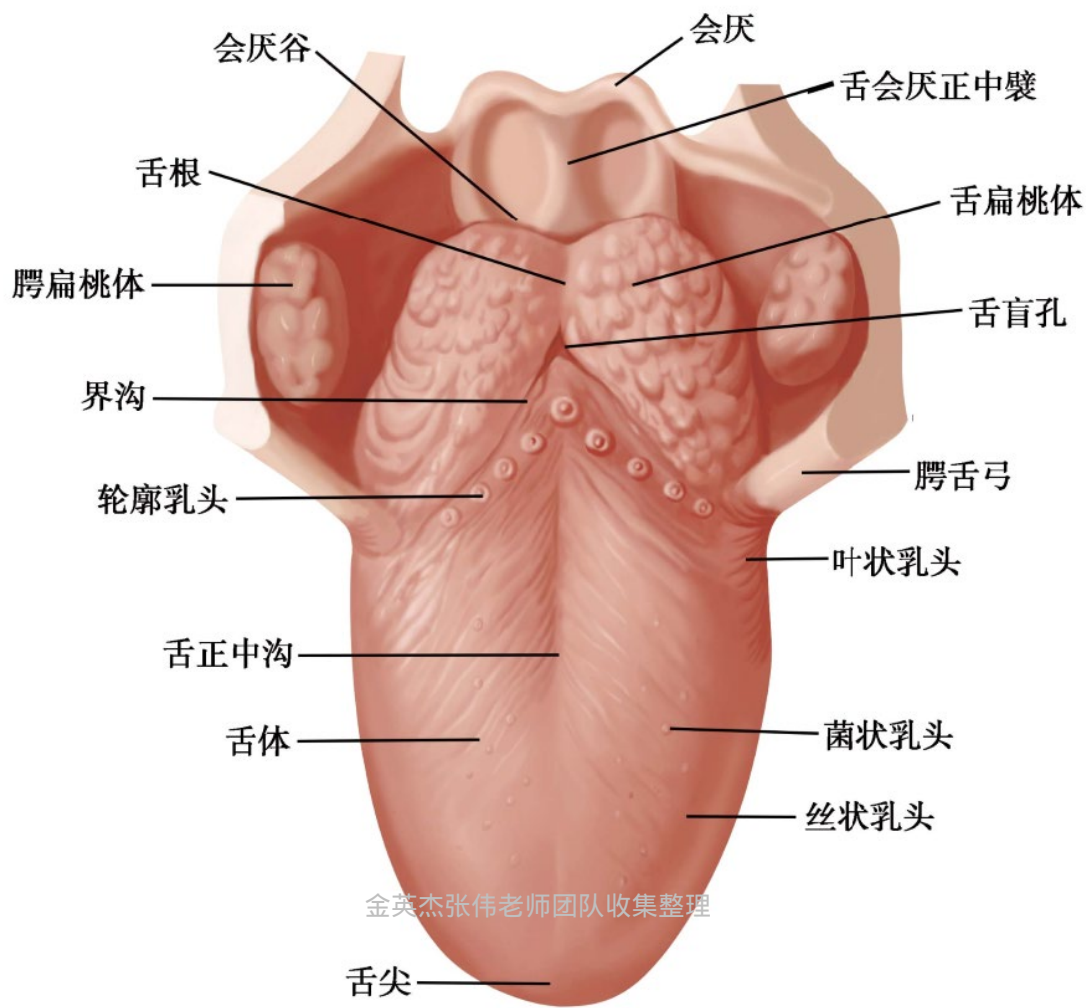


获取更多医考资料请关注



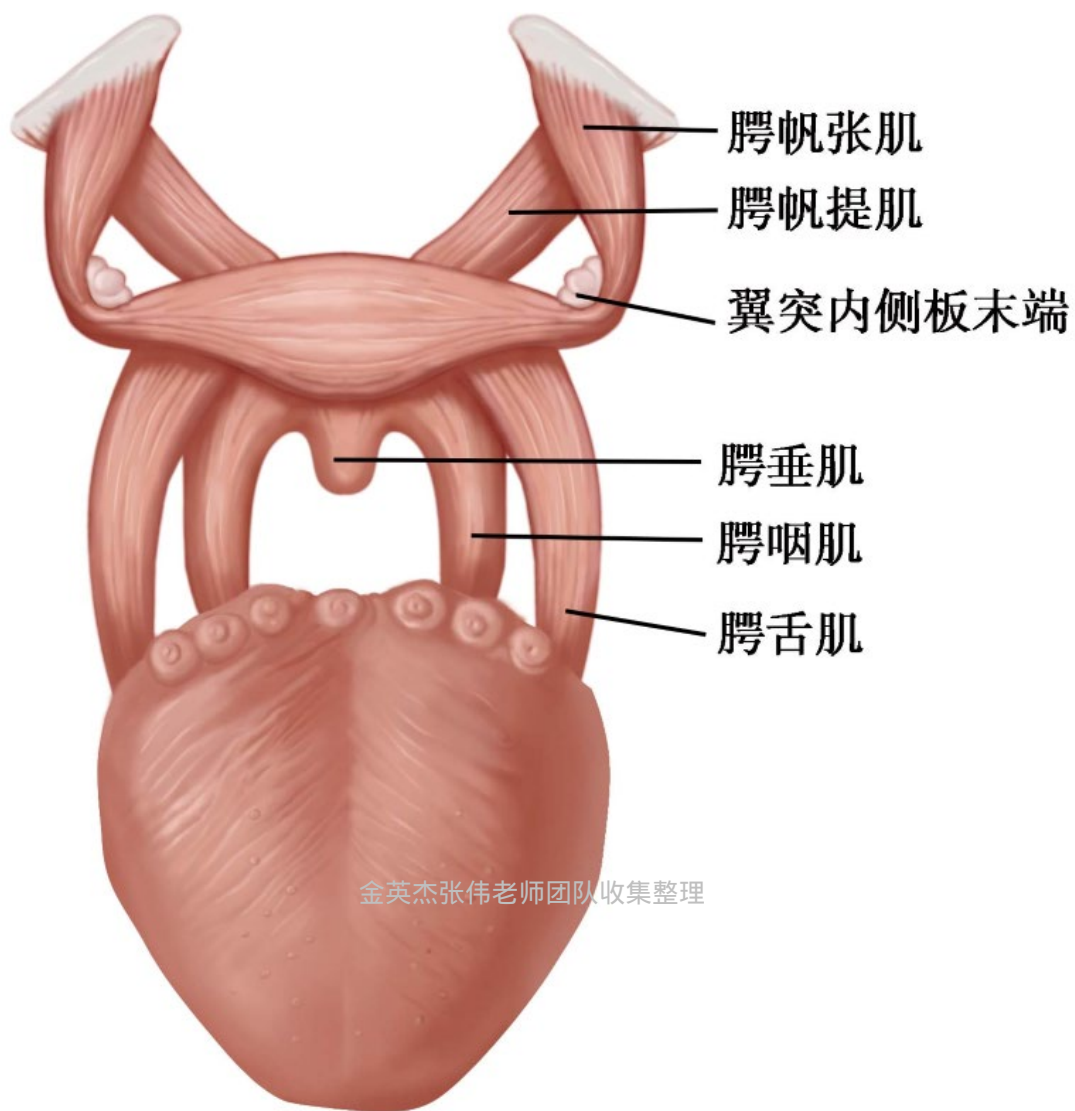


获取更多医考资料请关注



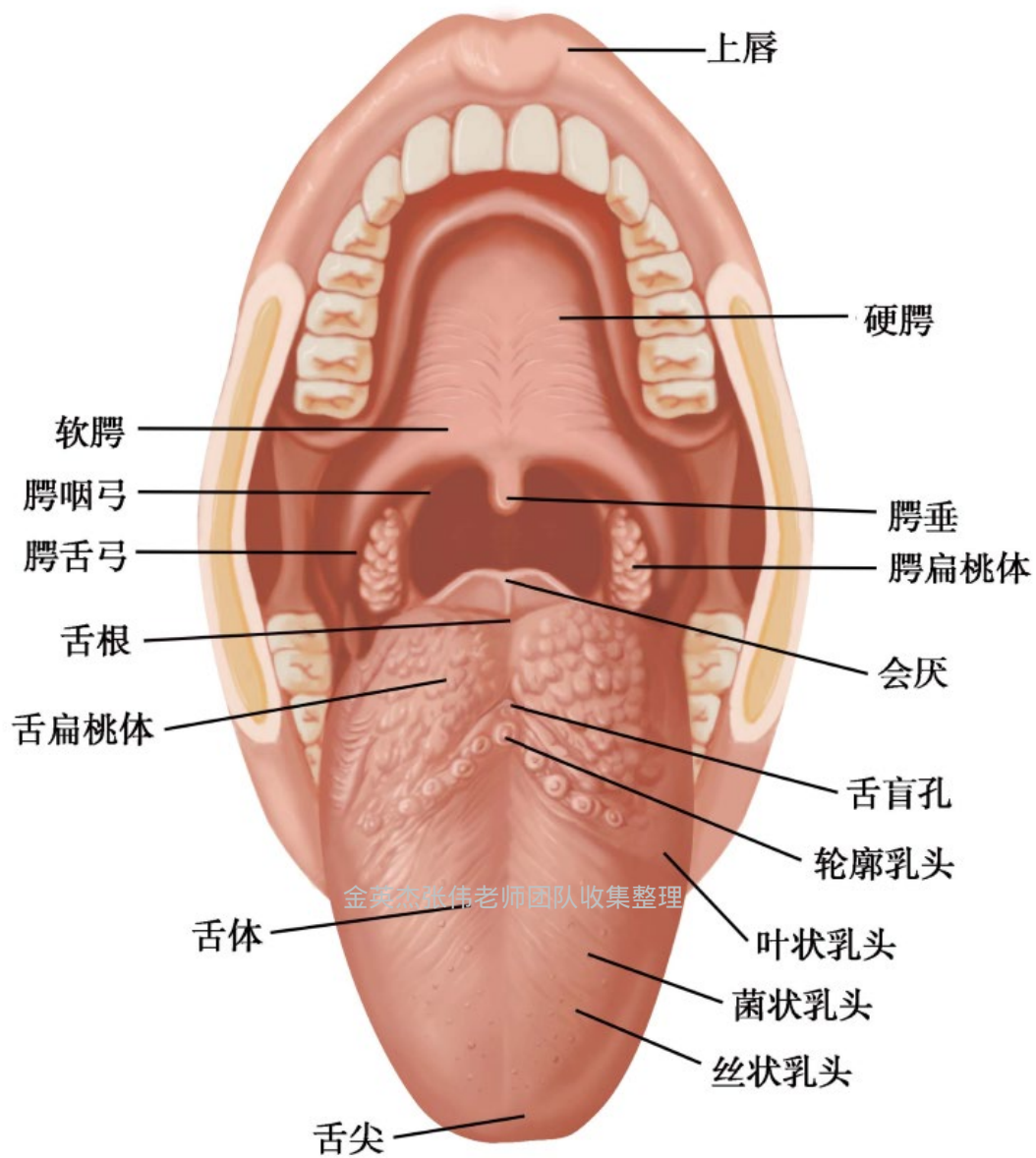
获取更多医考资料请关注





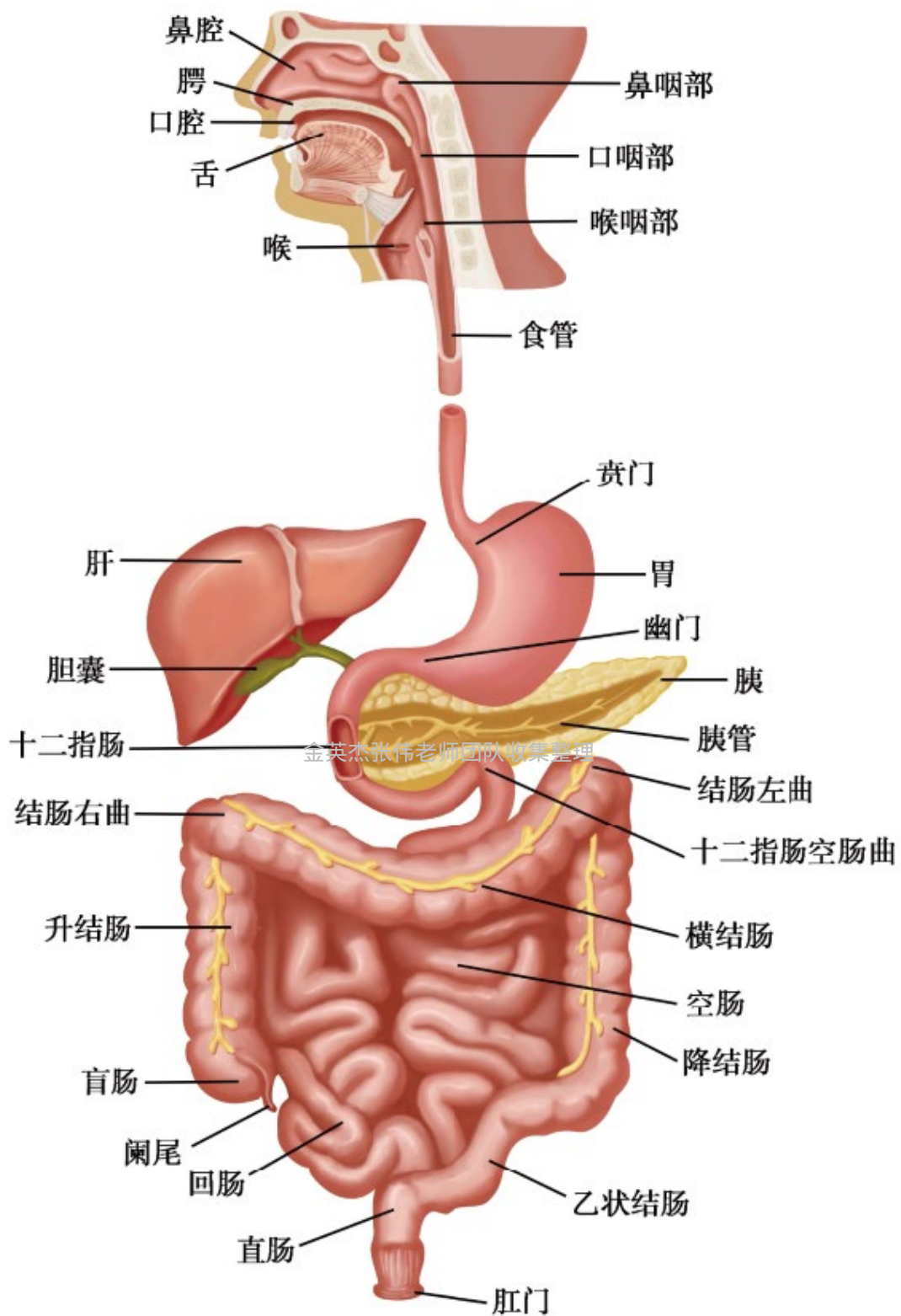
获取更多医考资料请关注





获取更多医考资料请关注

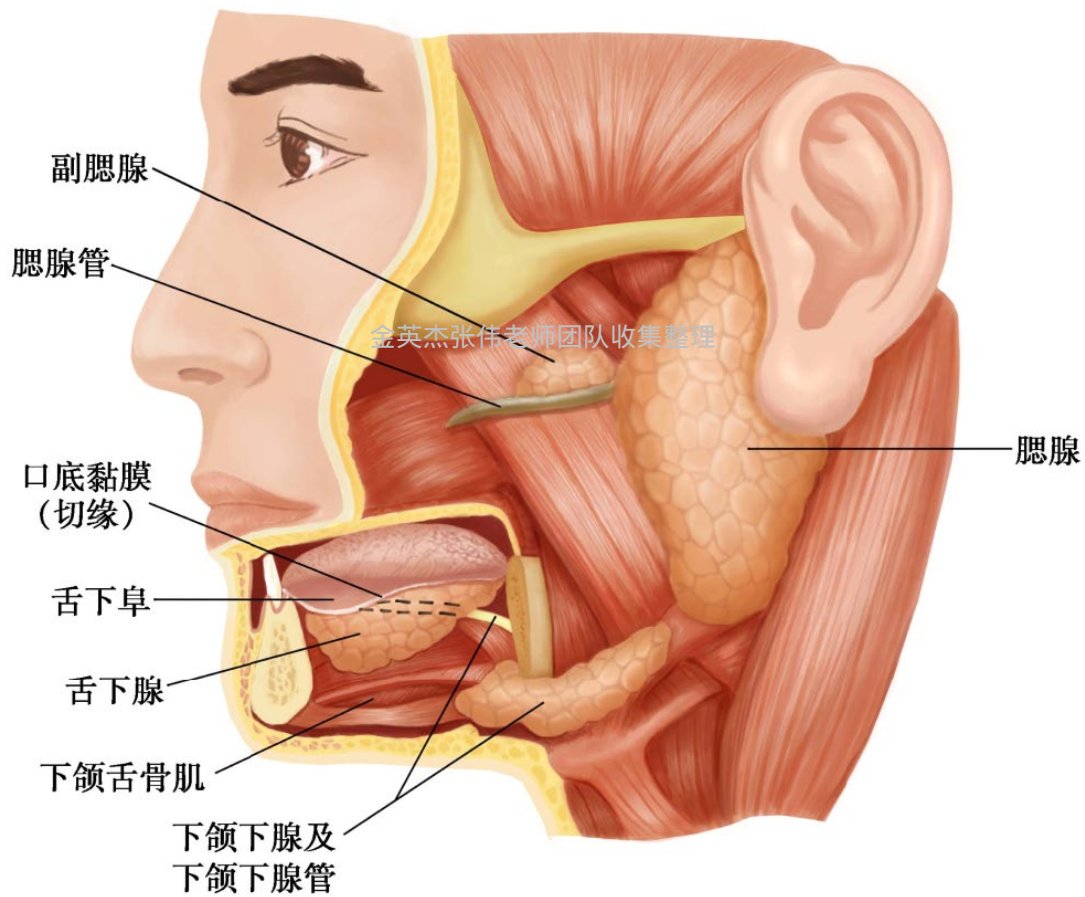
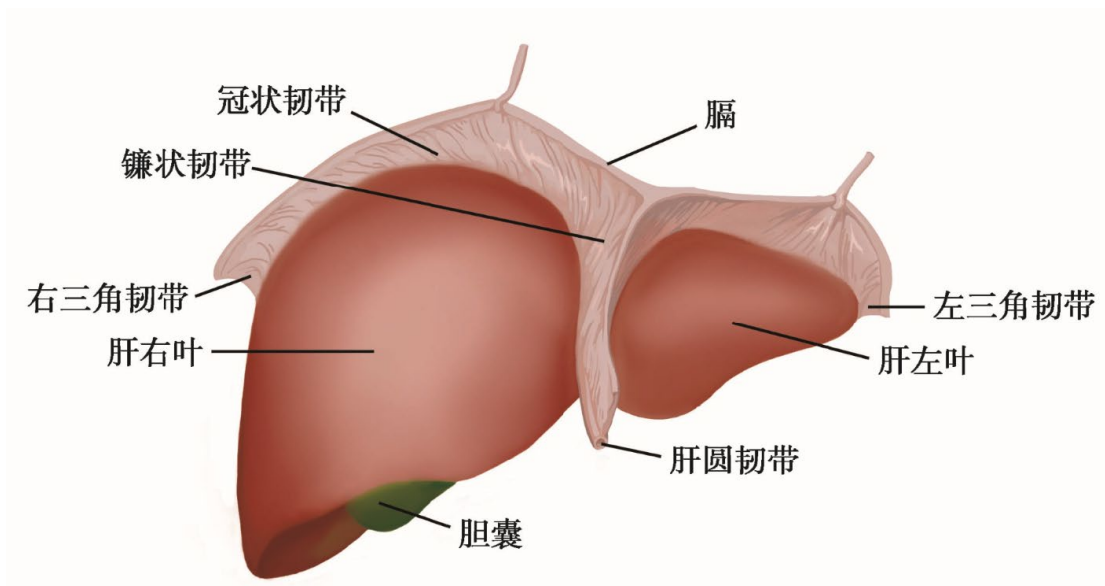




金英杰张伟老师

获取更多医考资料请关注

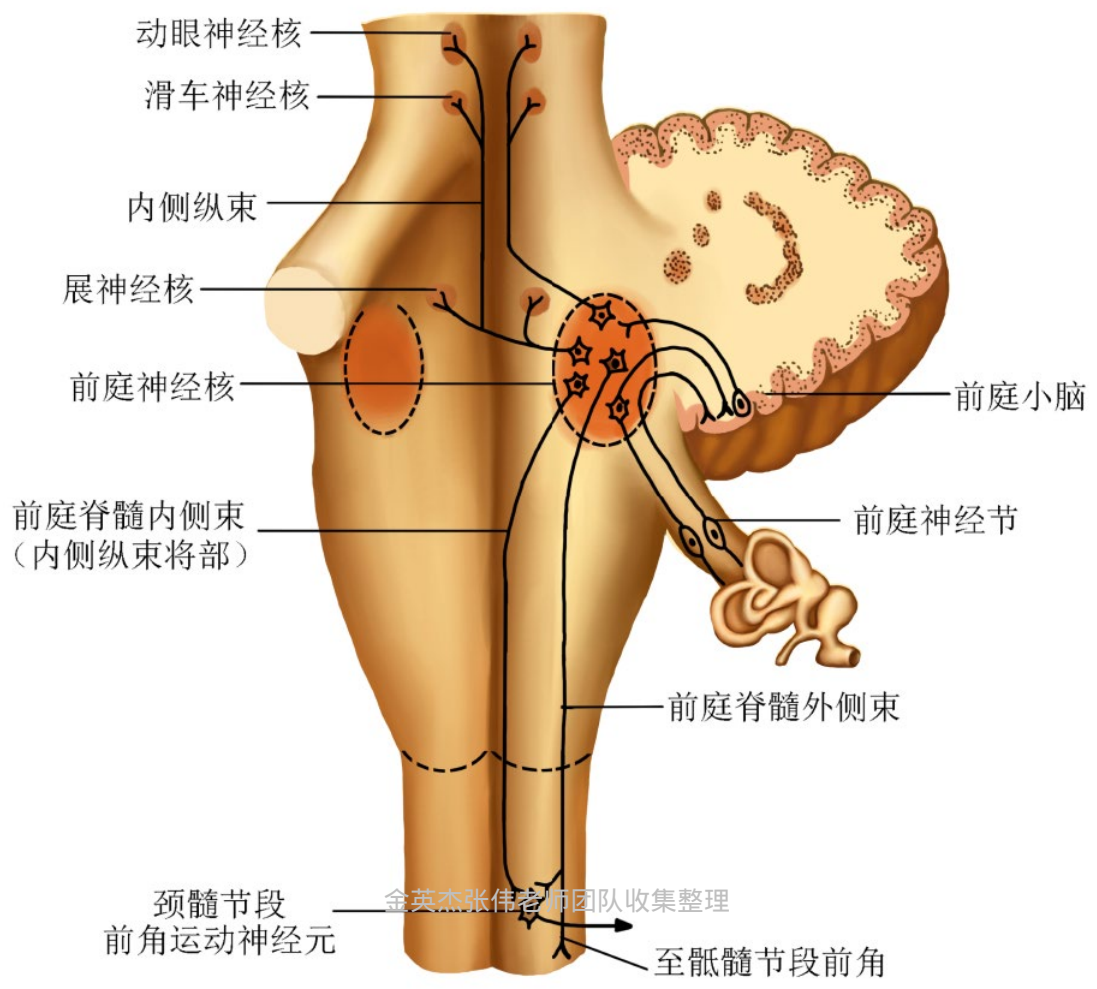




神经

获取更多医考资料请关注





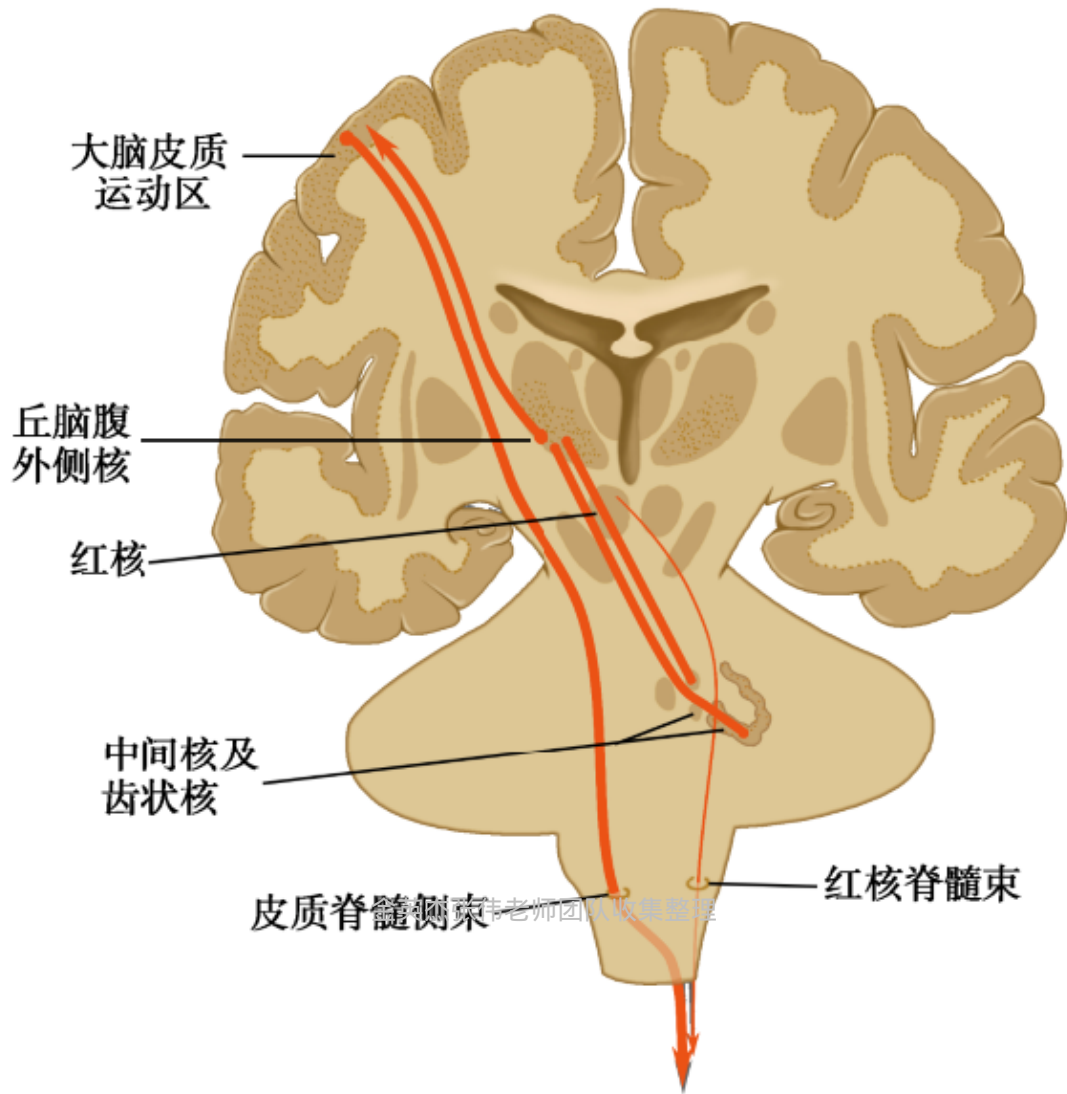
金英杰张伟老师团队收集整理



金英杰张伟老师

获取更多医考资料请关注

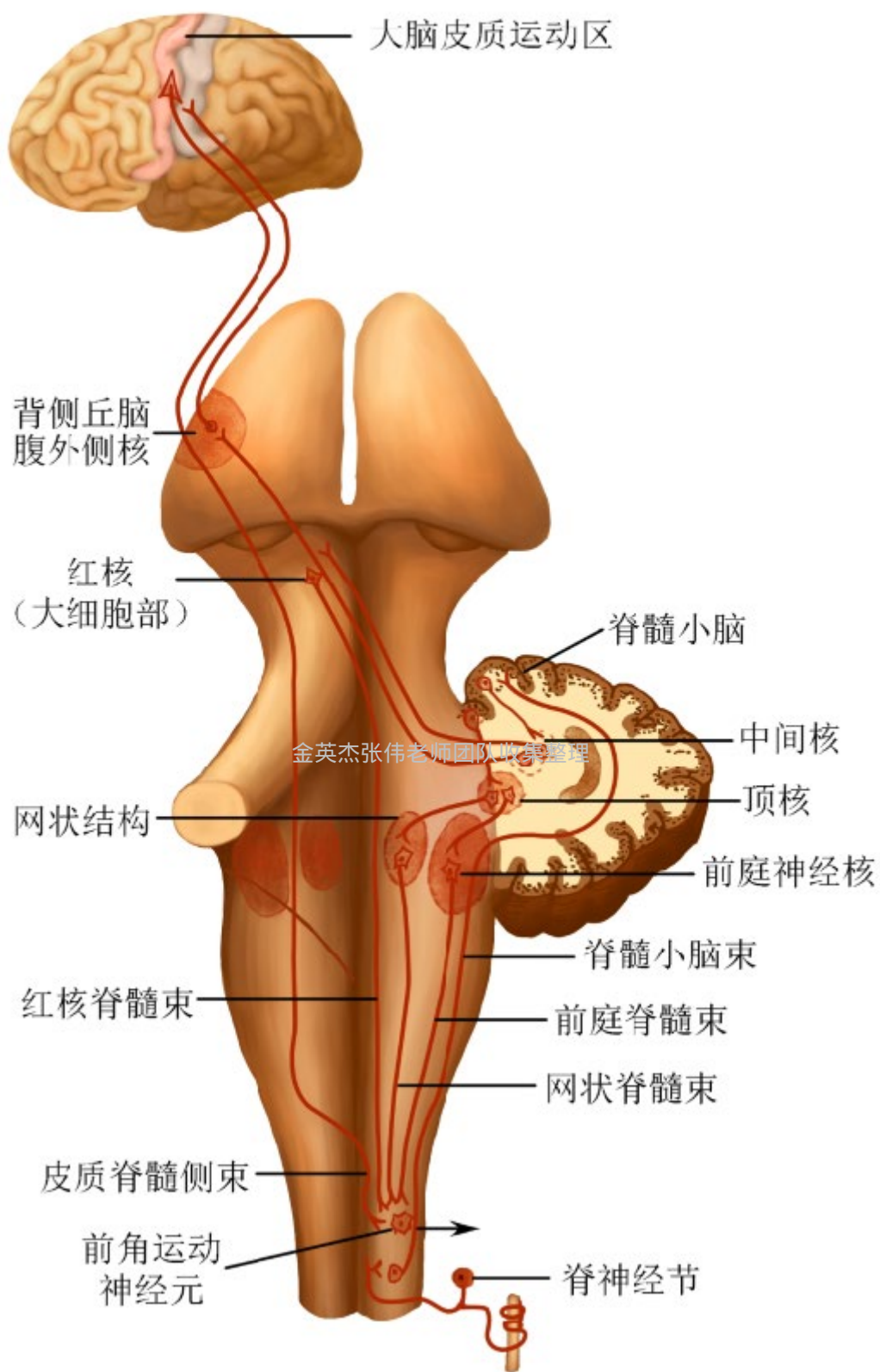




金英杰张伟老师

获取更多医考资料请关注

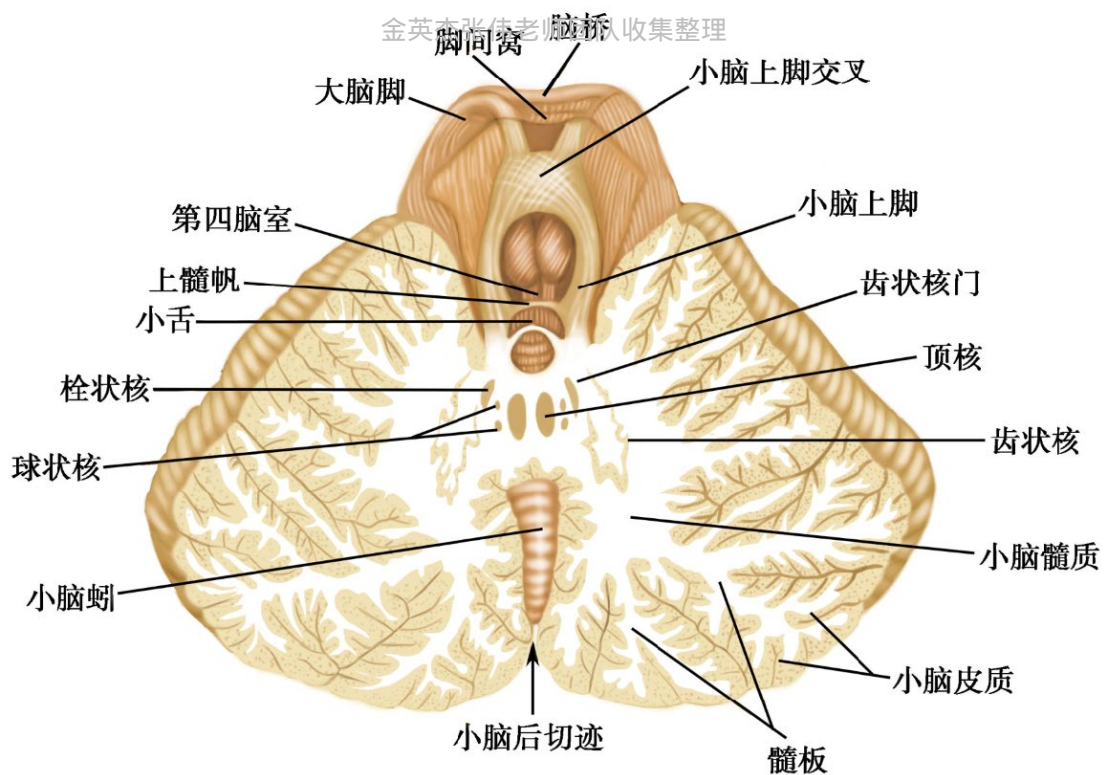
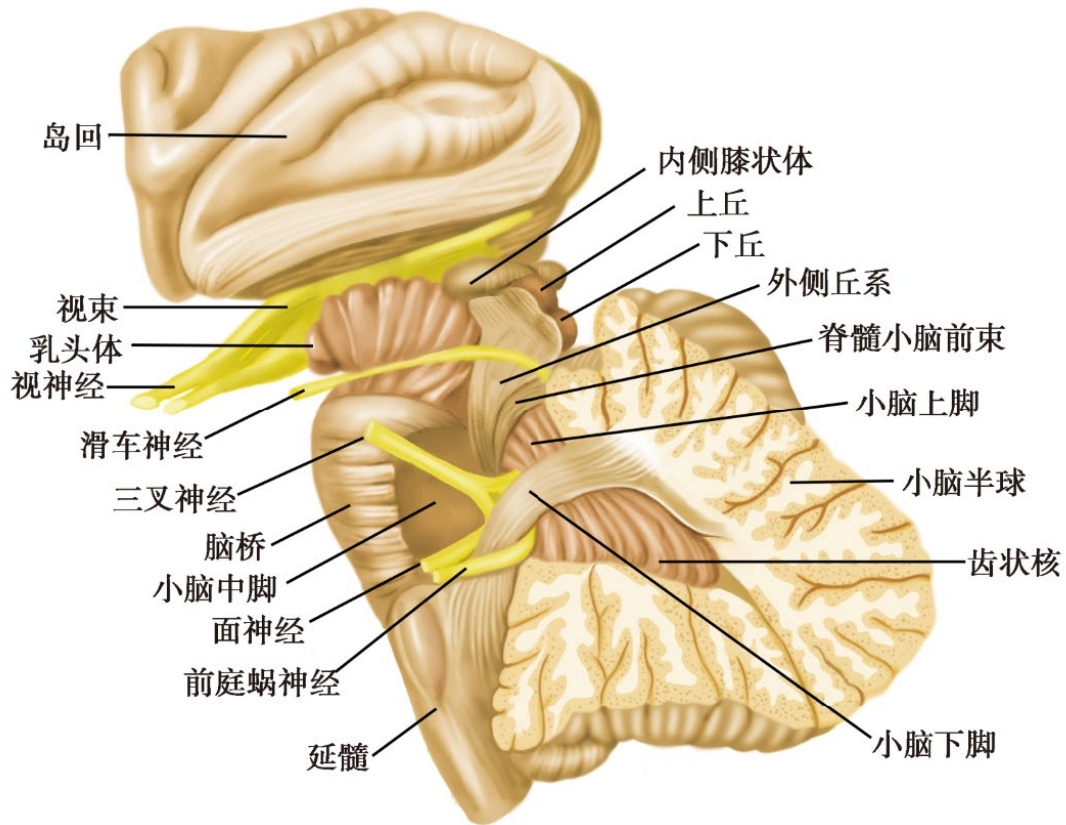




金英杰张伟老师

获取更多医考资料请关注





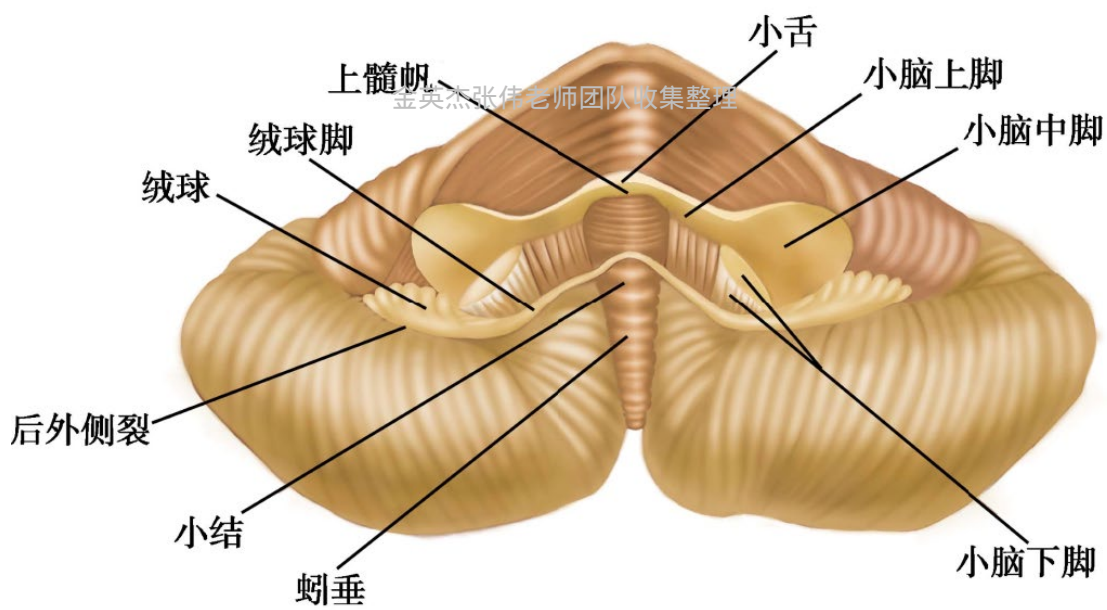
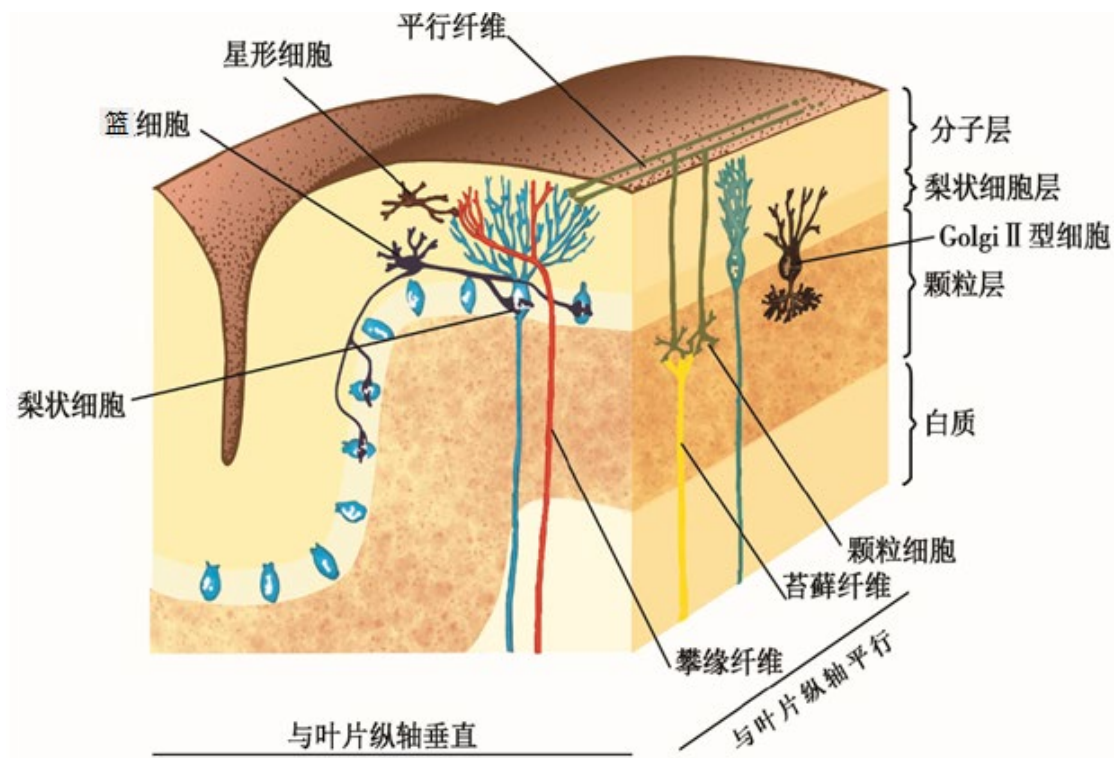
金英杰张伟老师团队收集整理



金英杰张伟老师

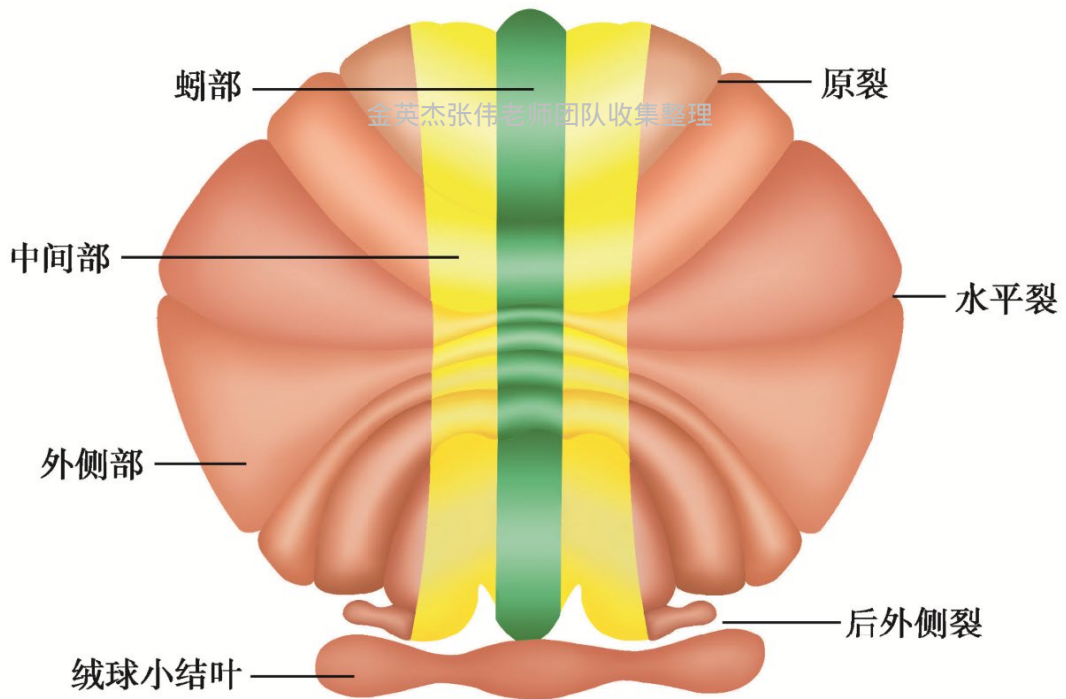
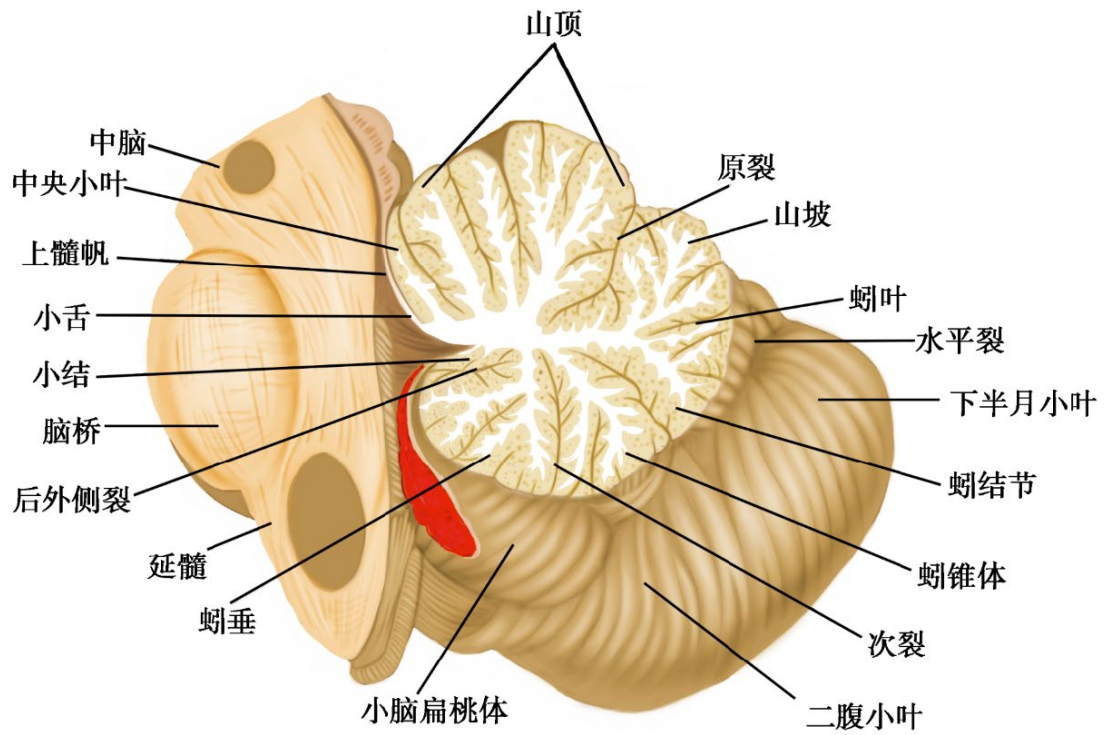
获取更多医考资料请关注





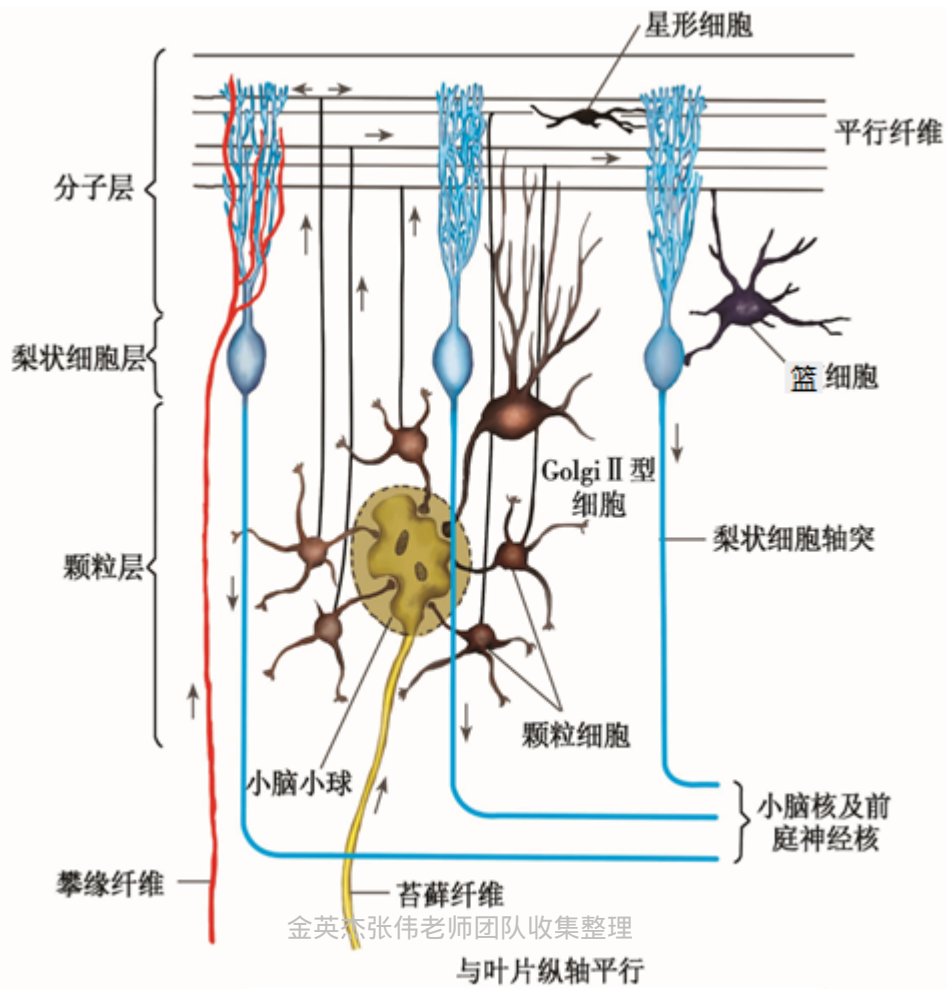
获取更多医考资料请关注





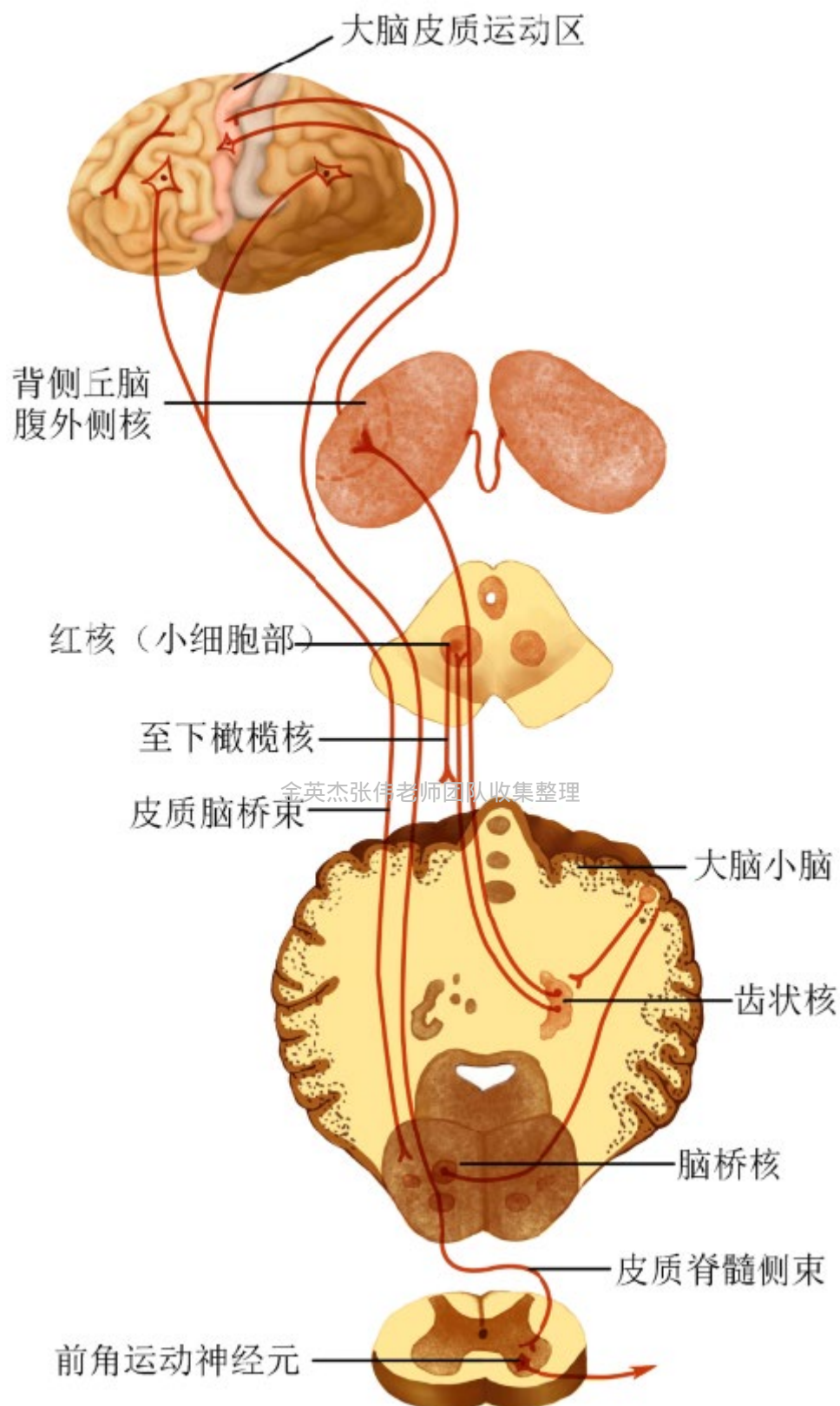
获取更多医考资料请关注





获取更多医考资料请关注

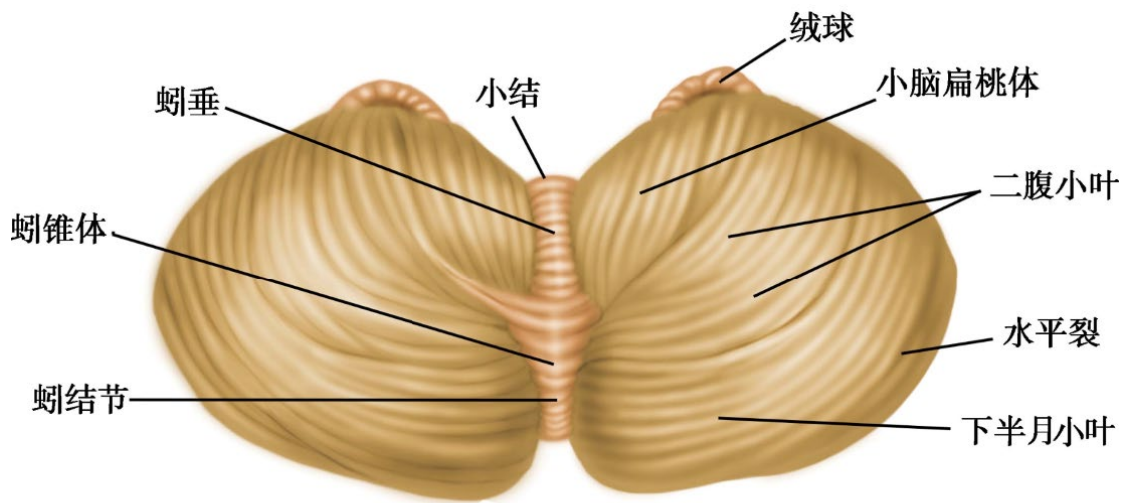




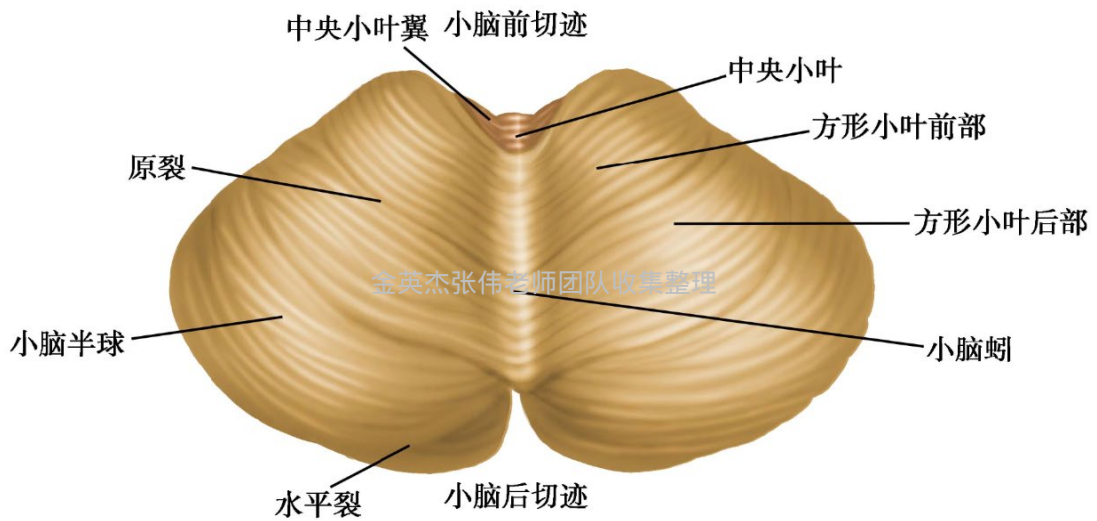
金英杰张伟老师

获取更多医考资料请关注





小脑后切迹

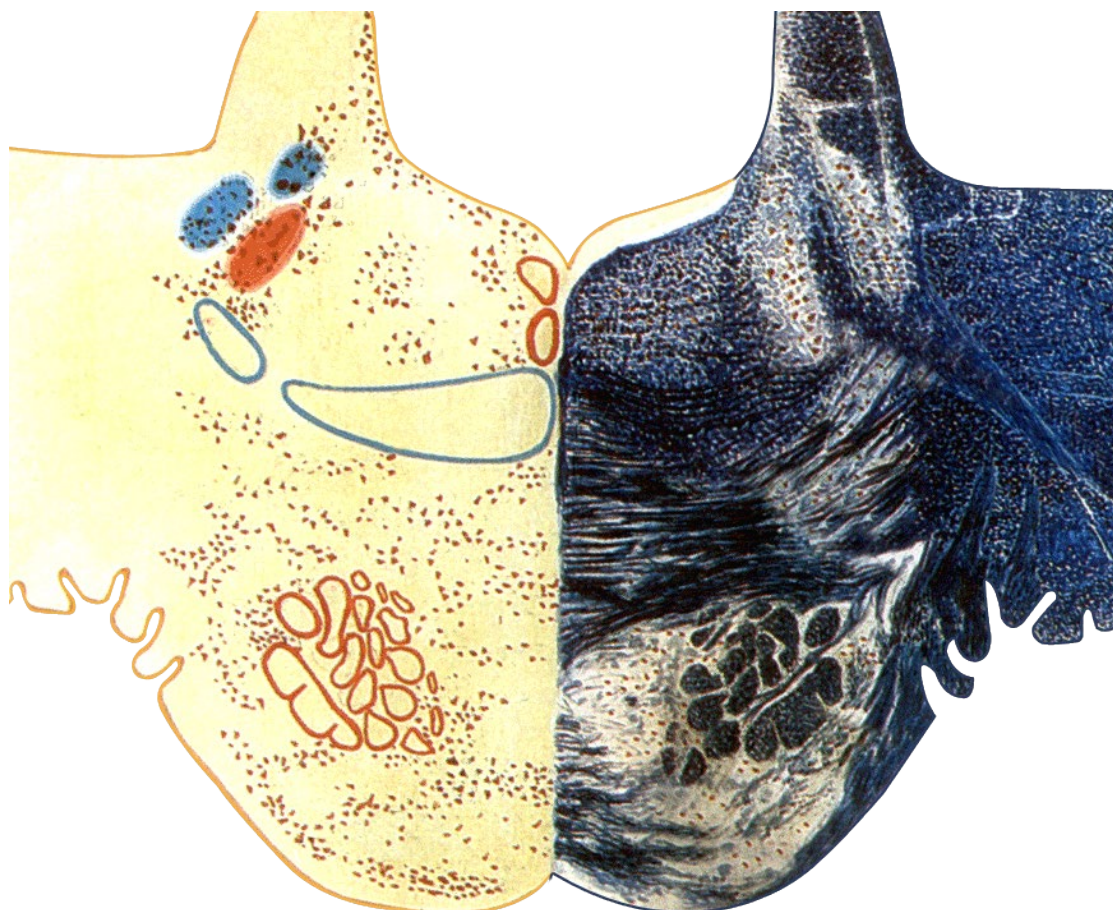


金英杰张伟老师团队收集整理

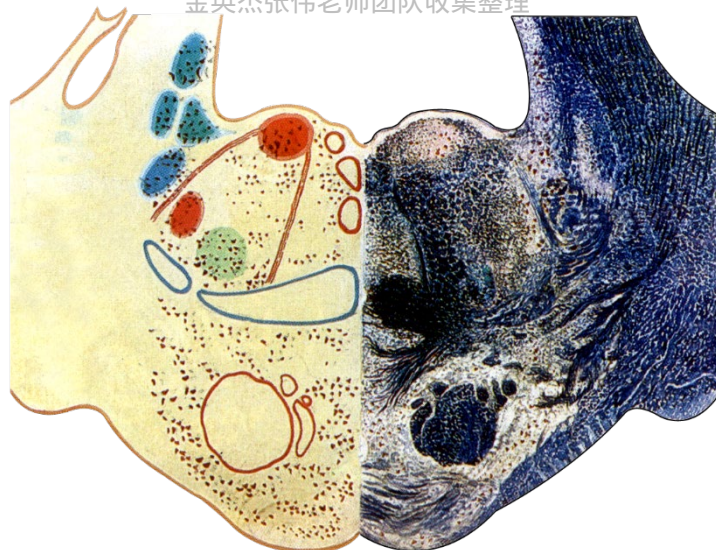


获取更多医考资料请关注





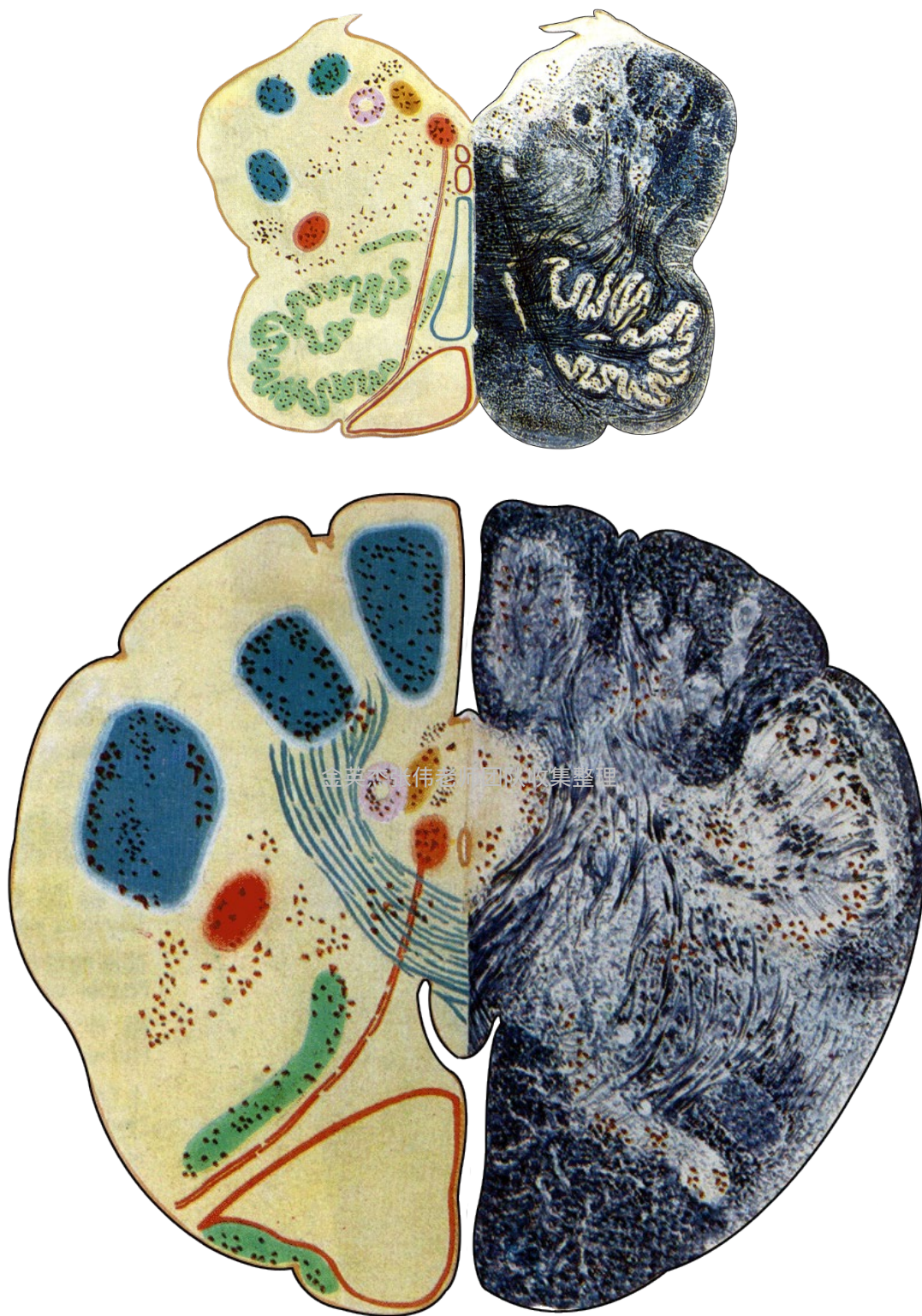金英杰张伟老师团队收集整理



金英杰张伟老师

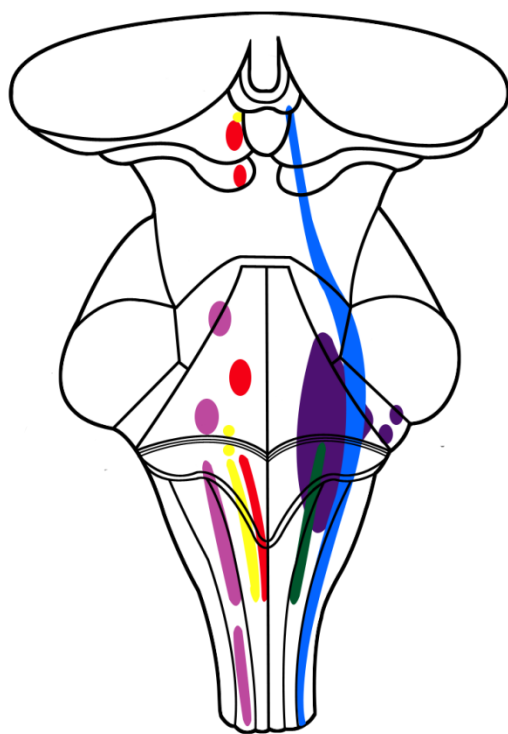
获取更多医考资料请关注





获取更多医考资料请关注



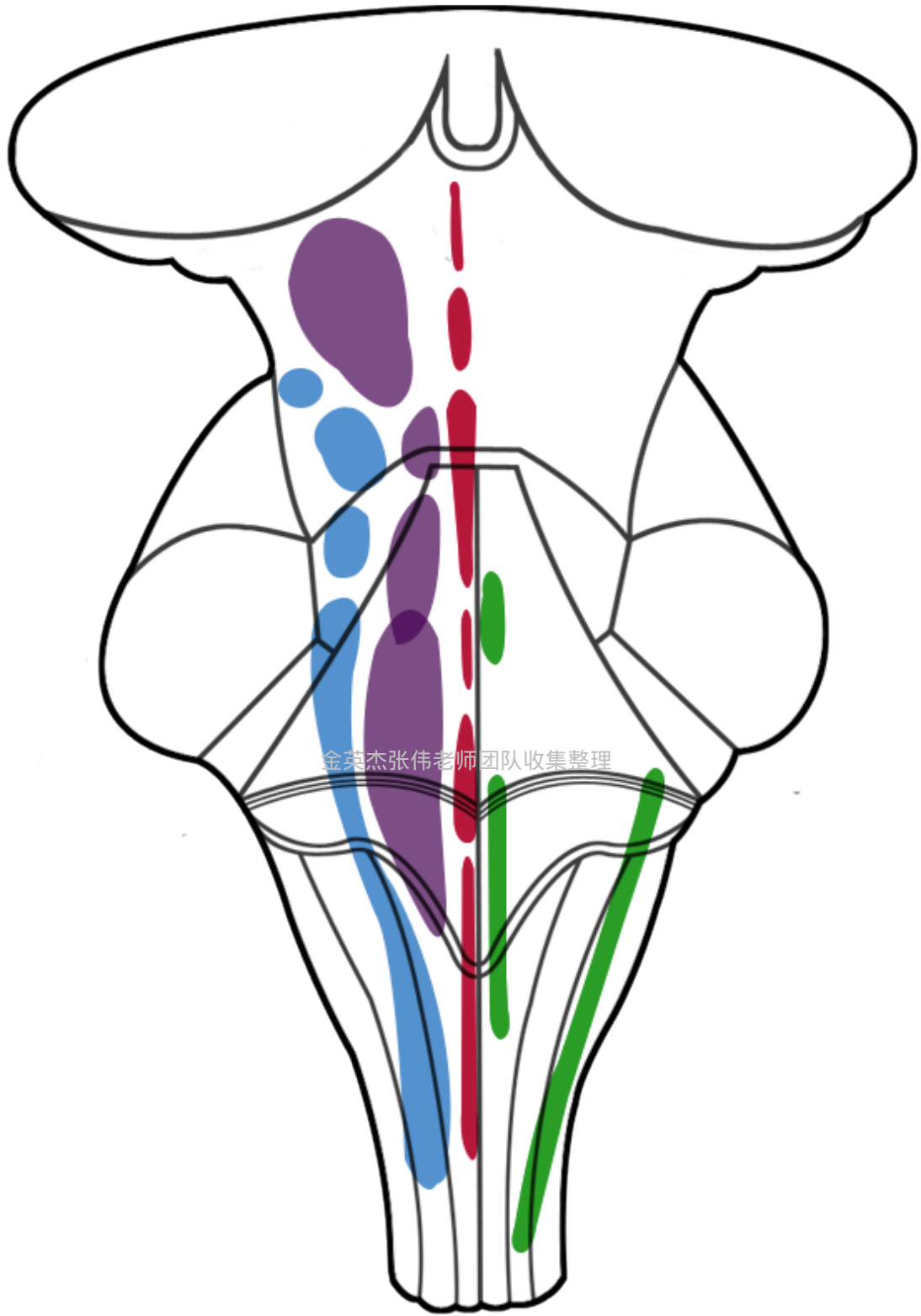


金英杰张伟老师团队收集整理



获取更多医考资料请关注





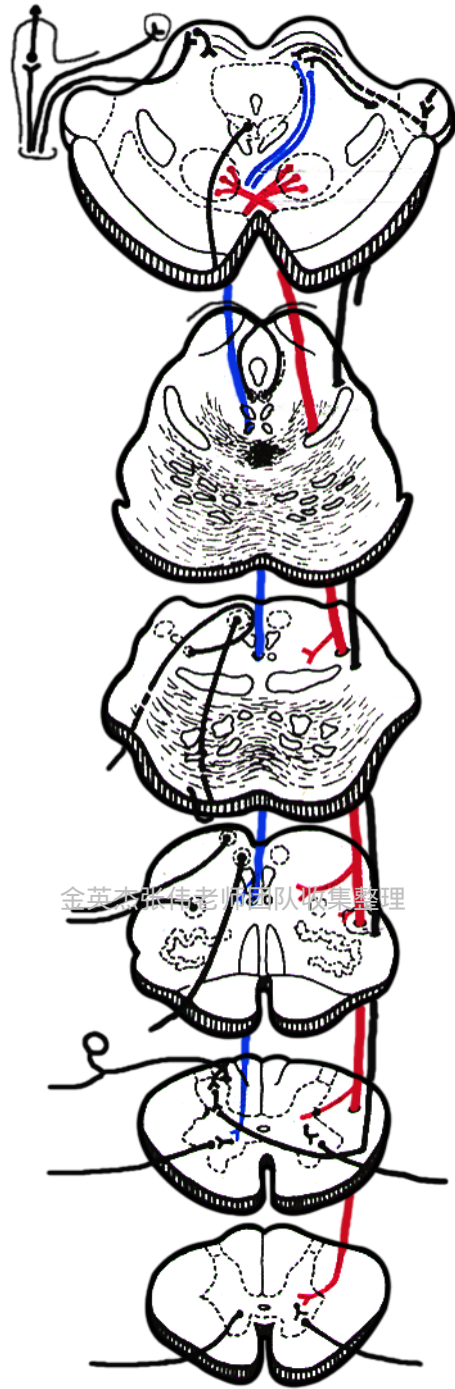
金英杰张伟老师团队收集整理



金英杰张伟老师

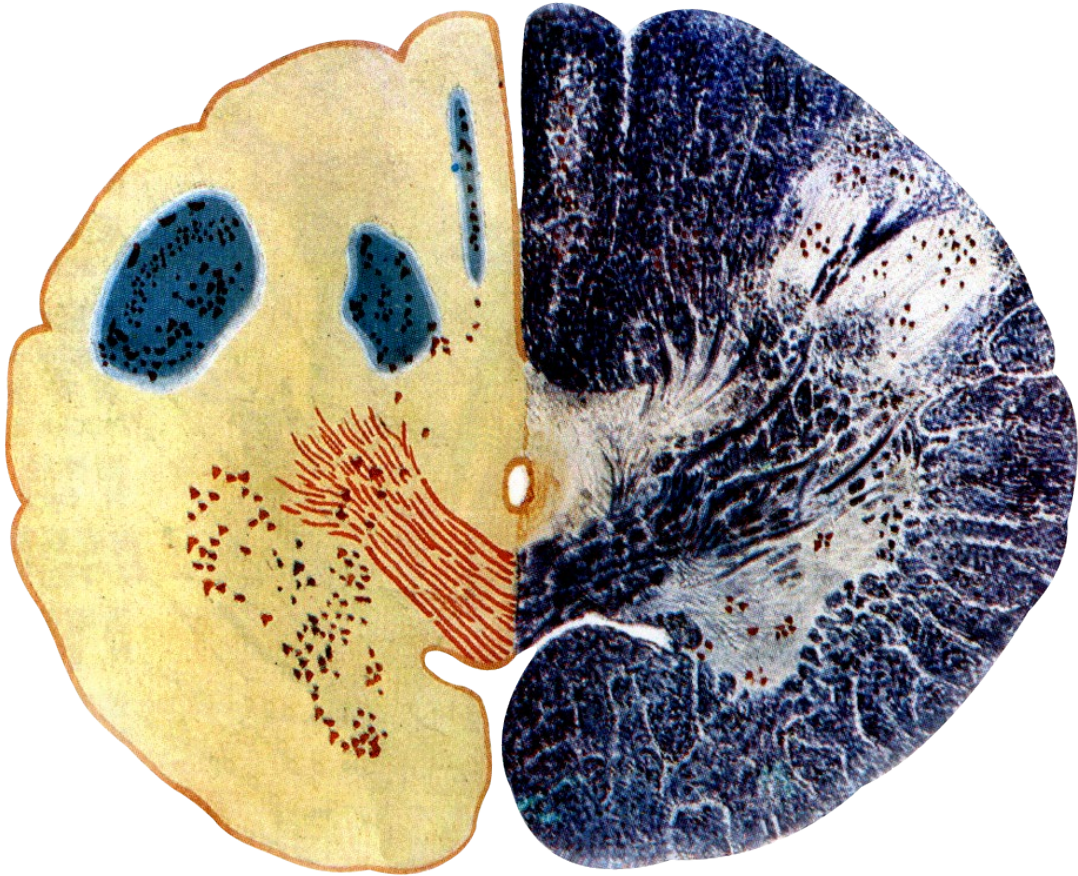获取更多医考资料请关注





获取更多医考资料请关注

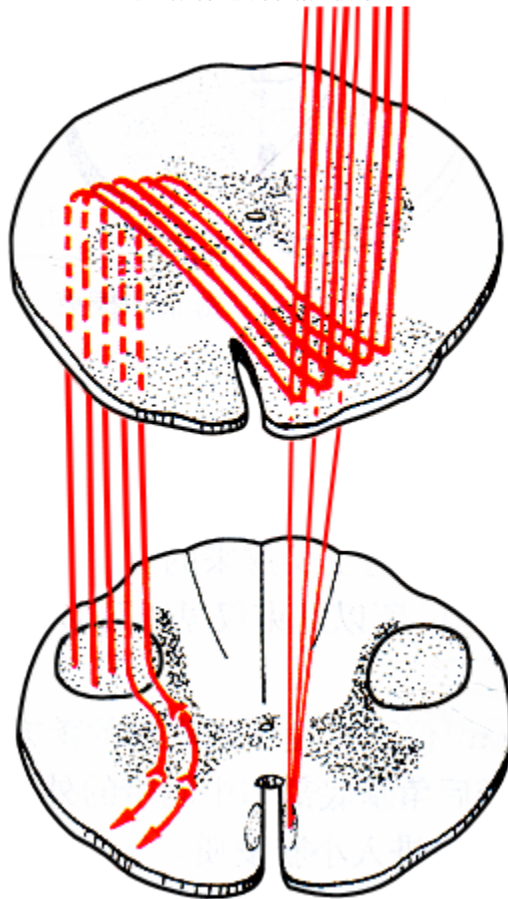




金英杰张伟老师团队收集整理

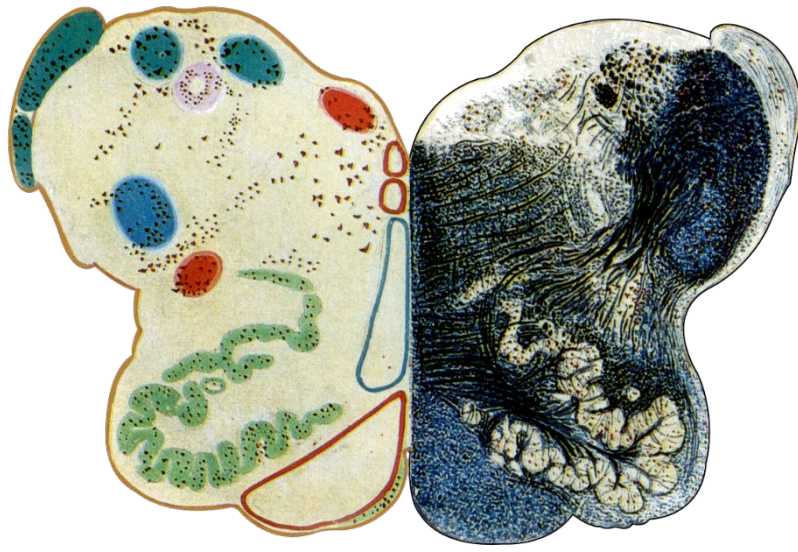


金英杰张伟老师



获取更多医考资料请关注



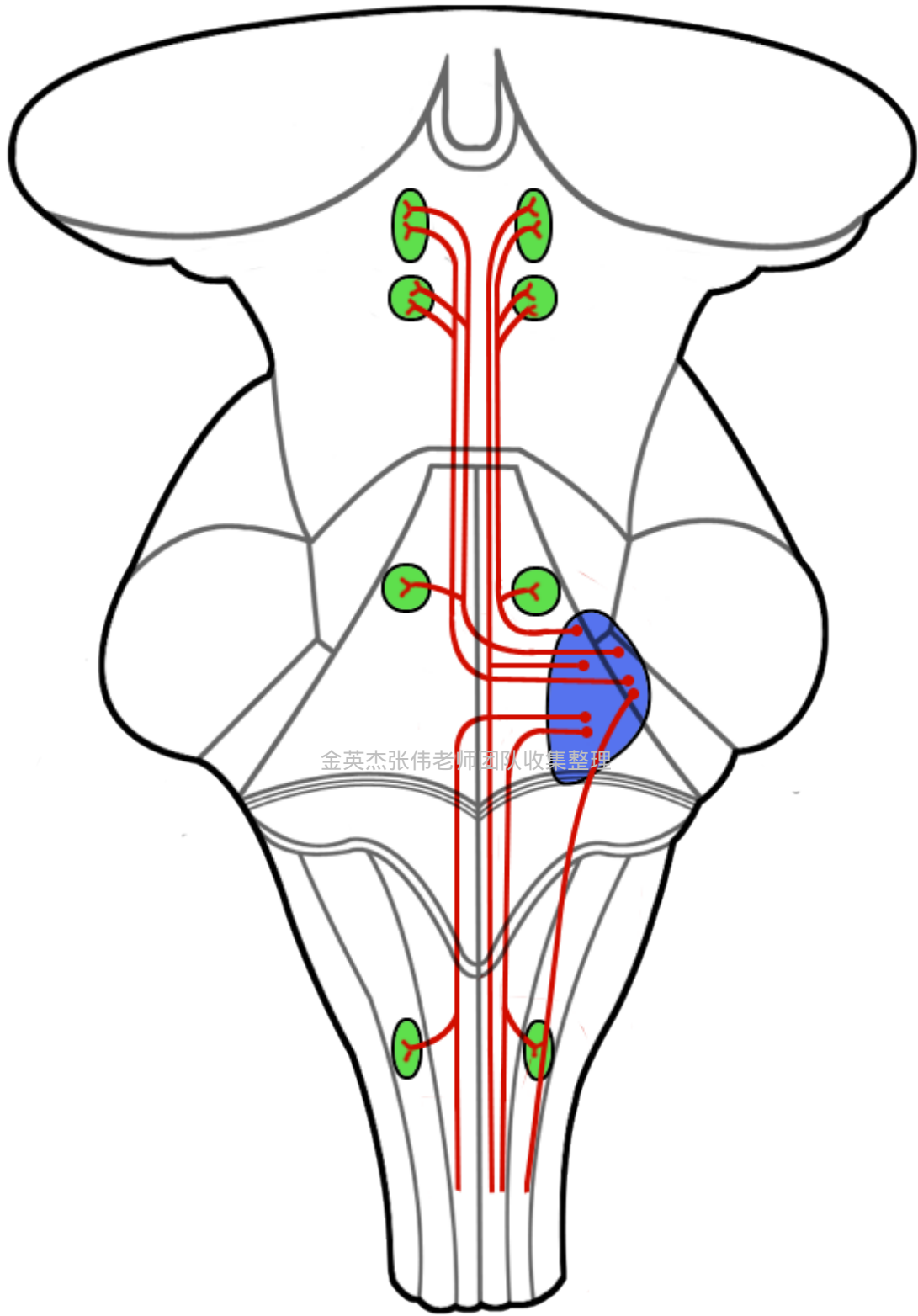


金英杰张伟老师团队收集整理



获取更多医考资料请关注

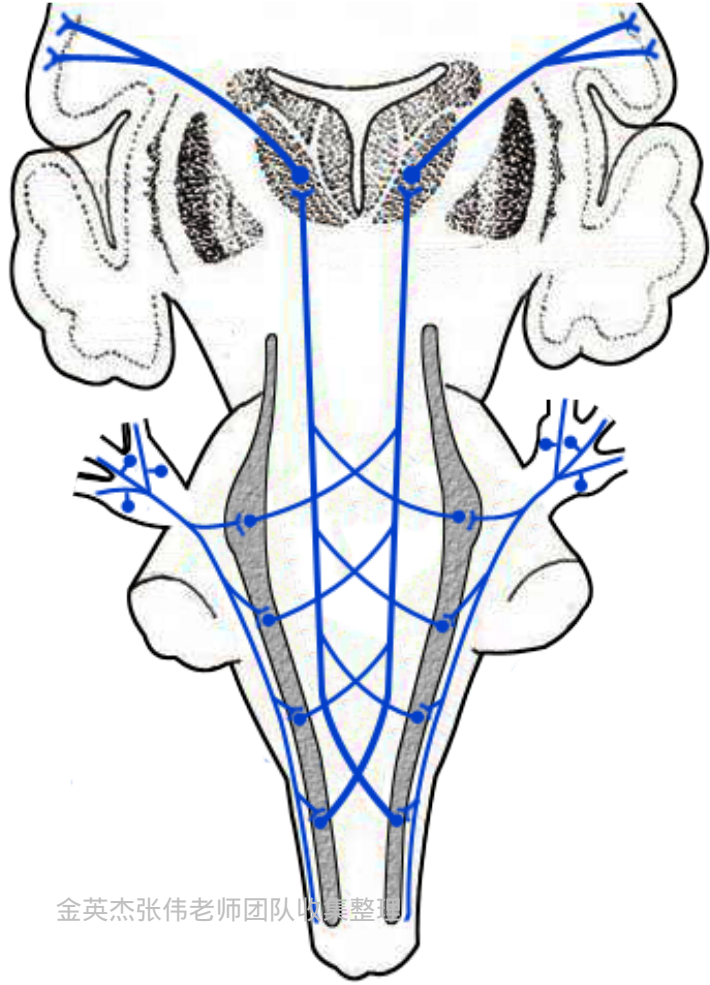





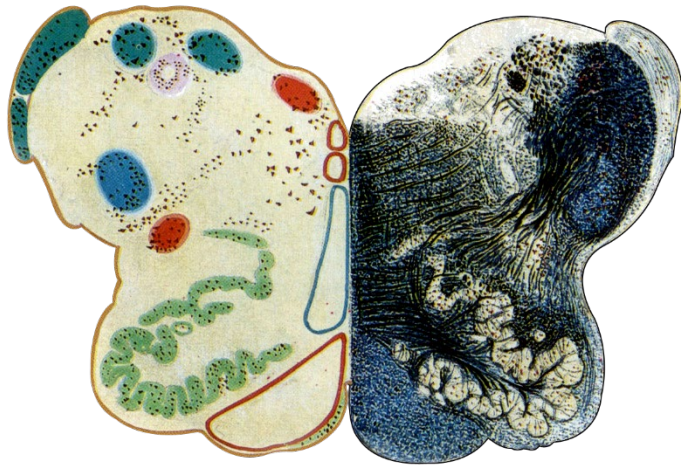
金英杰张伟老师

获取更多医考资料请关注



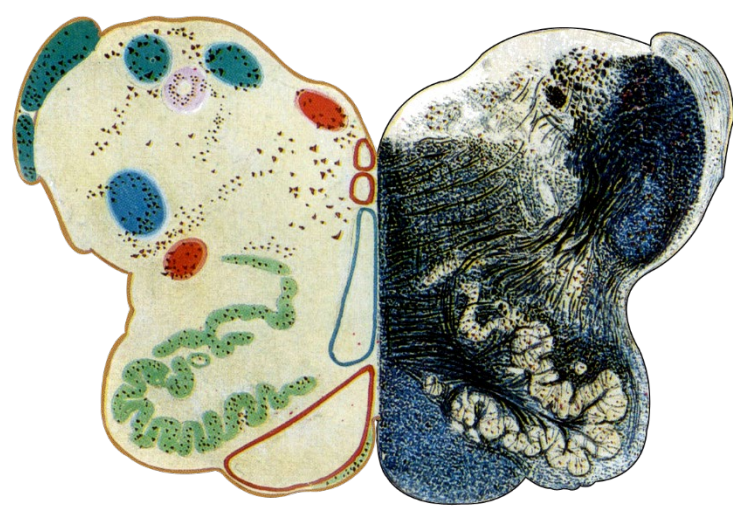
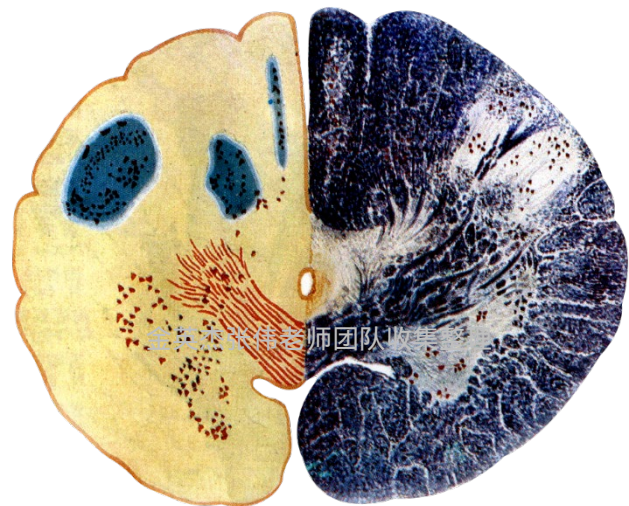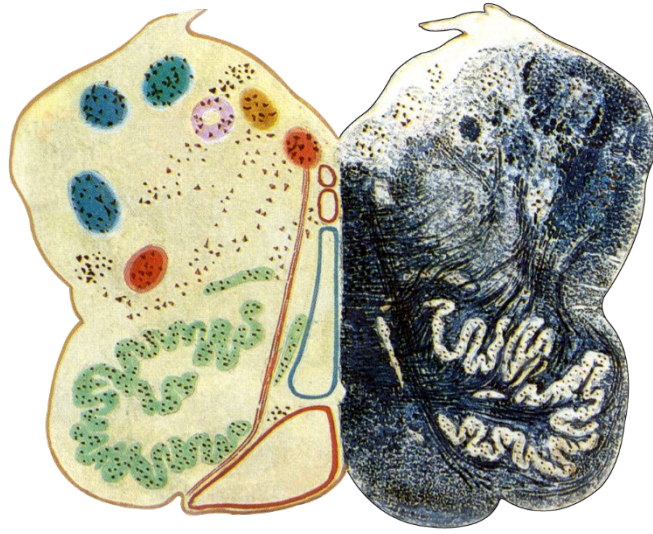


金英杰张伟老师团队收集整理



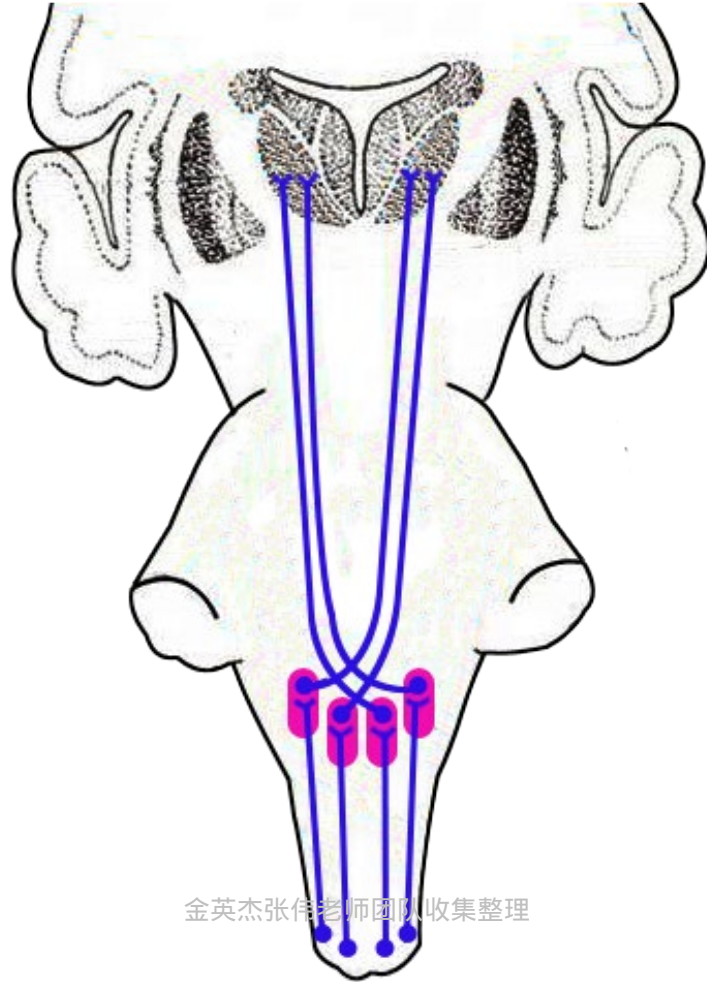
获取更多医考资料请关注



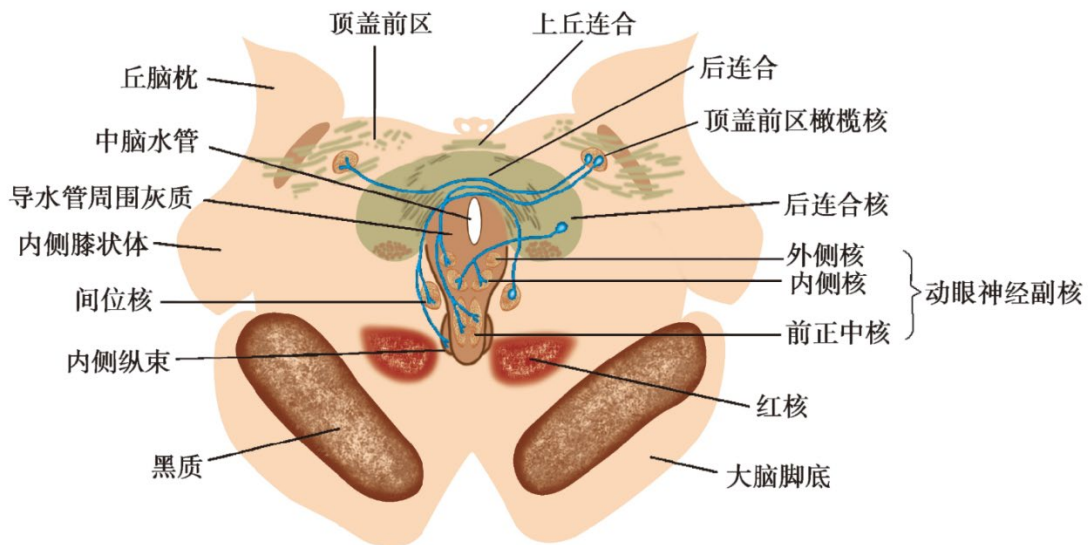


获取更多医考资料请关注



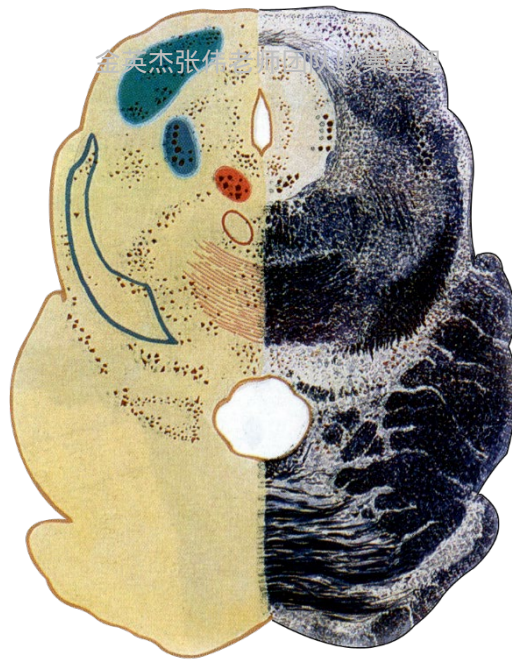
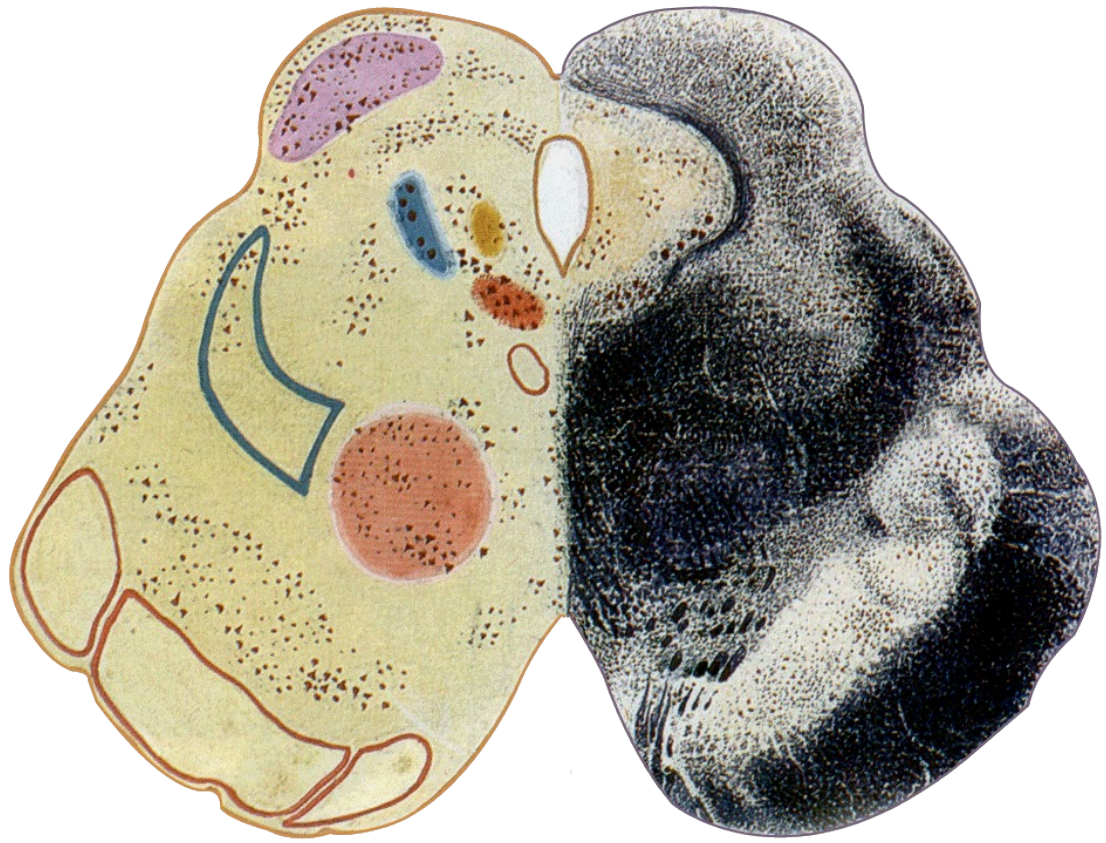


金英杰张伟老师团队收集整理



获取更多医考资料请关注

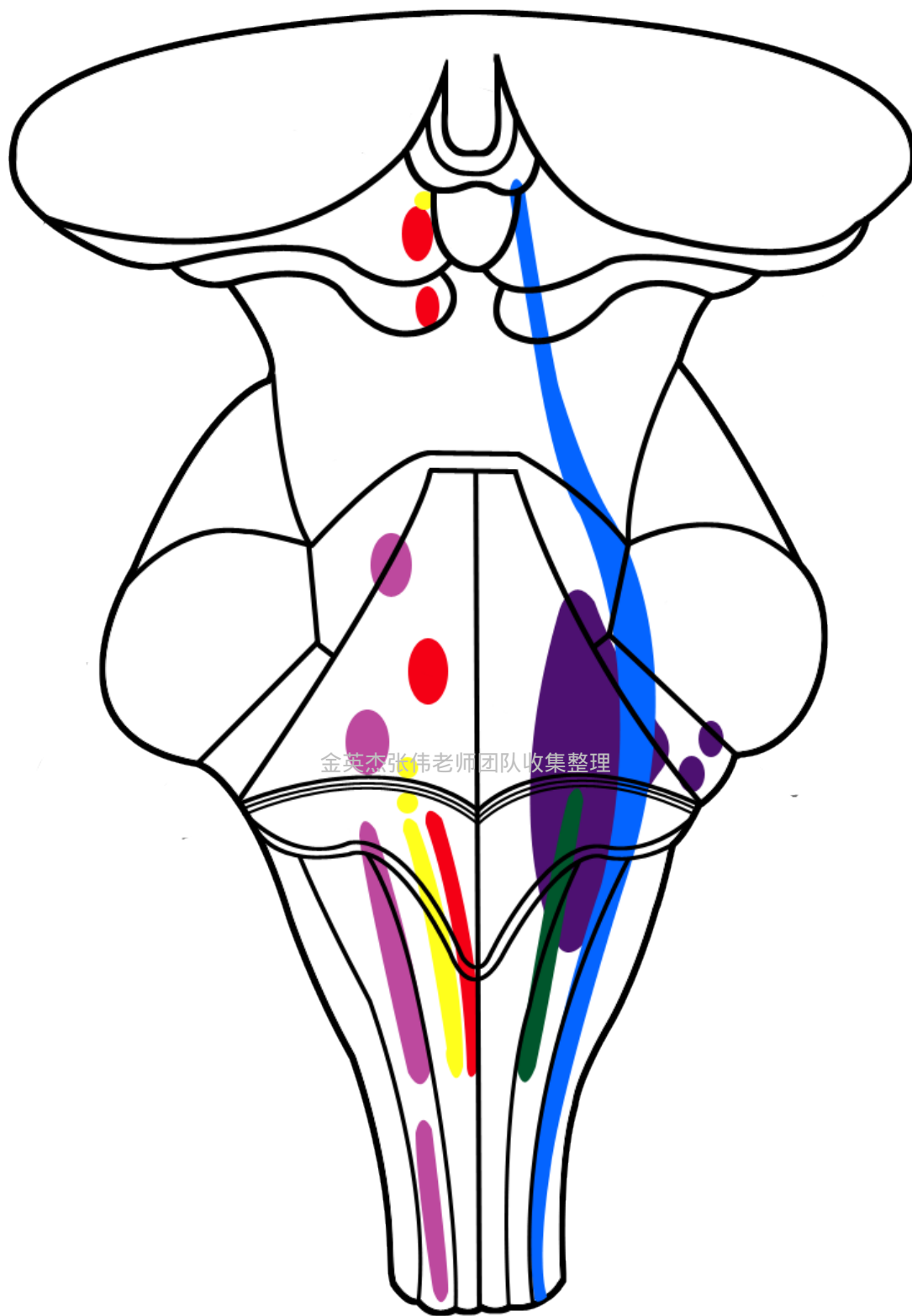




金英杰张伟大师

获取更多医考资料请关注





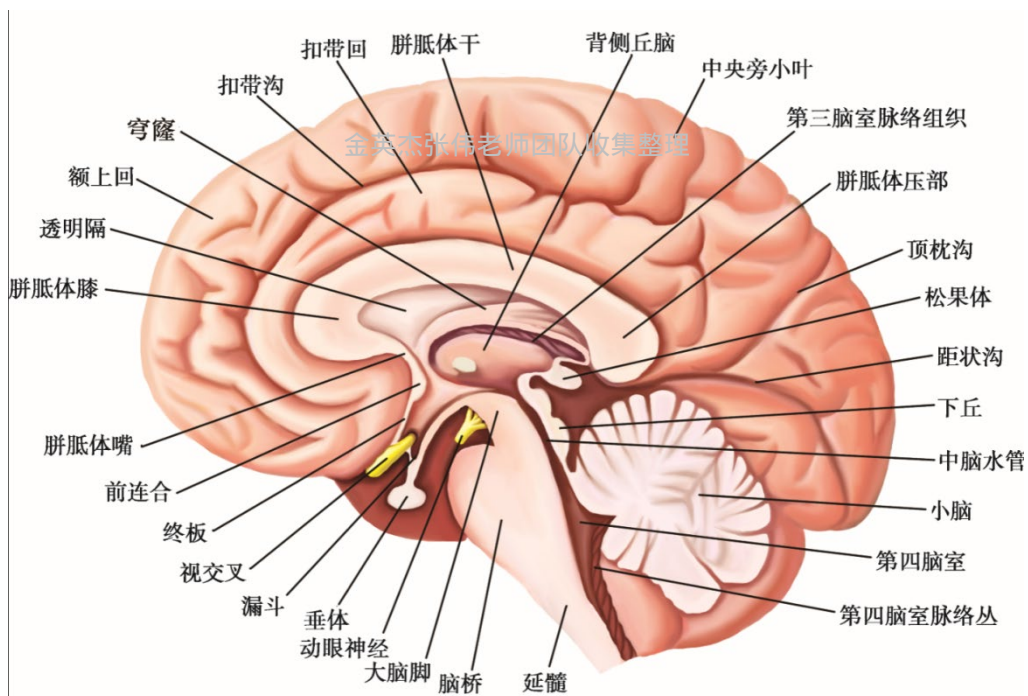
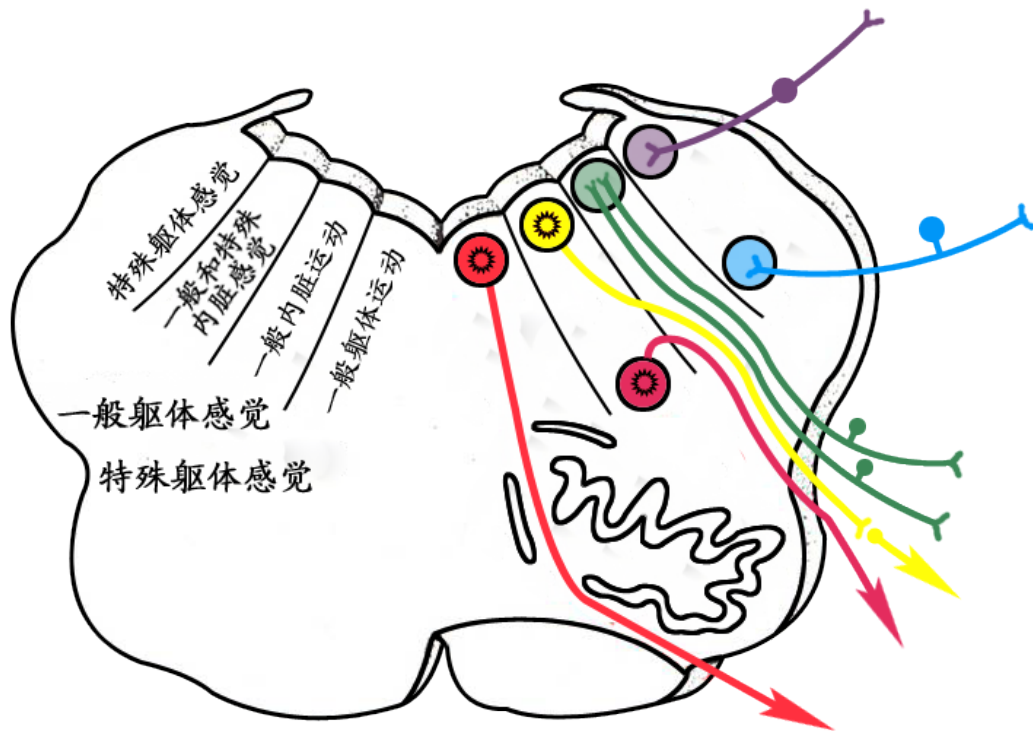
金英杰张伟老师团队收集整理



金英杰张伟老师

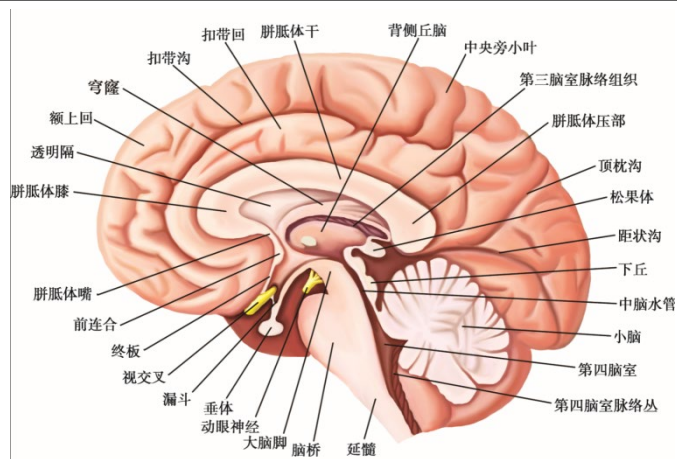
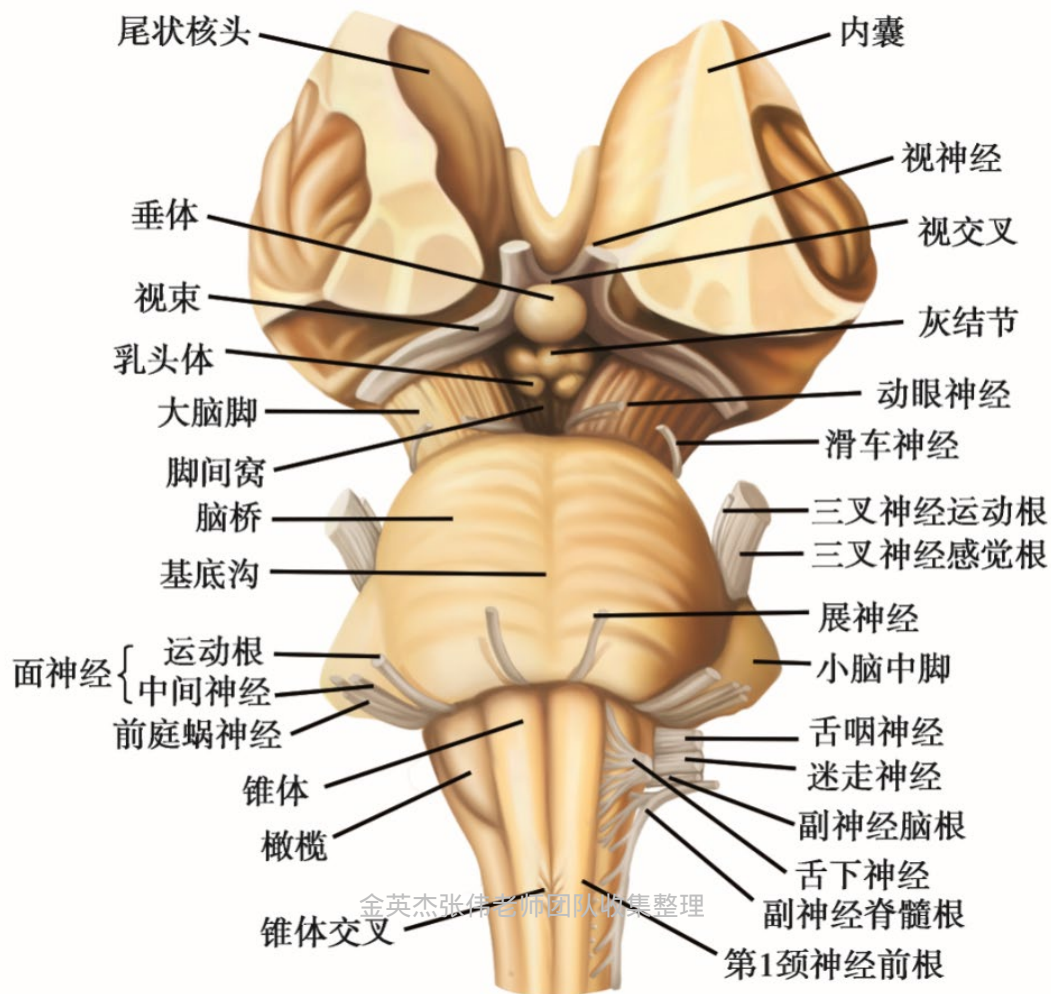
获取更多医考资料请关注





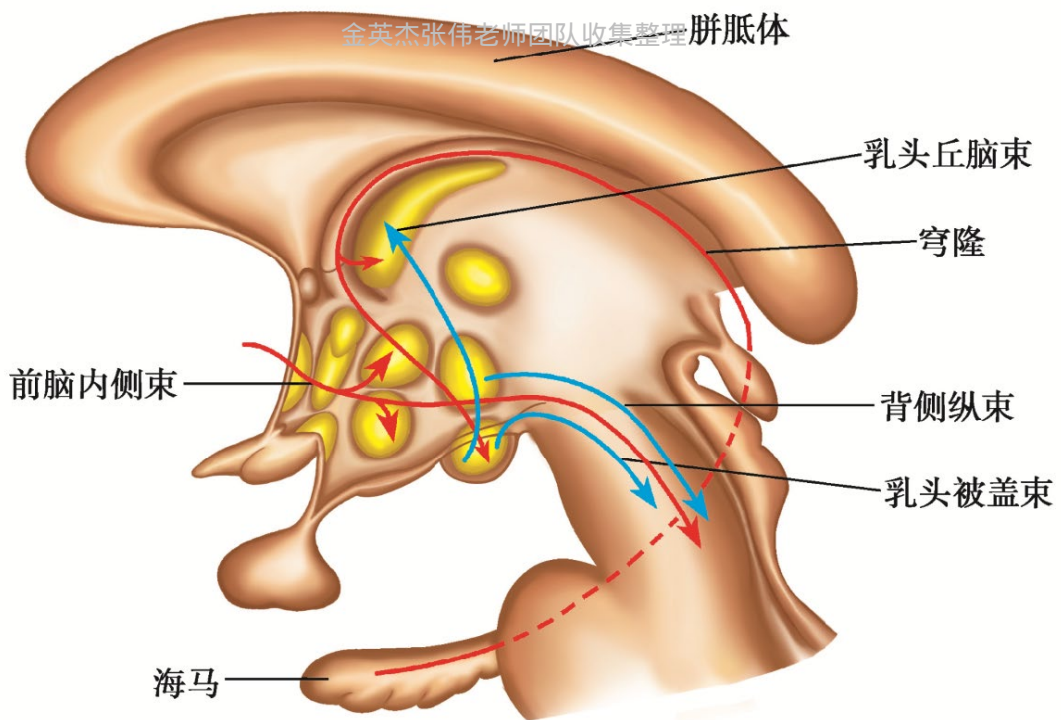
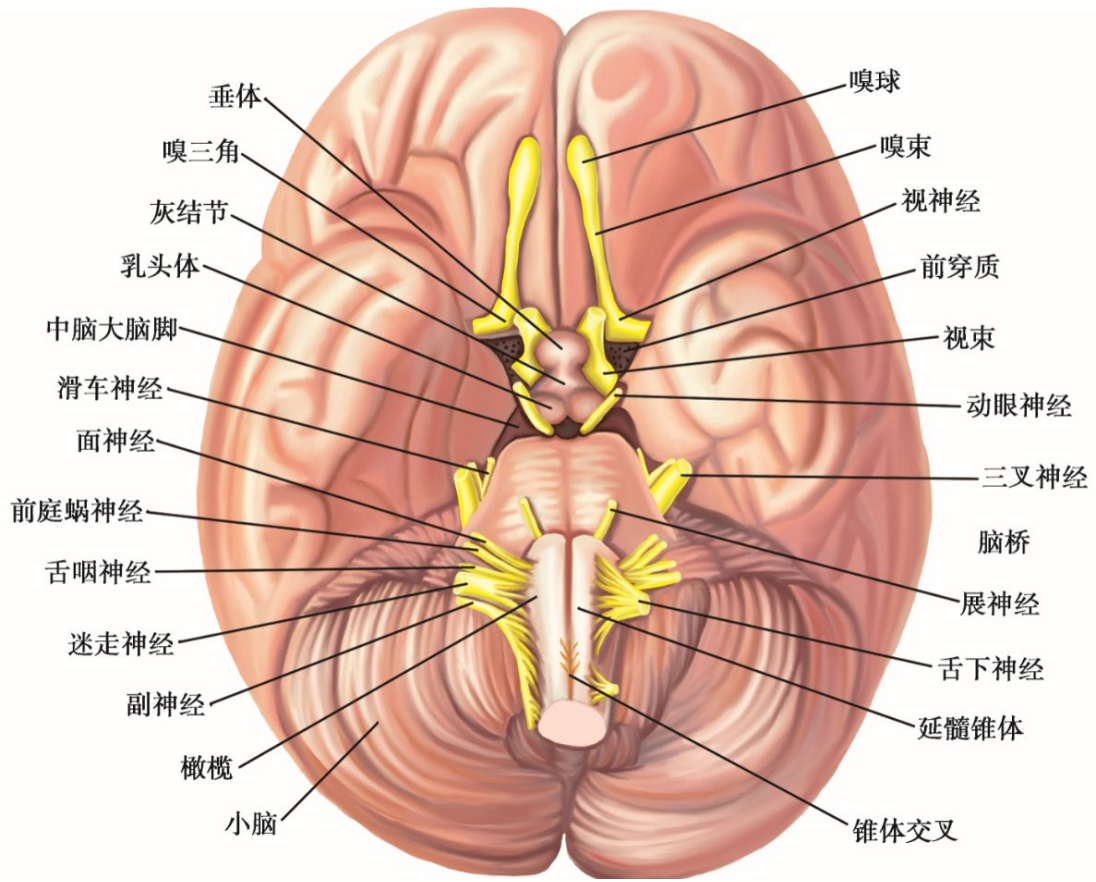
获取更多医考资料请关注





获取更多医考资料请关注

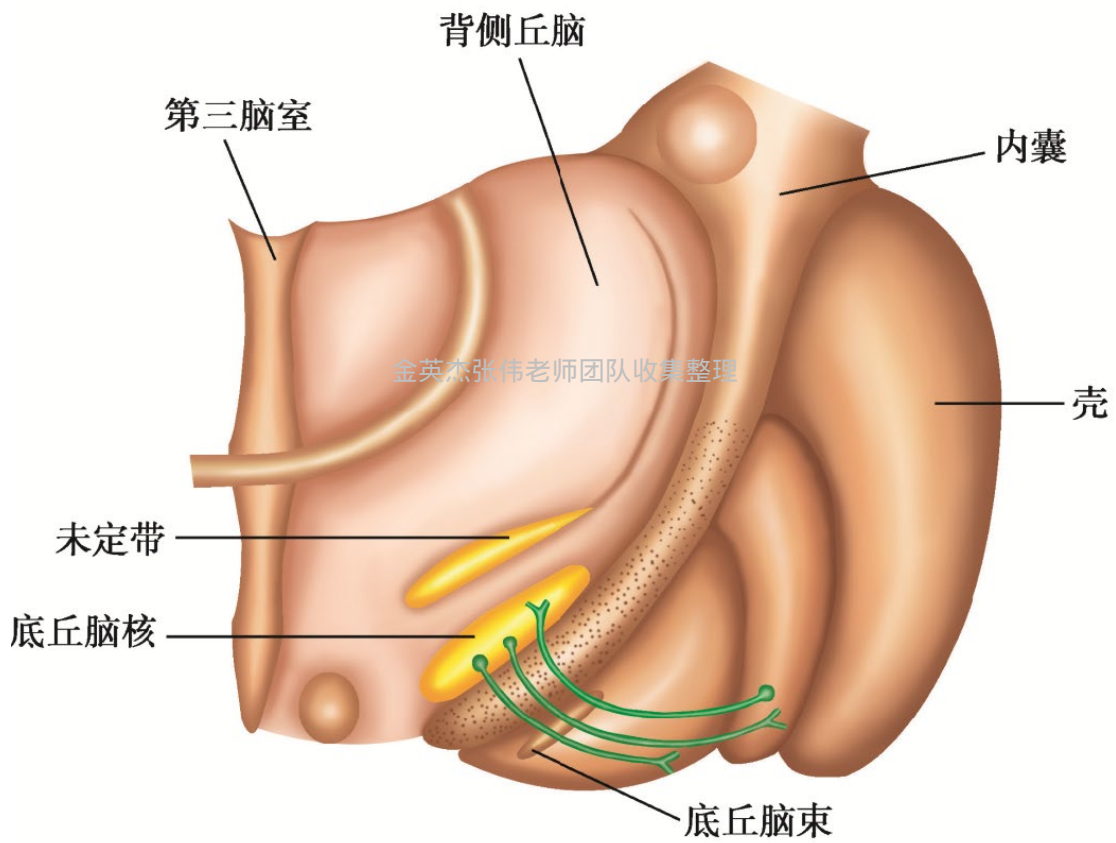
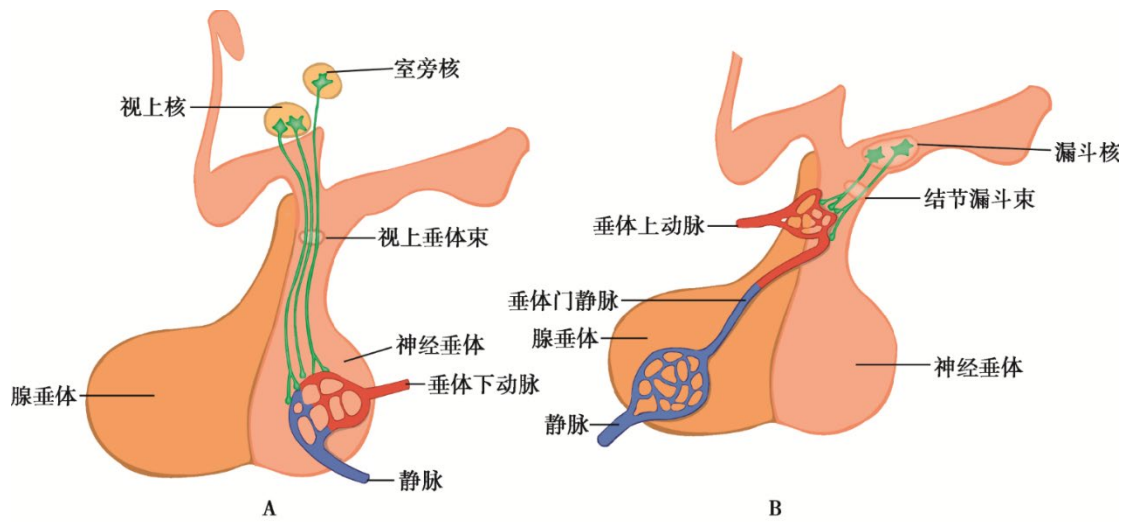




金英杰张伟老师

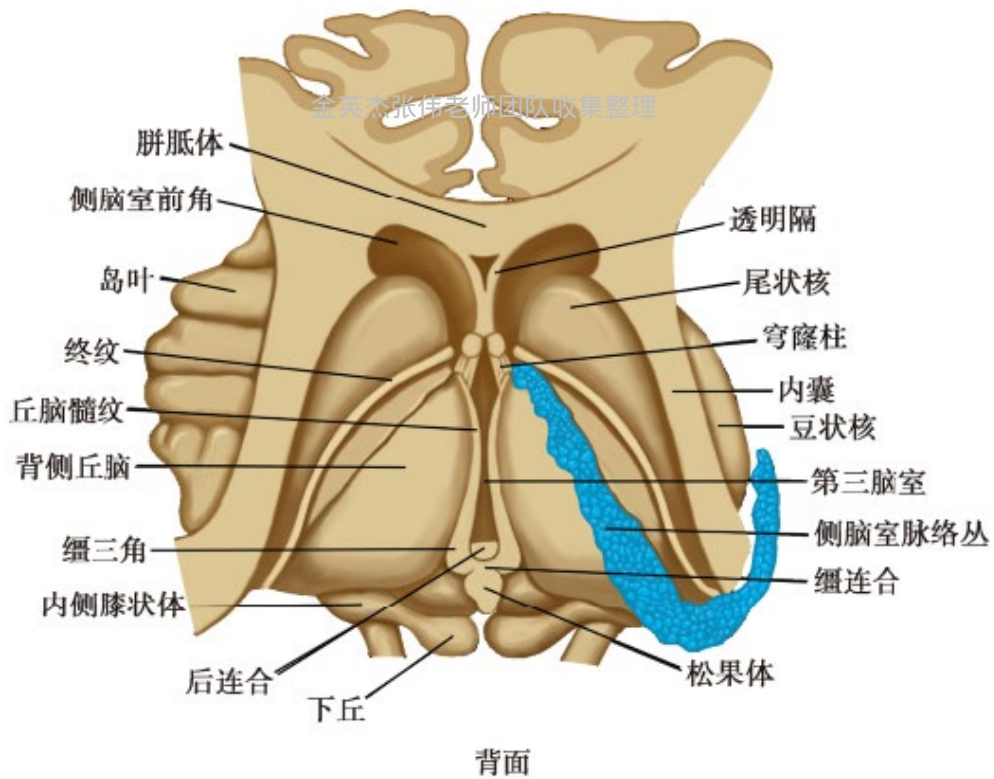
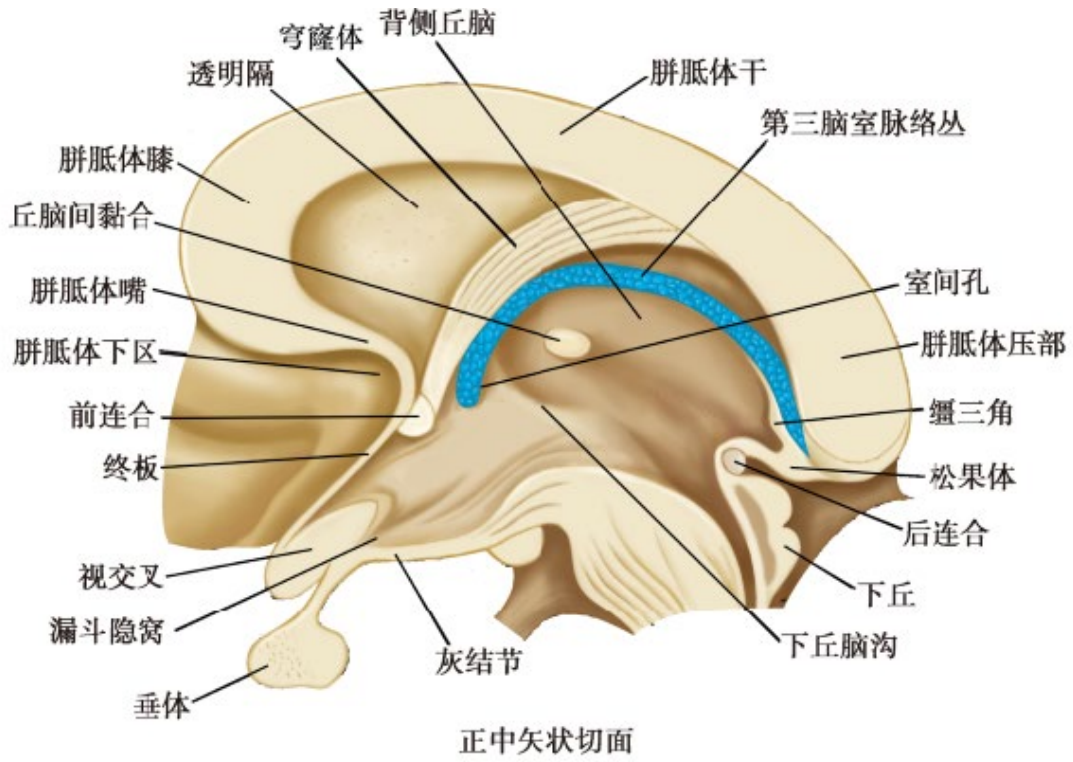
获取更多医考资料请关注





获取更多医考资料请关注





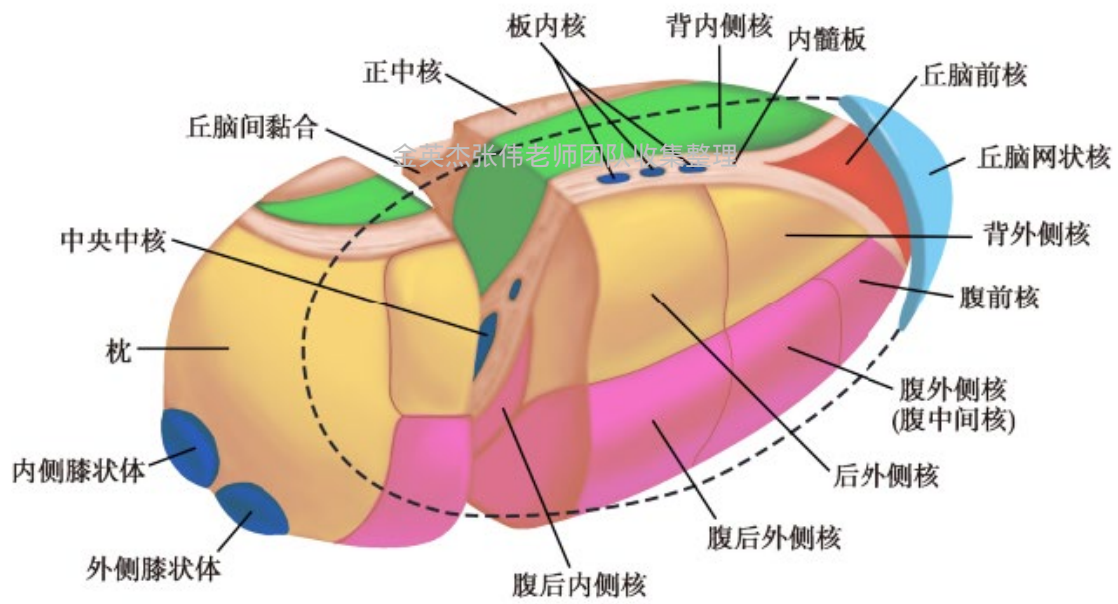
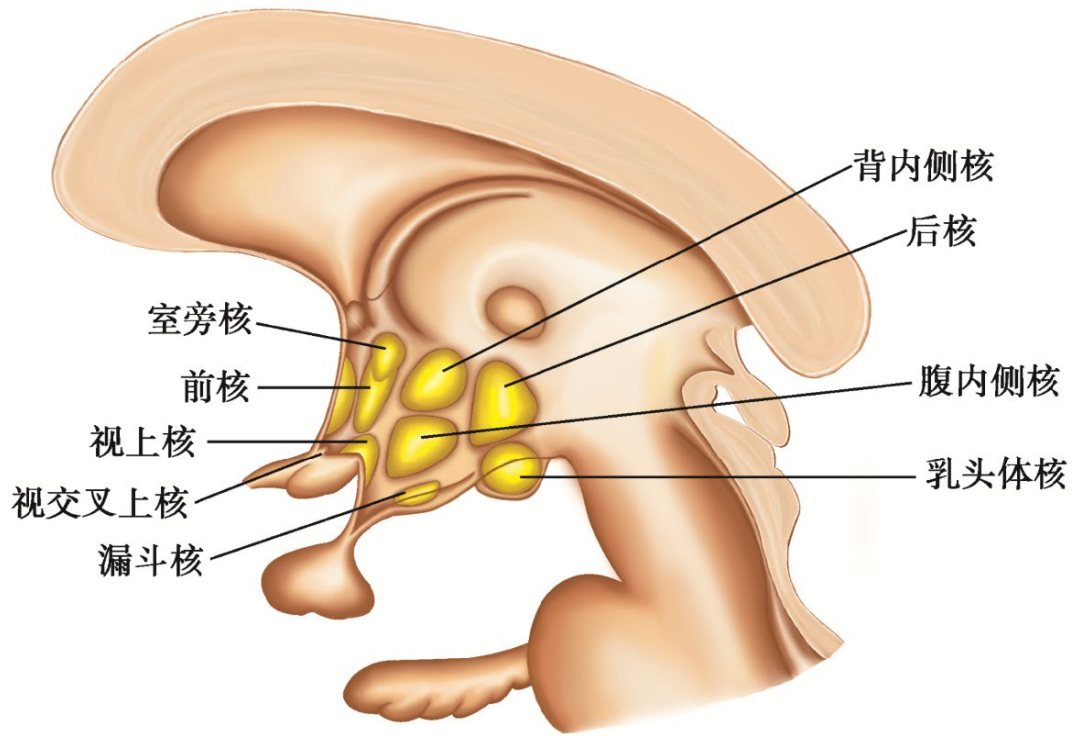
金英杰张伟老师团队收集整理



金英杰张伟老师

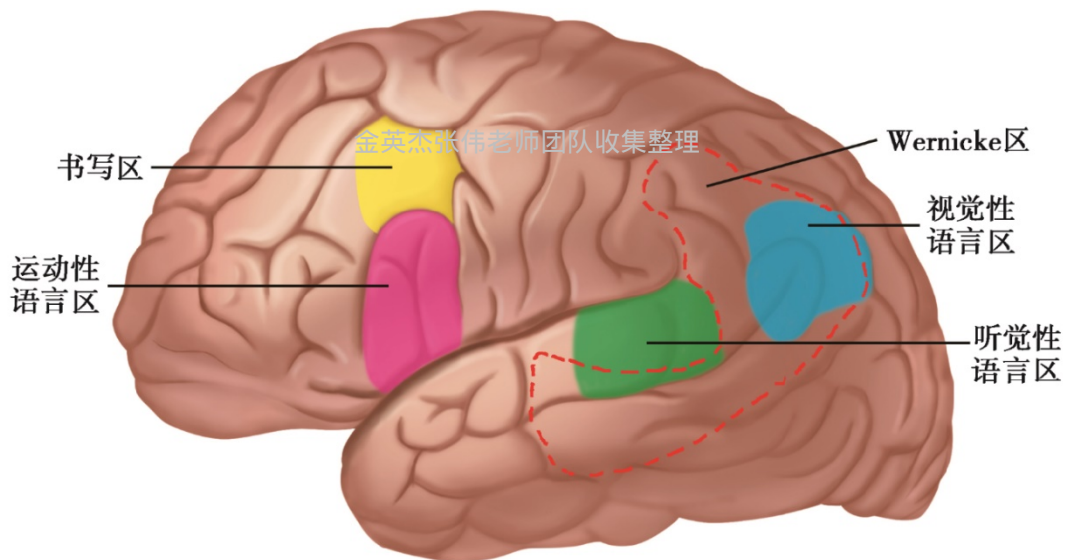
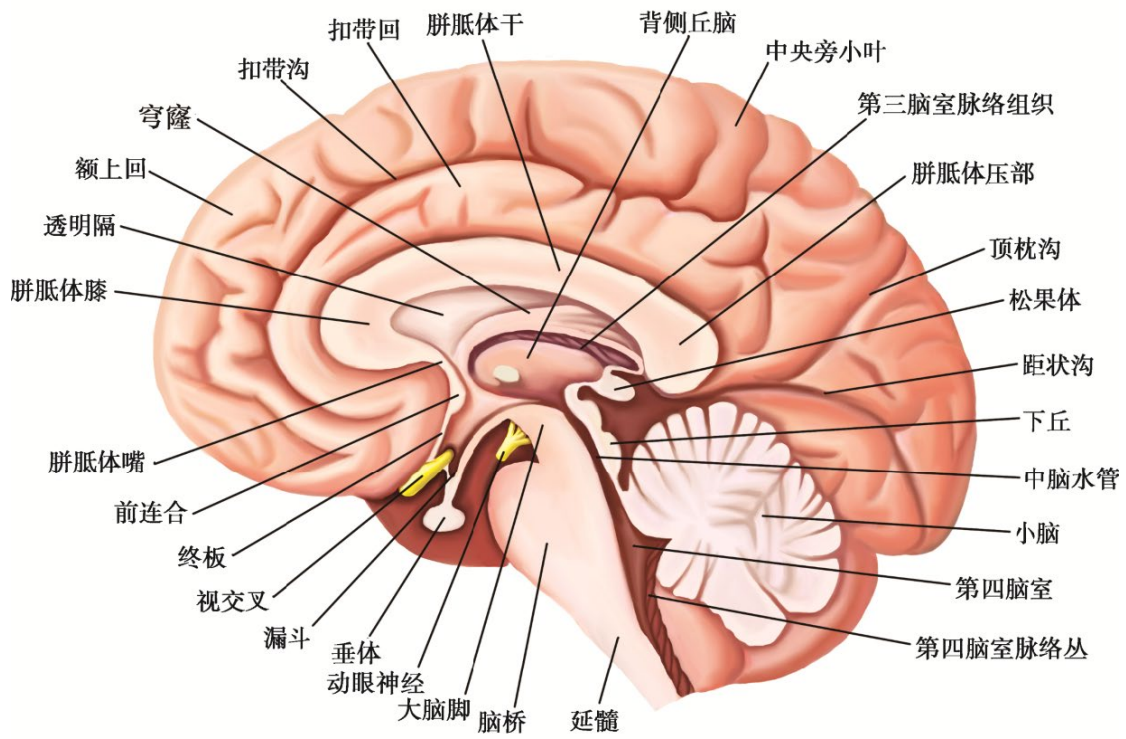
获取更多医考资料请关注





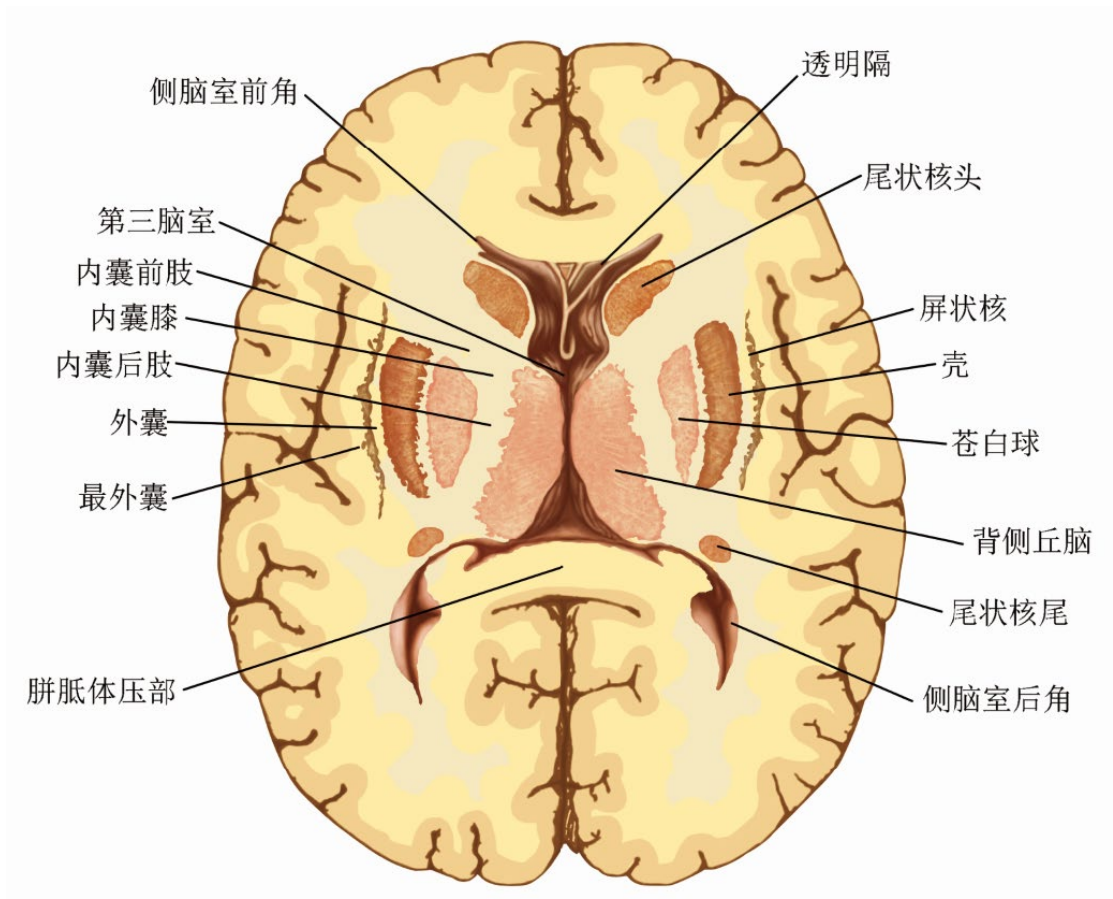
获取更多医考资料请关注



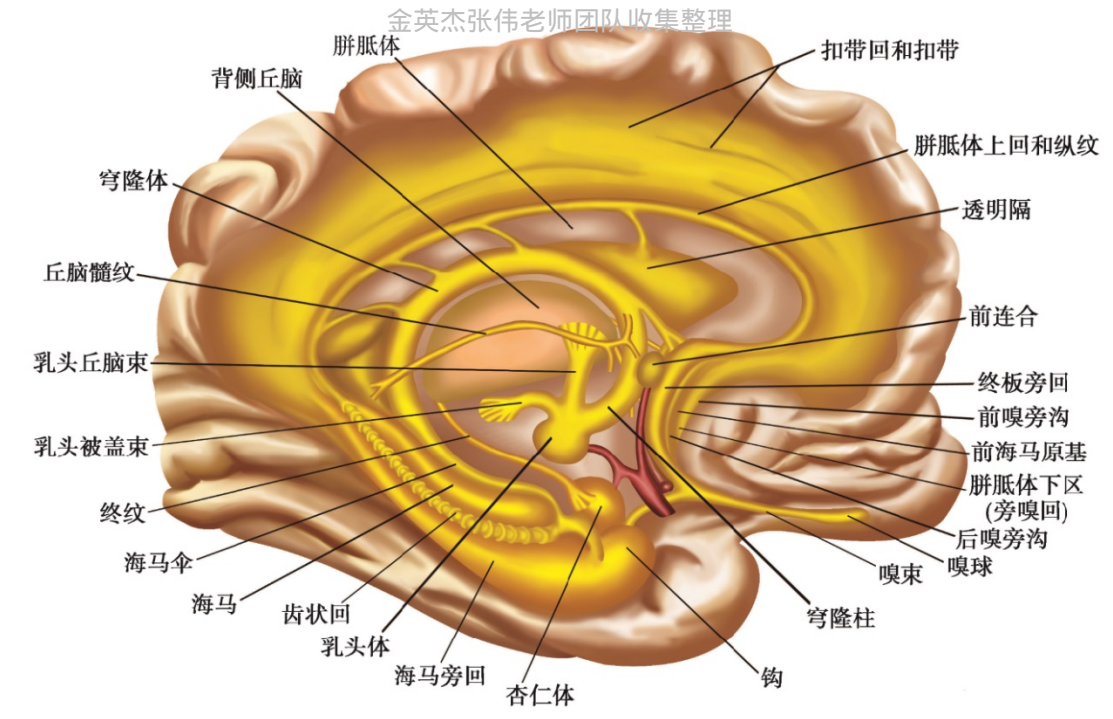


获取更多医考资料请关注



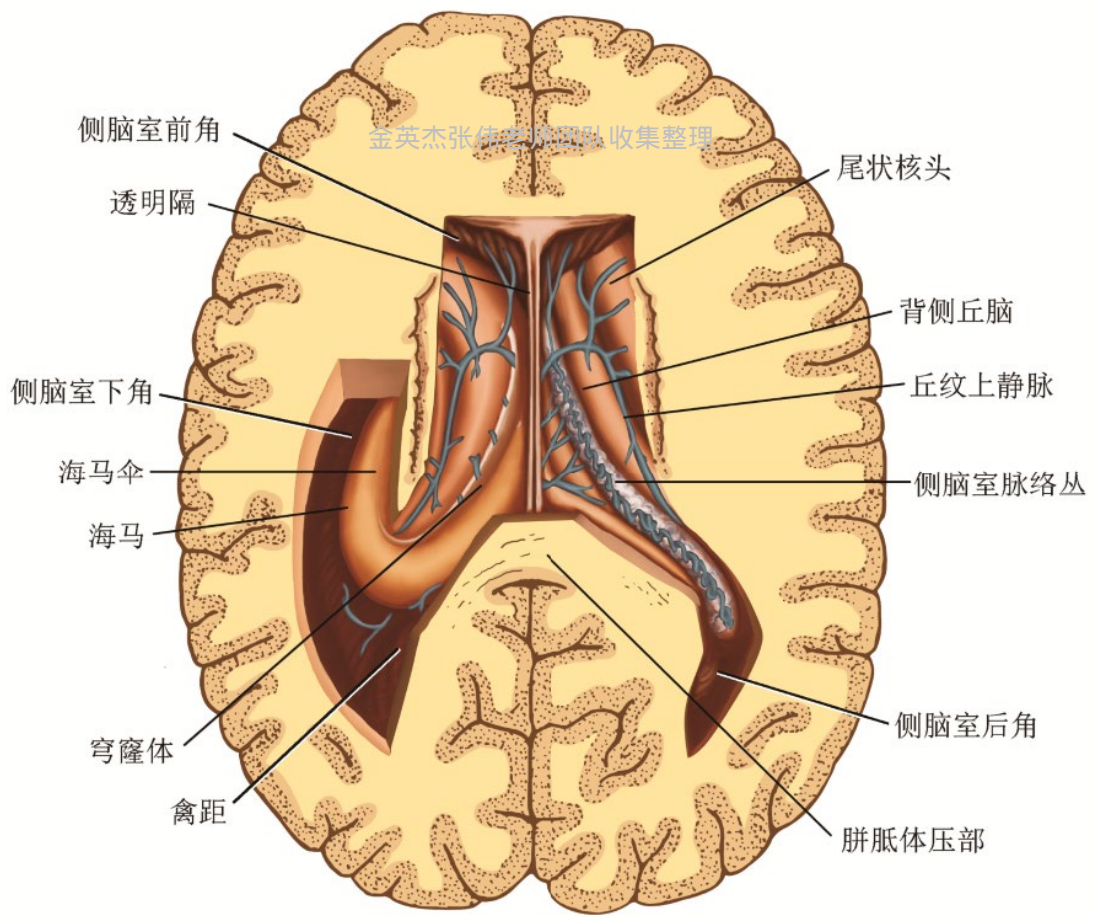
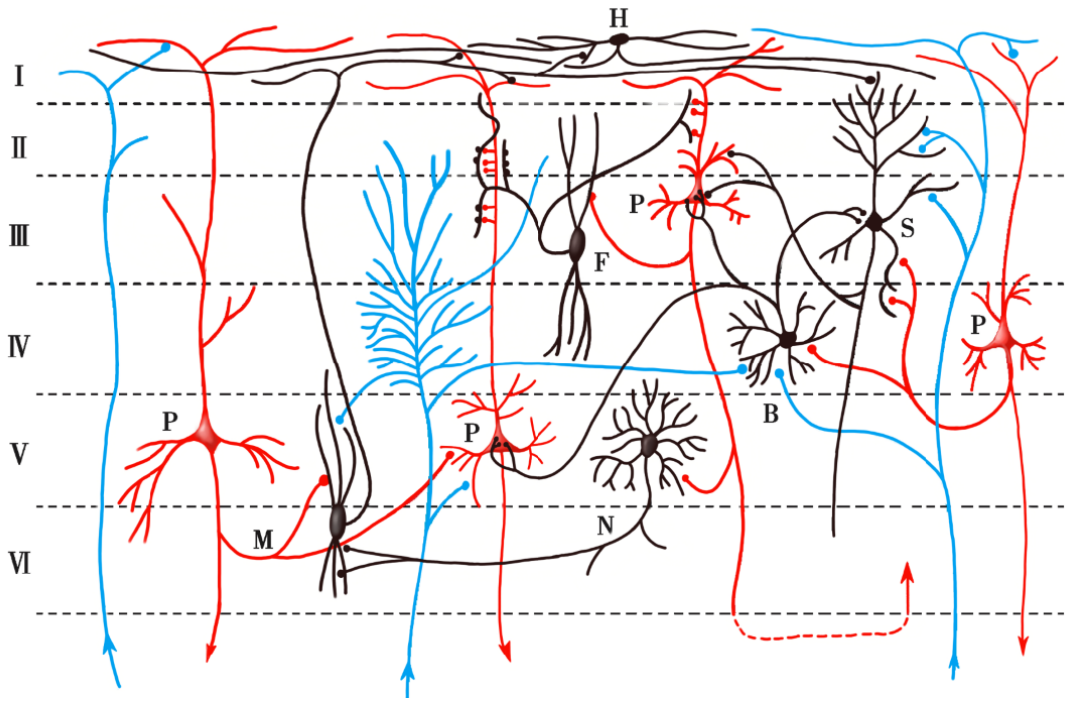


金英杰张伟老师团队收集整理



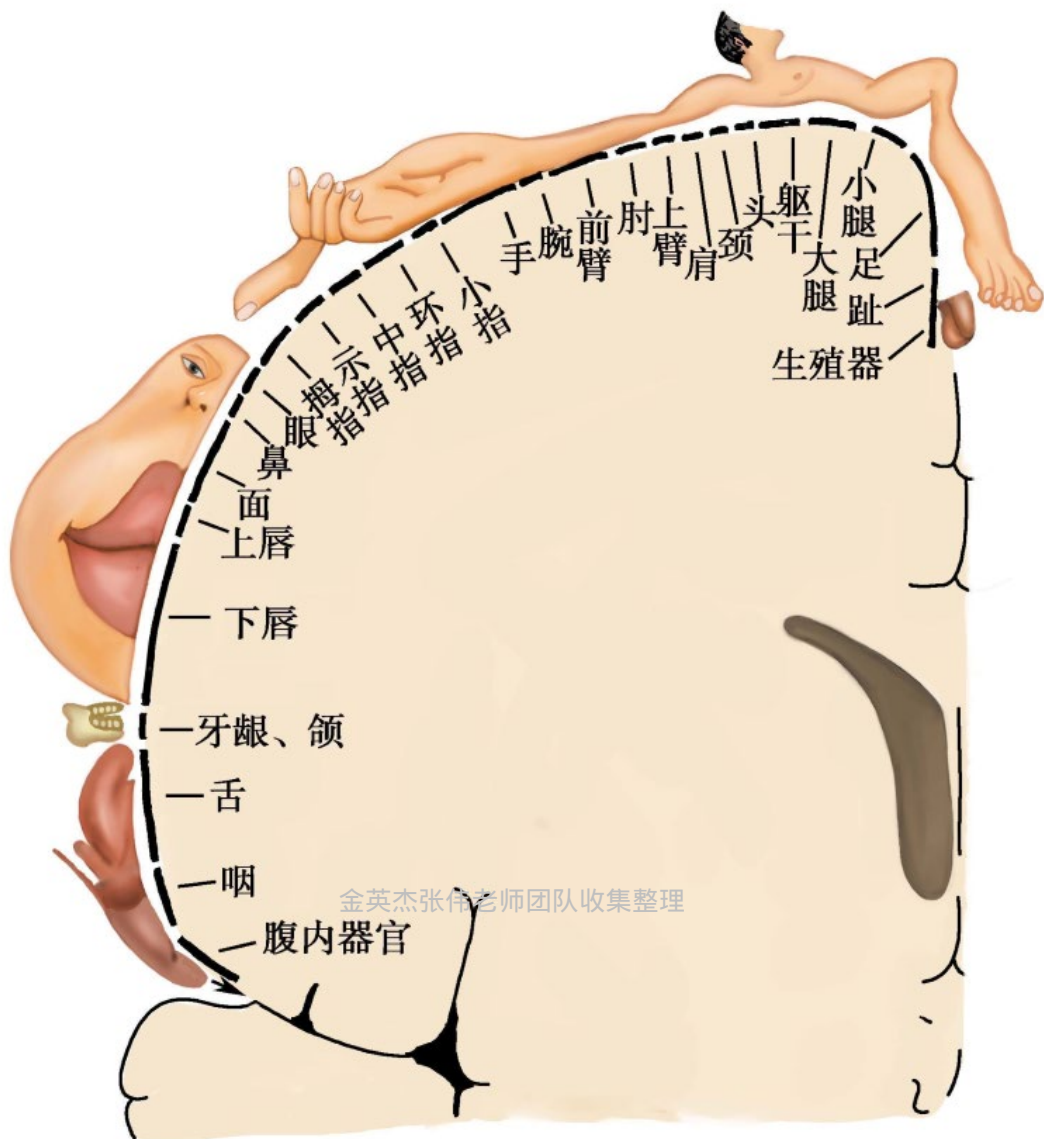
获取更多医考资料请关注





获取更多医考资料请关注





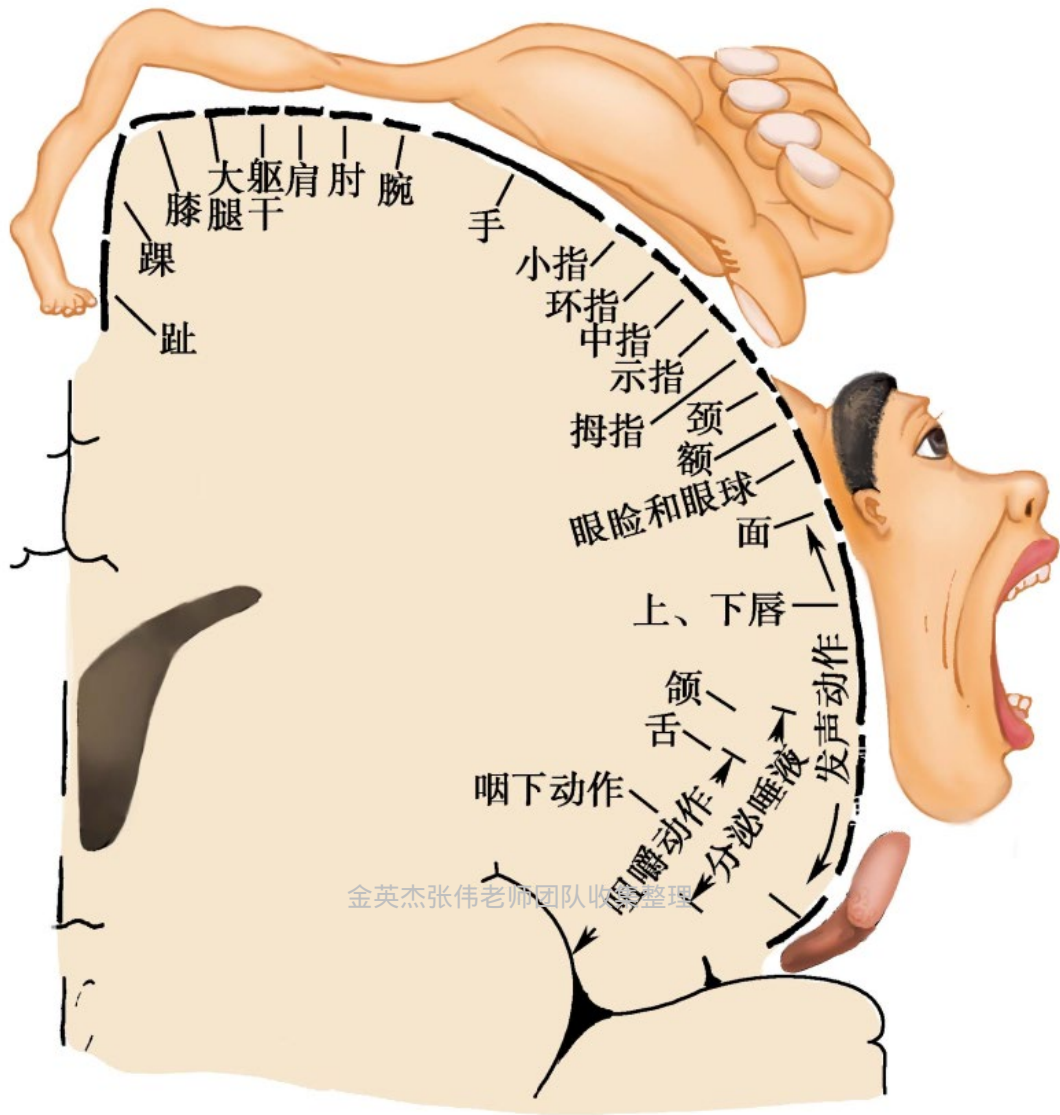
金英杰张仲老师团队收集整理



金英杰张仲老师

获取更多医考资料请关注





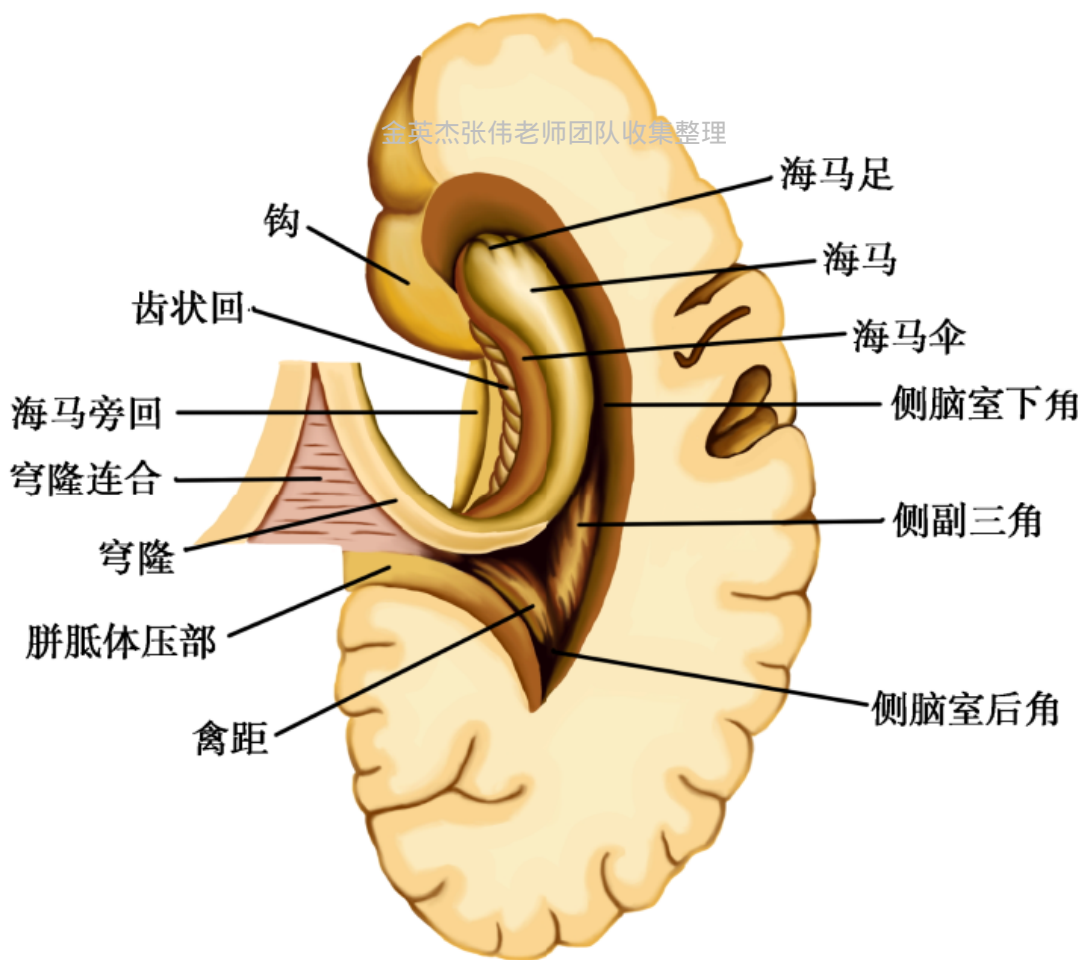
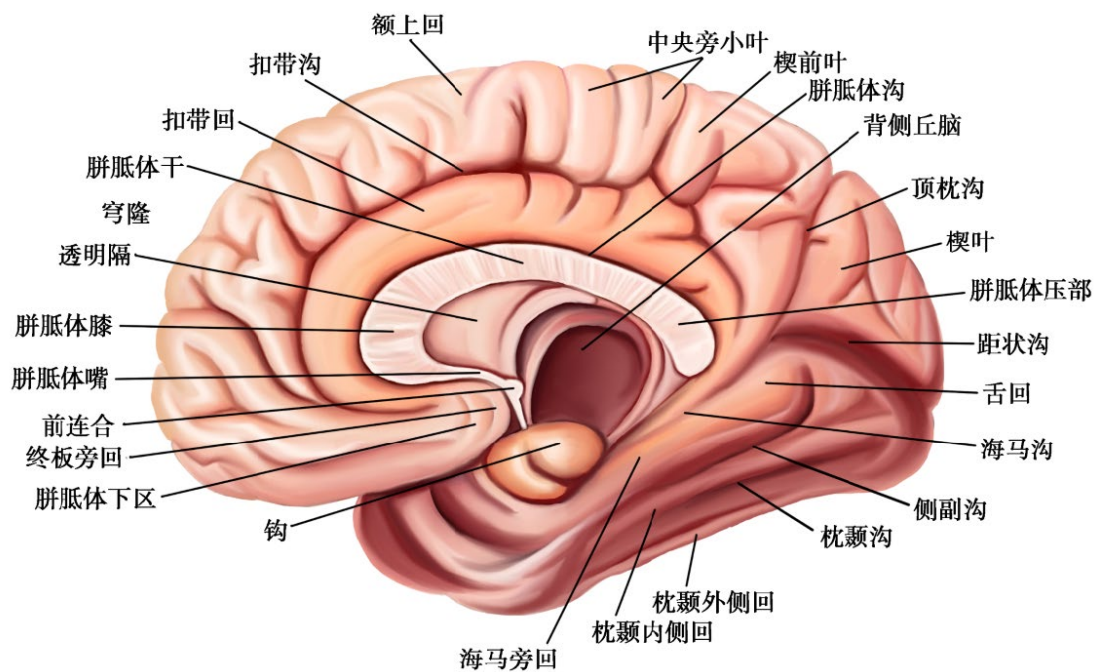
金英杰张伟老师团队收集整理



金英杰张伟老师

获取更多医考资料请关注

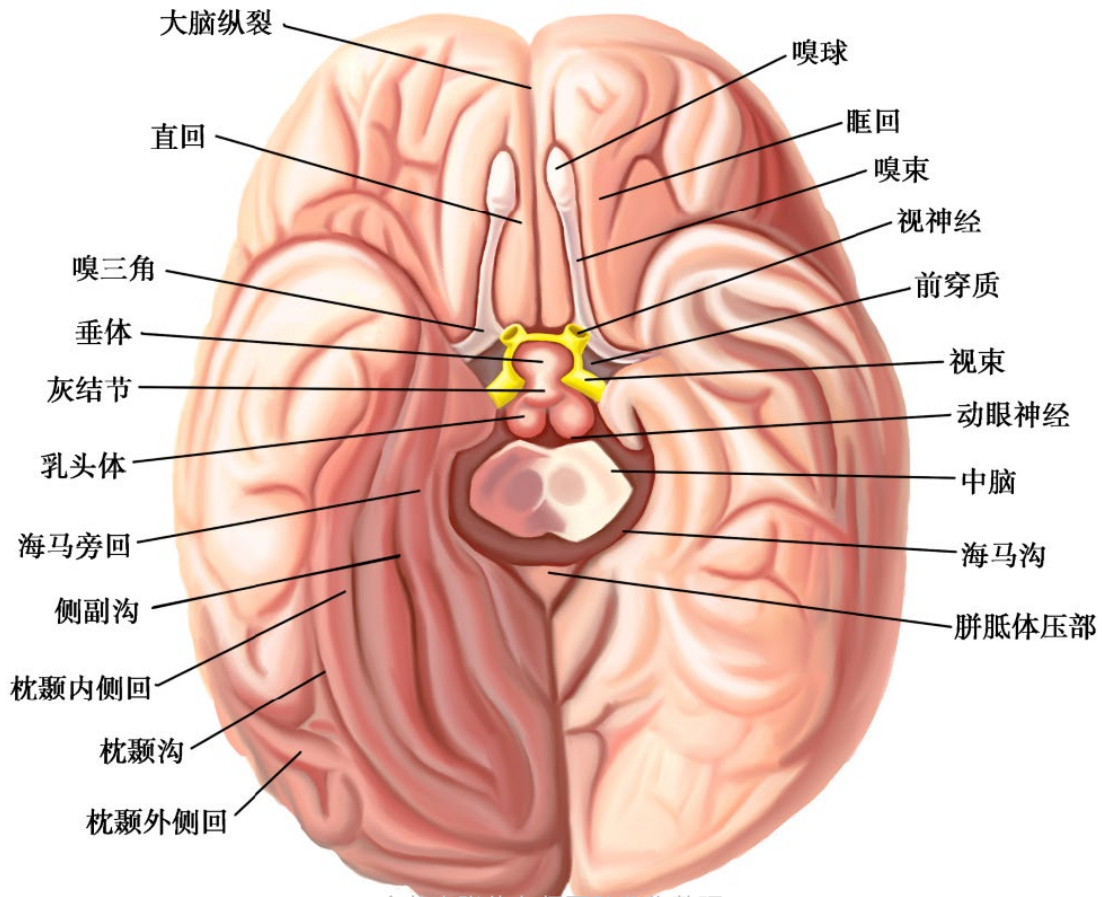




金英杰张伟老师

获取更多医考资料请关注

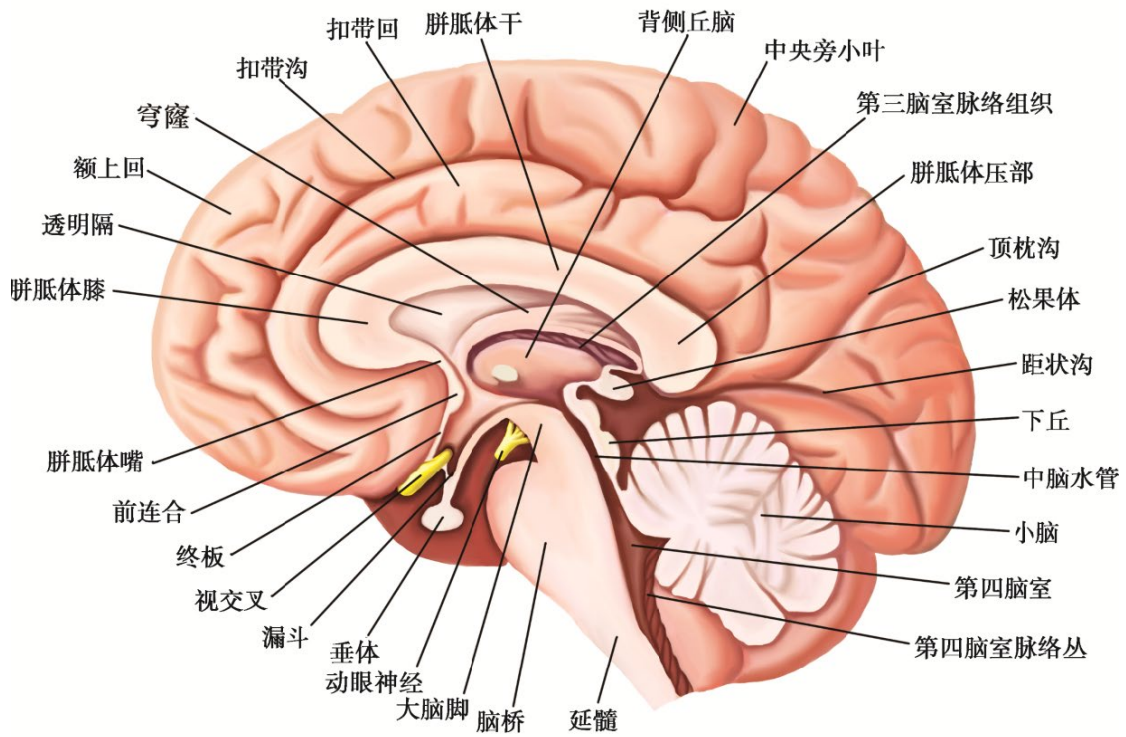




金英杰张伟老师团队收集整理

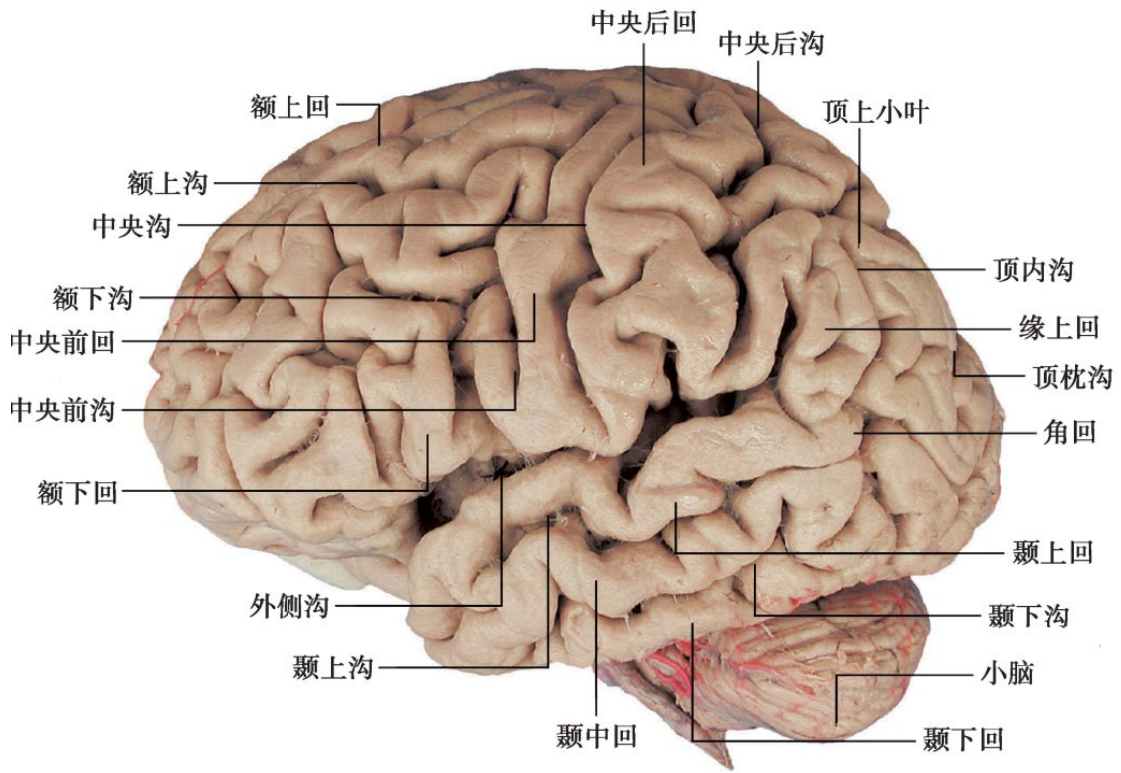


金英杰张伟老师

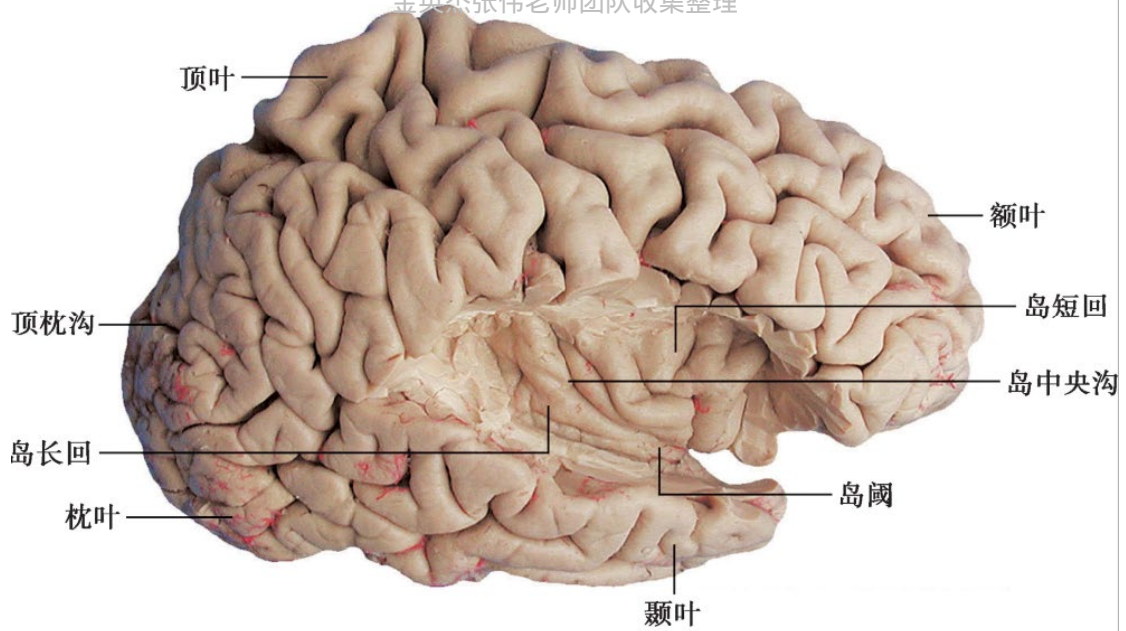


获取更多医考资料请关注





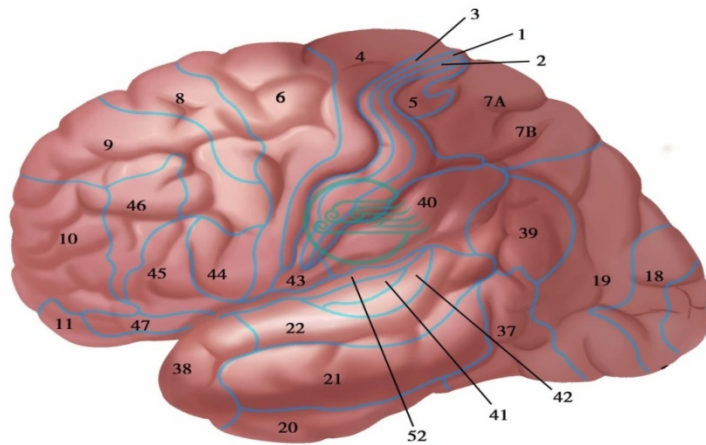
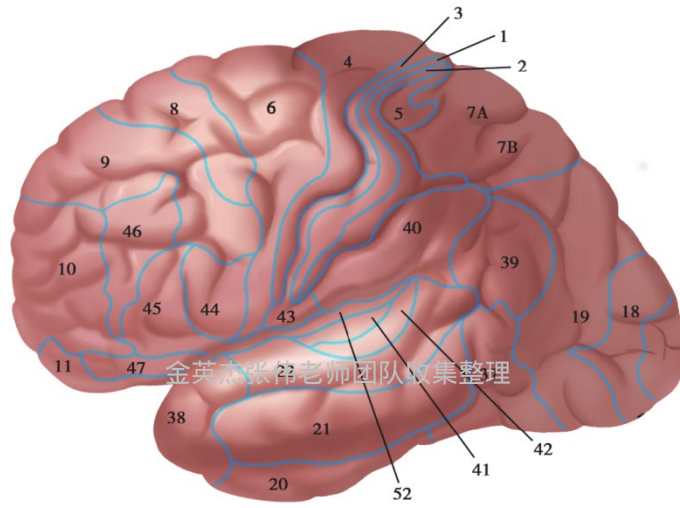
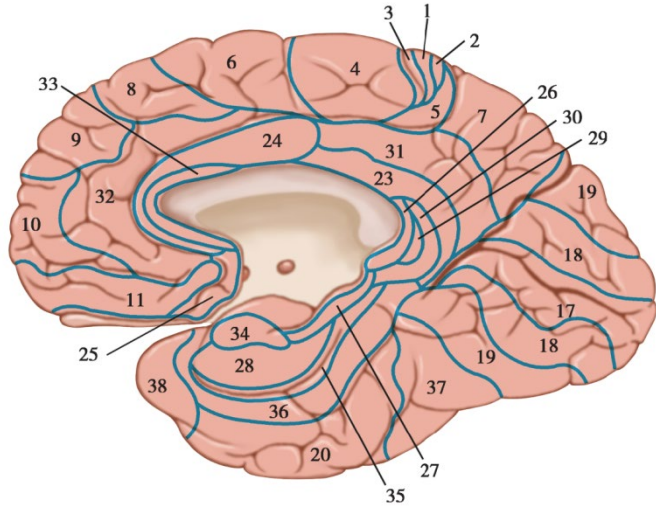
金英杰张伟老师团队收集整理



金英杰张伟老师

获取更多医考资料请关注



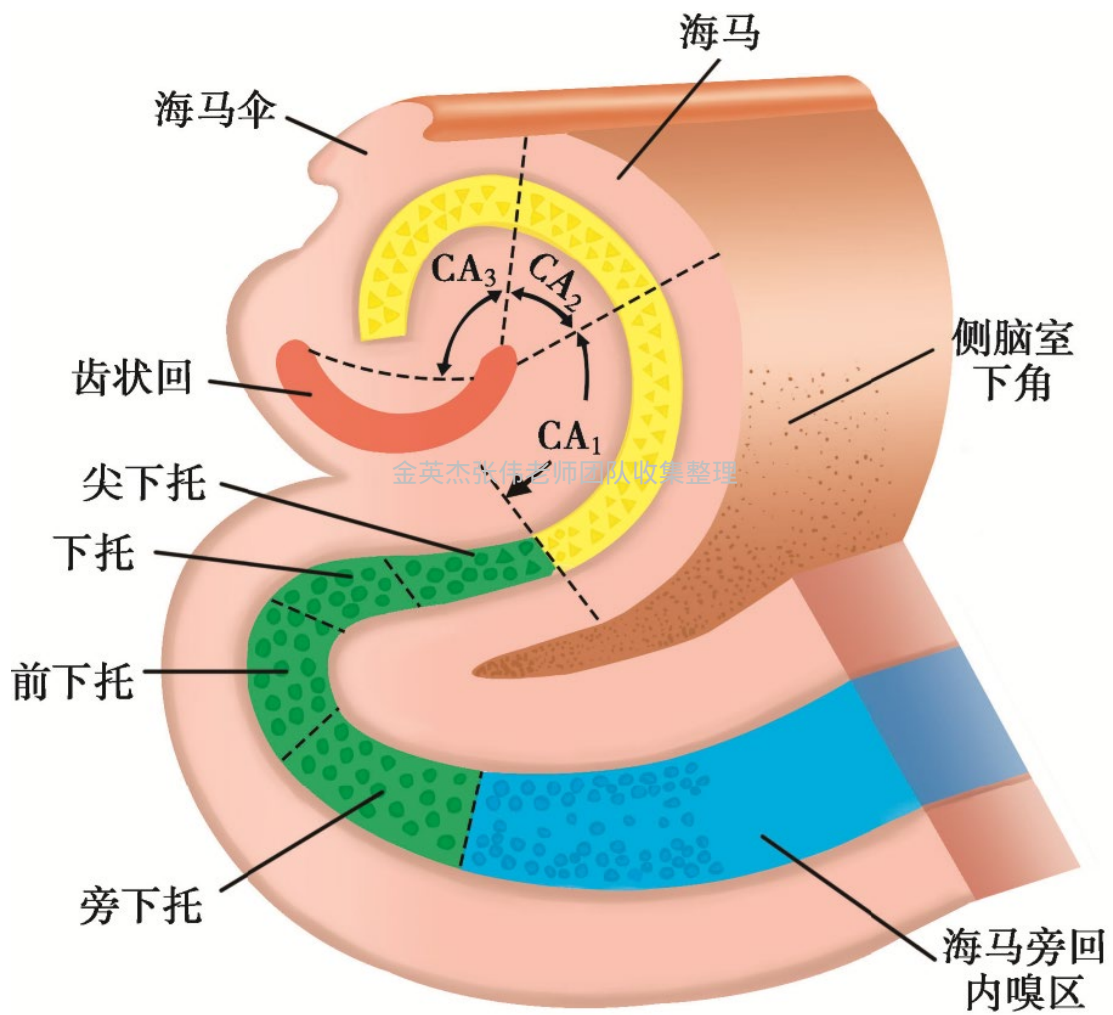
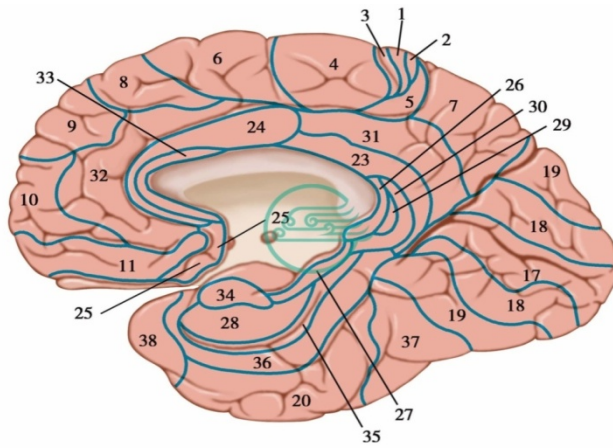


金英杰张浩老师团队收集整理



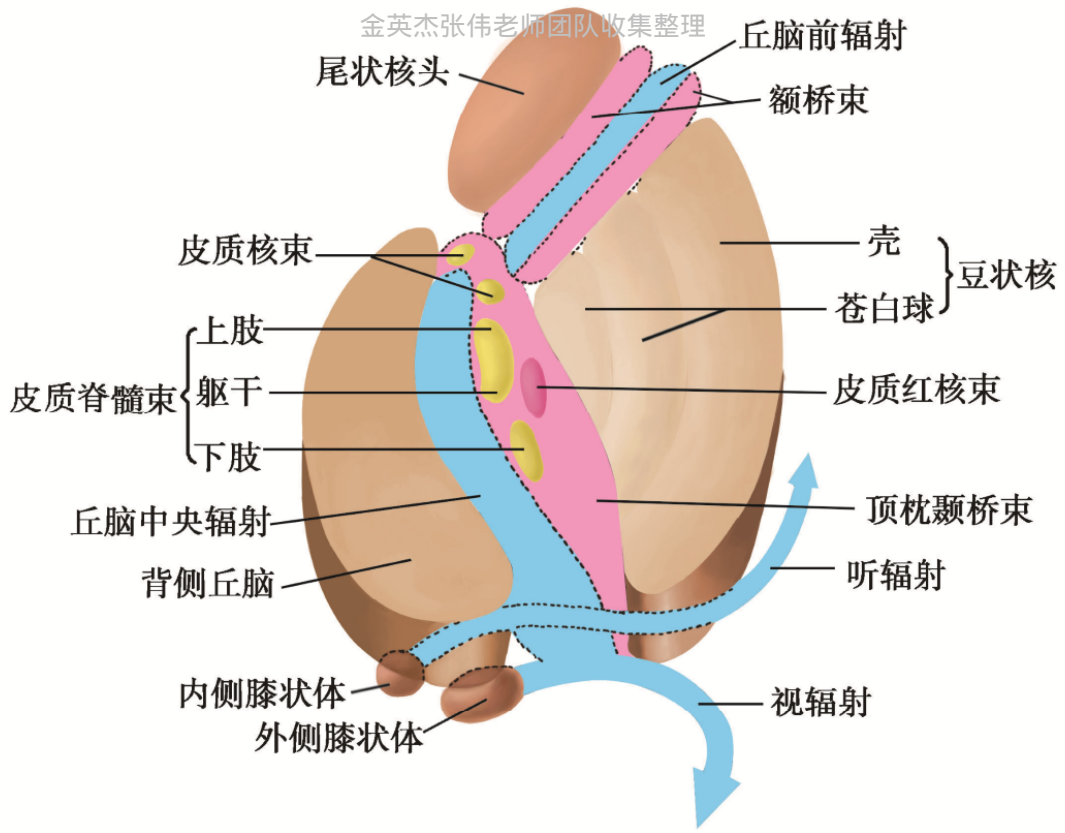
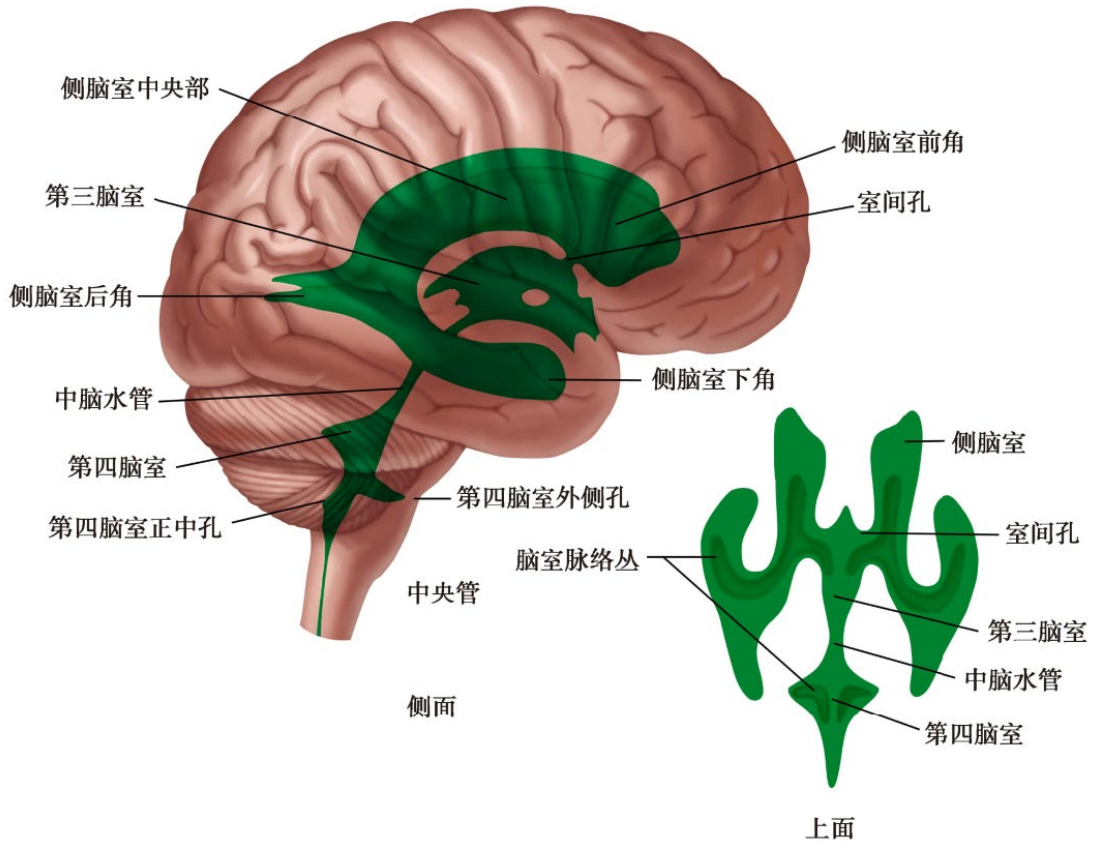
获取更多医考资料请关注





获取更多医考资料请关注

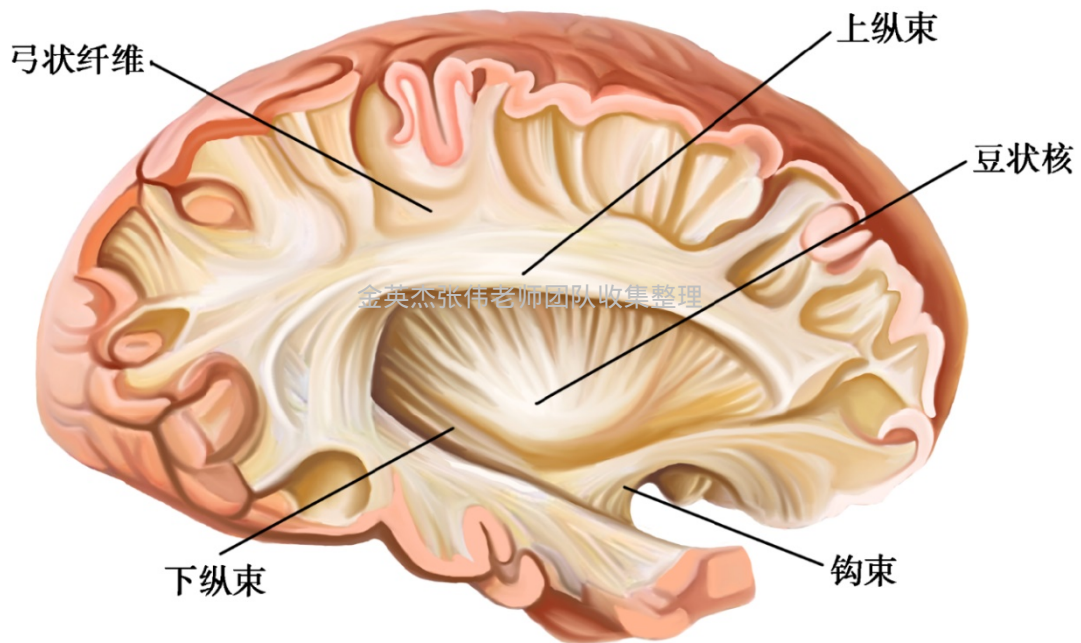
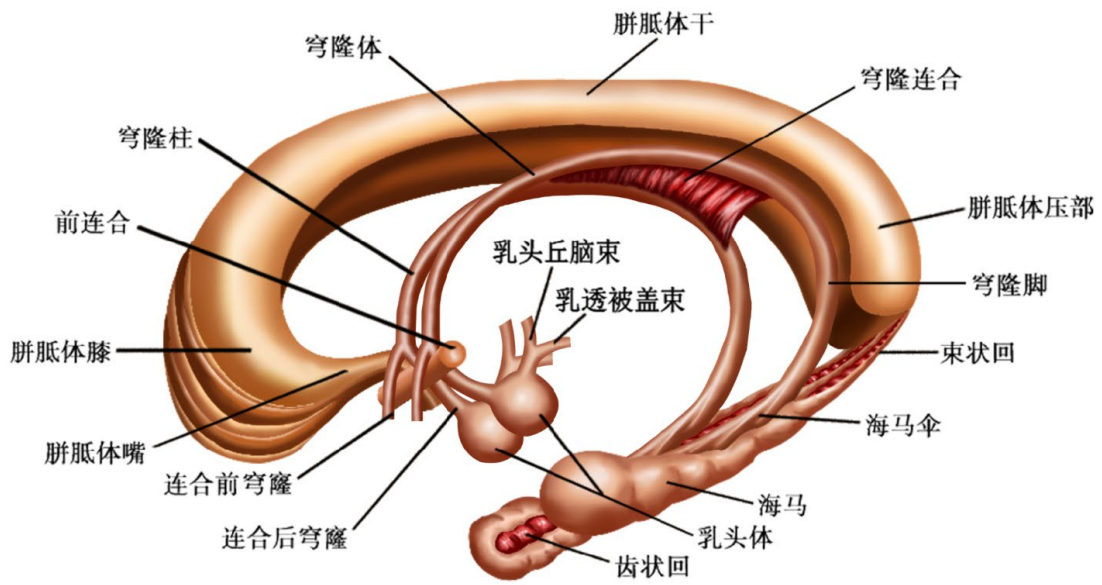




金英杰张伟老师

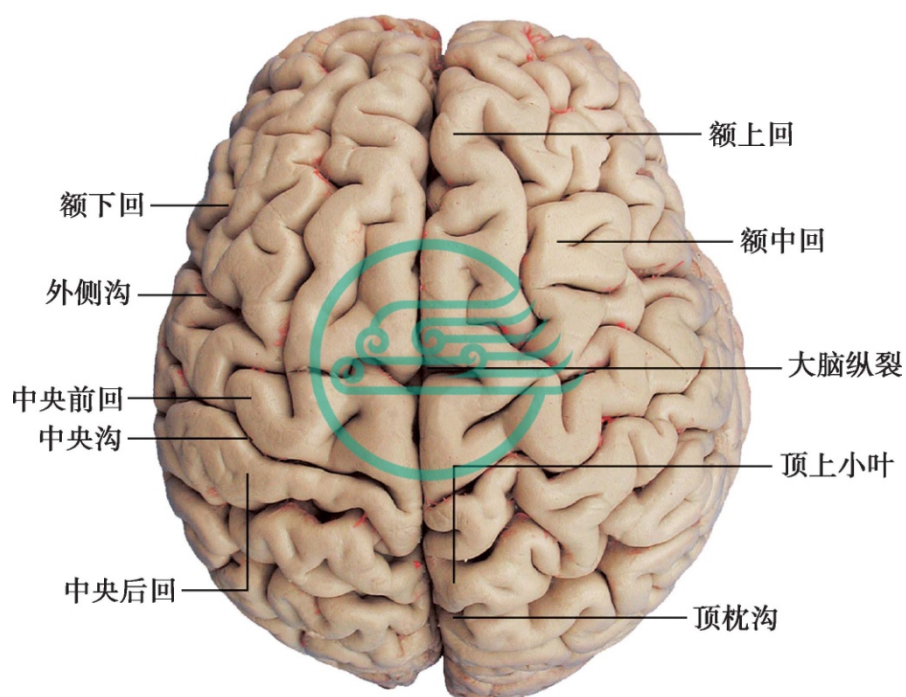
获取更多医考资料请关注





获取更多医考资料请关注



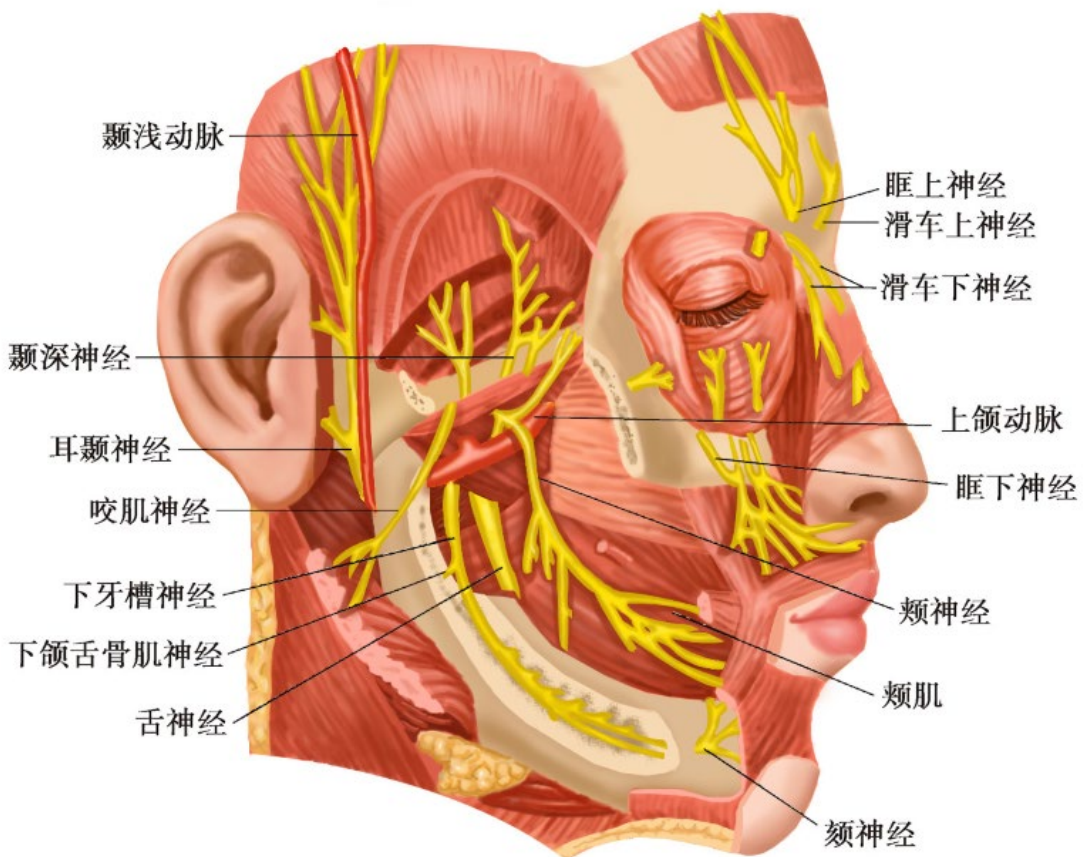
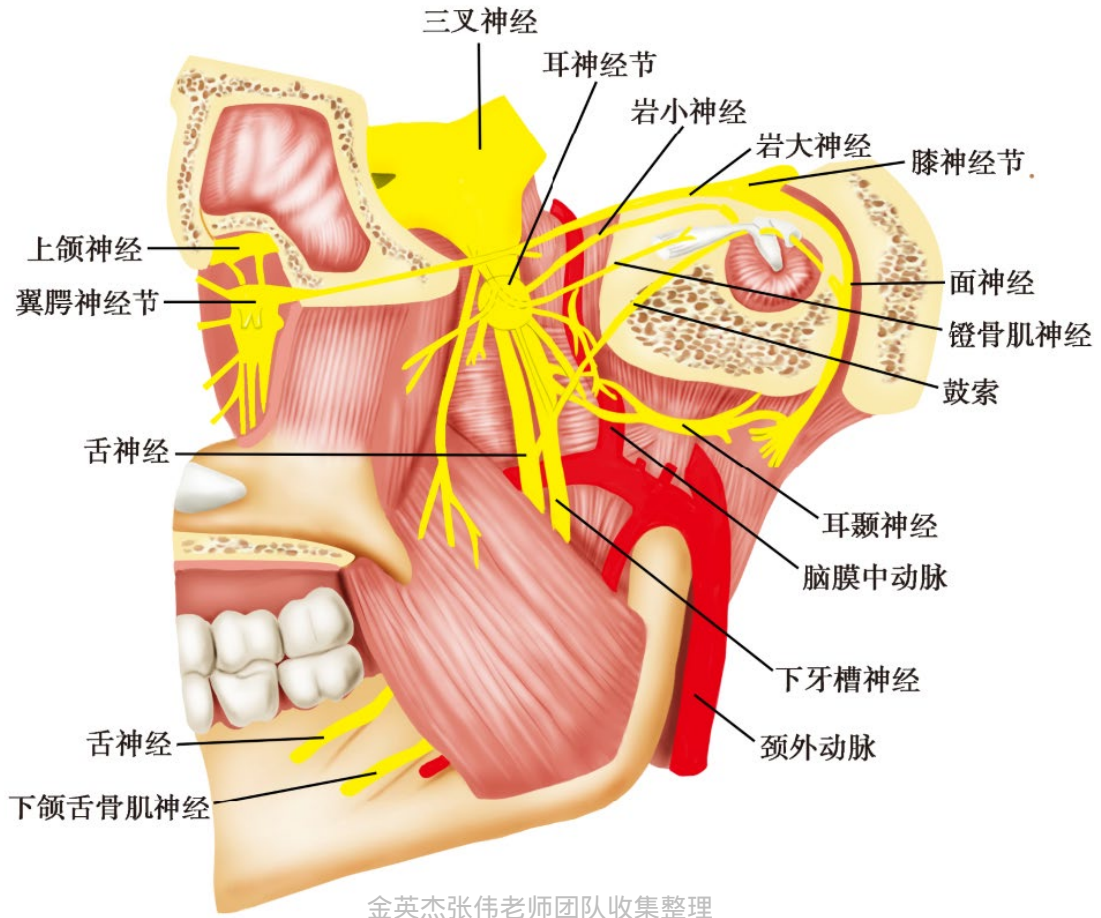


金英杰张伟老师团队收集整理



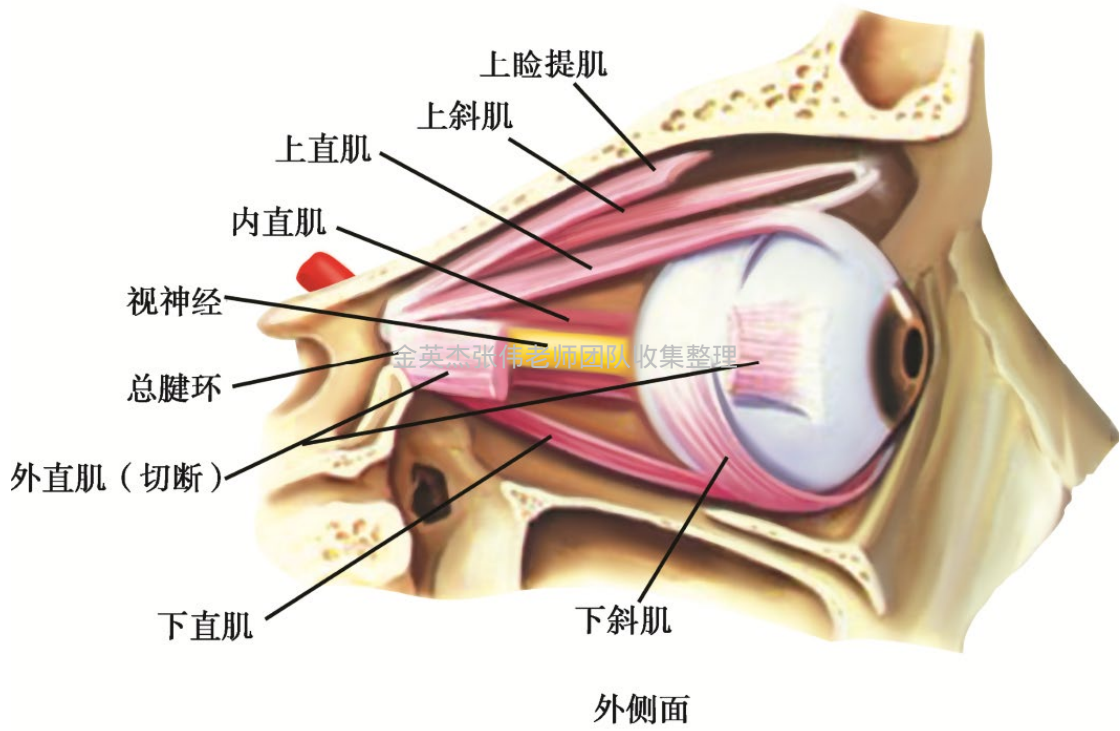
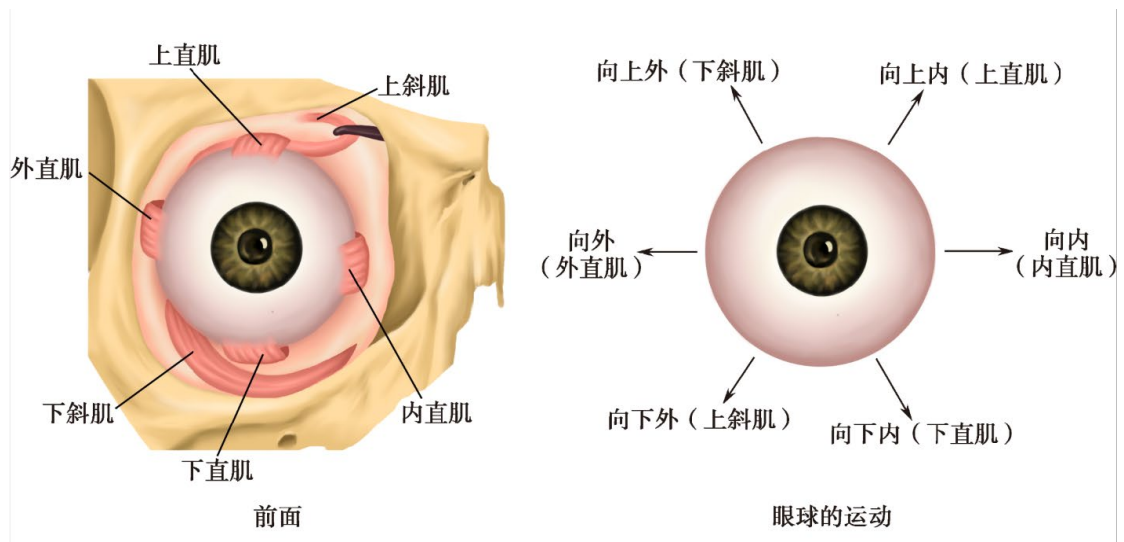
获取更多医考资料请关注





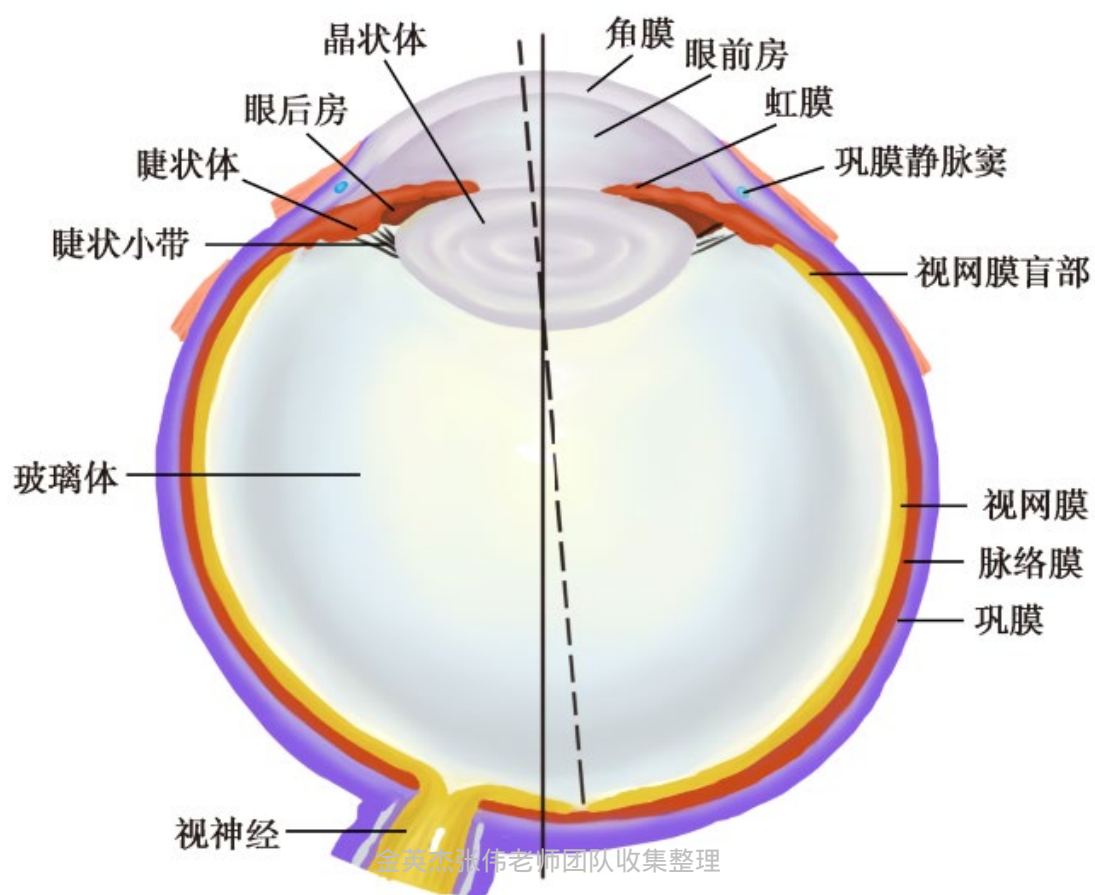
获取更多医考资料请关注





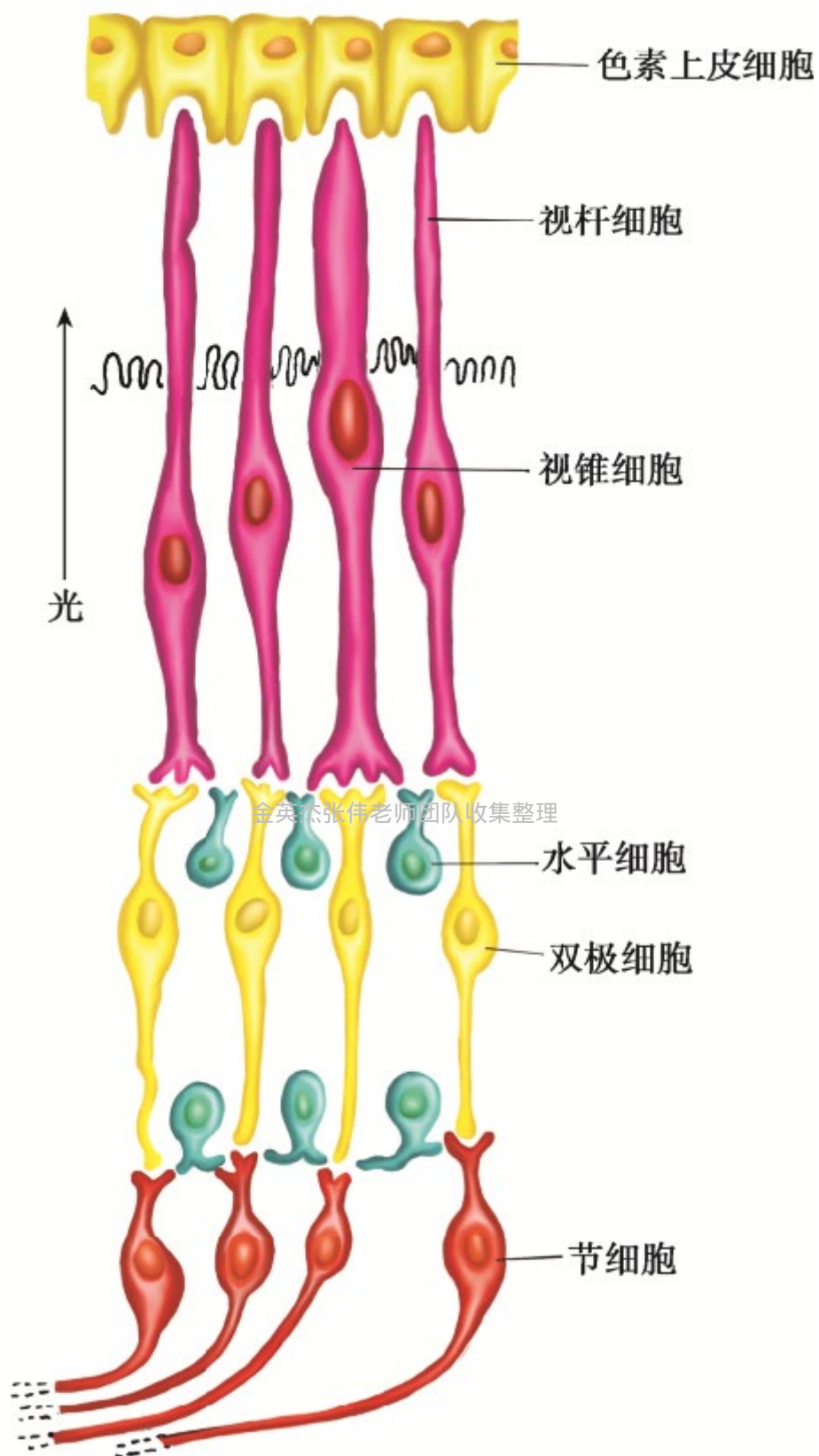
获取更多医考资料请关注





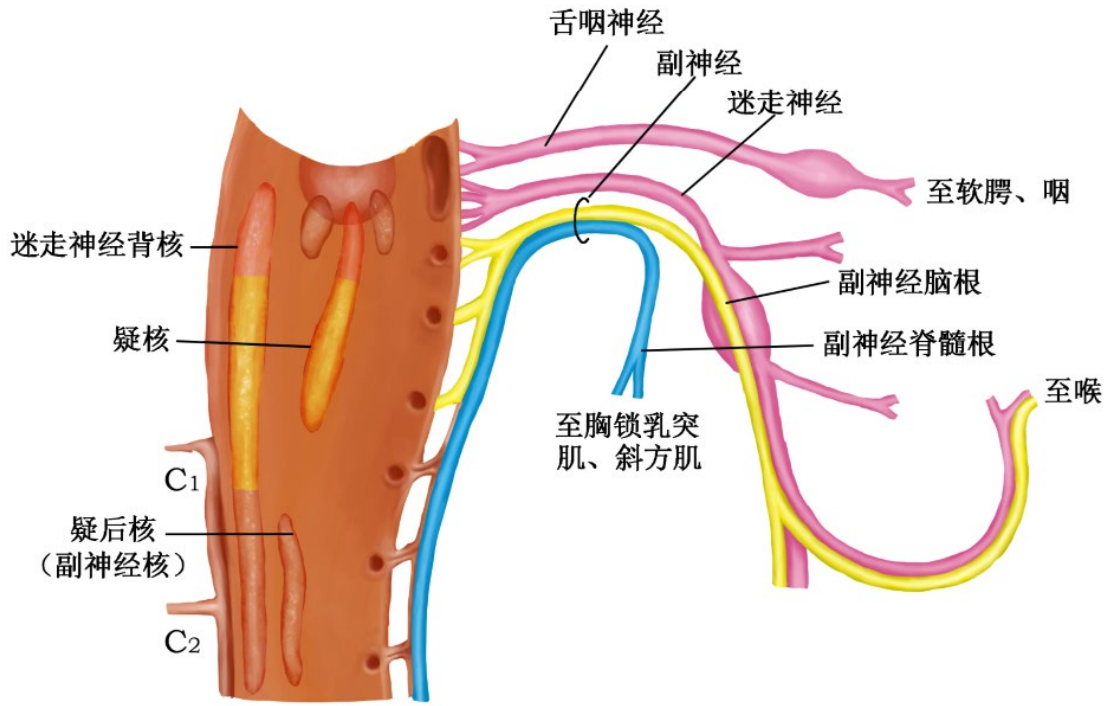
获取更多医考资料请关注





获取更多医考资料请关注





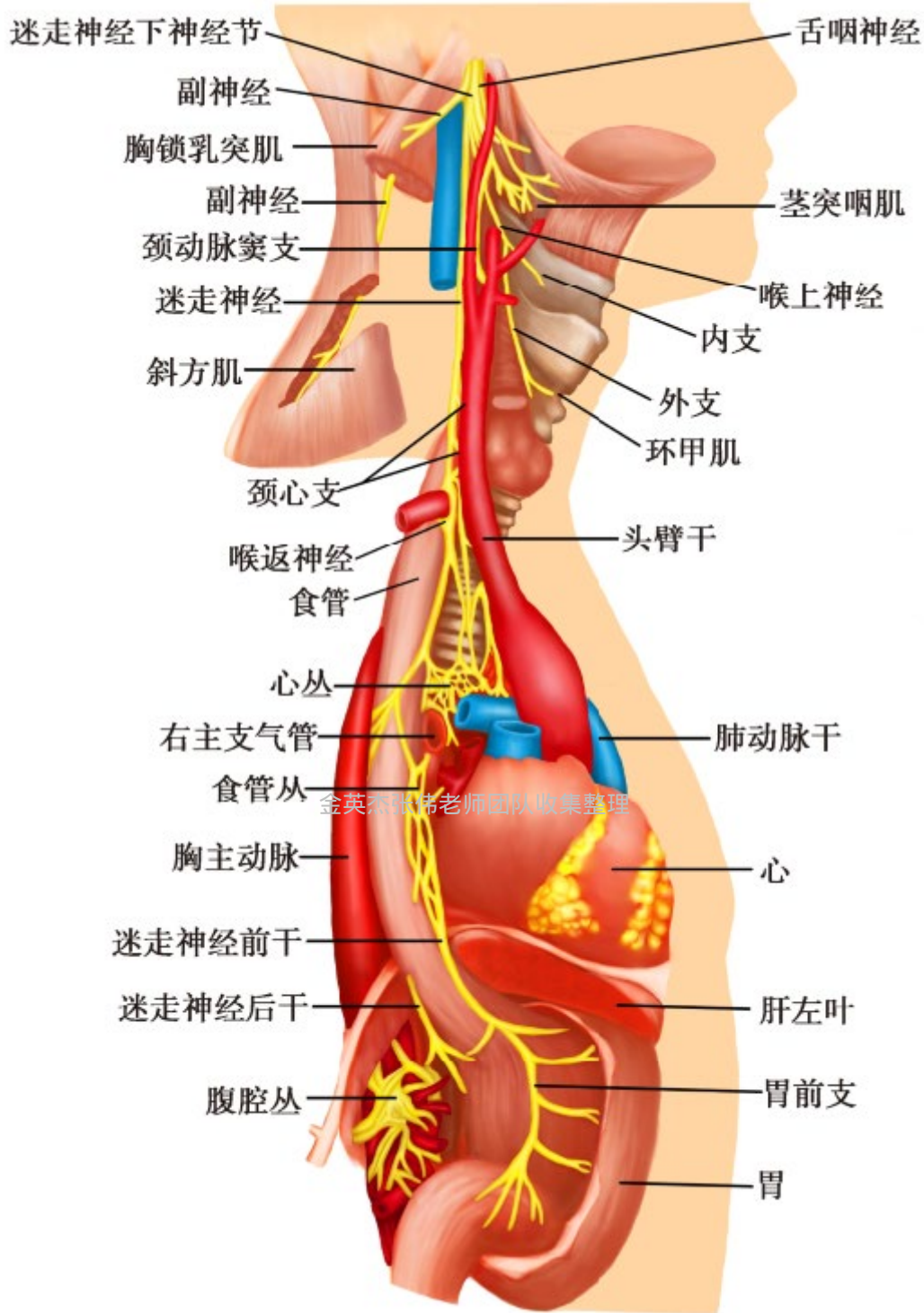
金英杰张伟老师团队收集整理



金英杰张伟老师

获取更多医考资料请关注





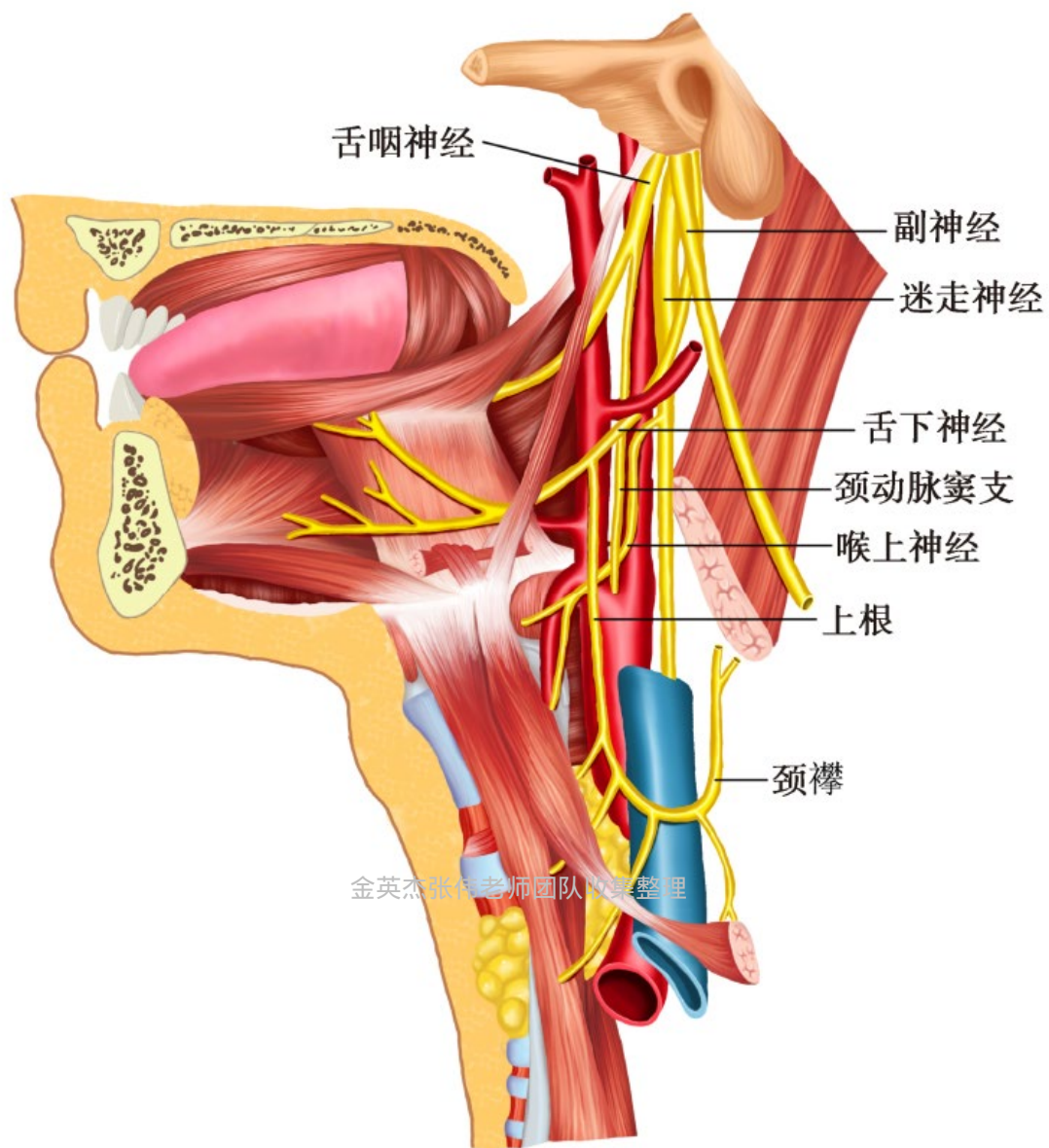
金英杰张伟老师团队收集整理



金英杰张伟老师

获取更多医考资料请关注





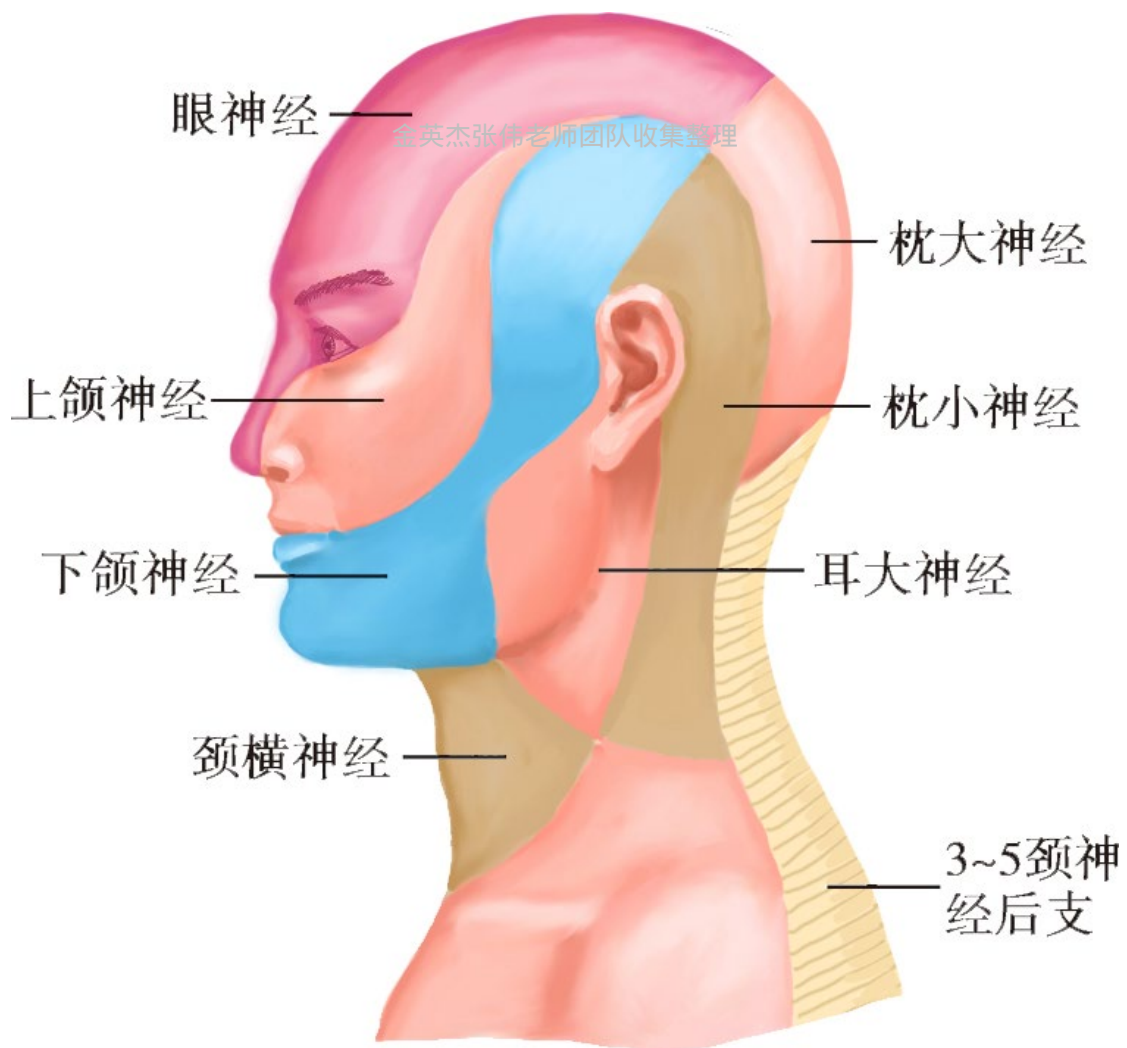
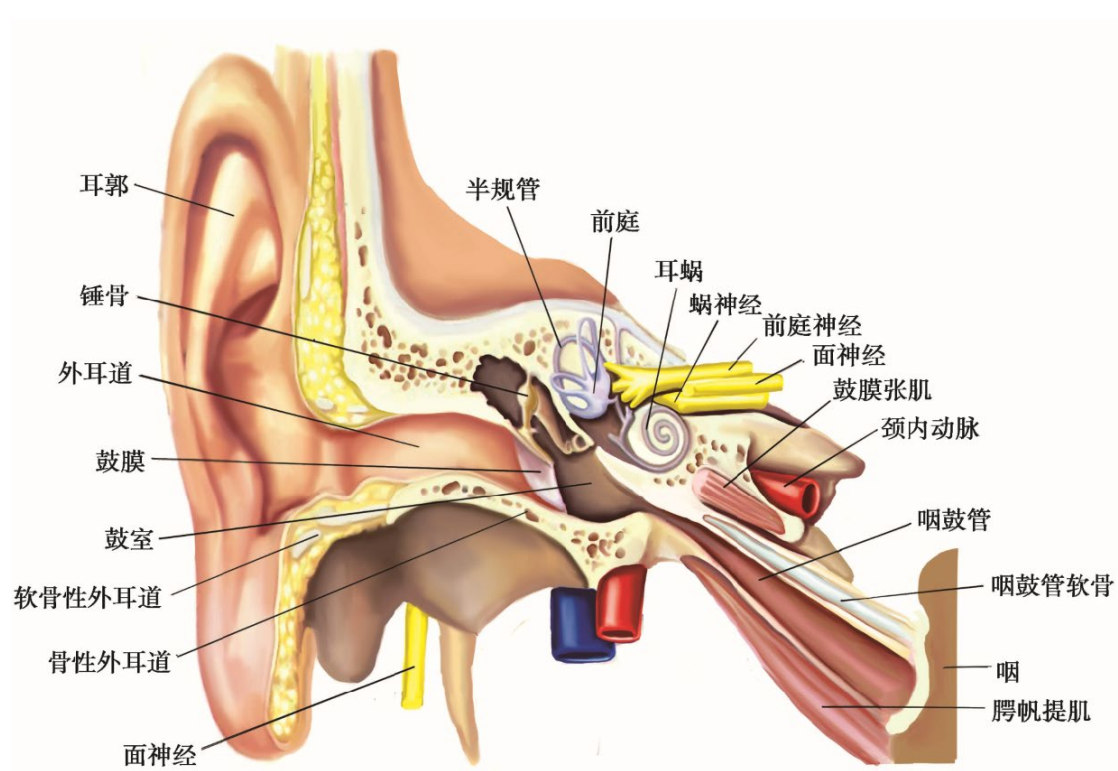
金英杰张伟老师团队课程整理



金英杰张伟老师

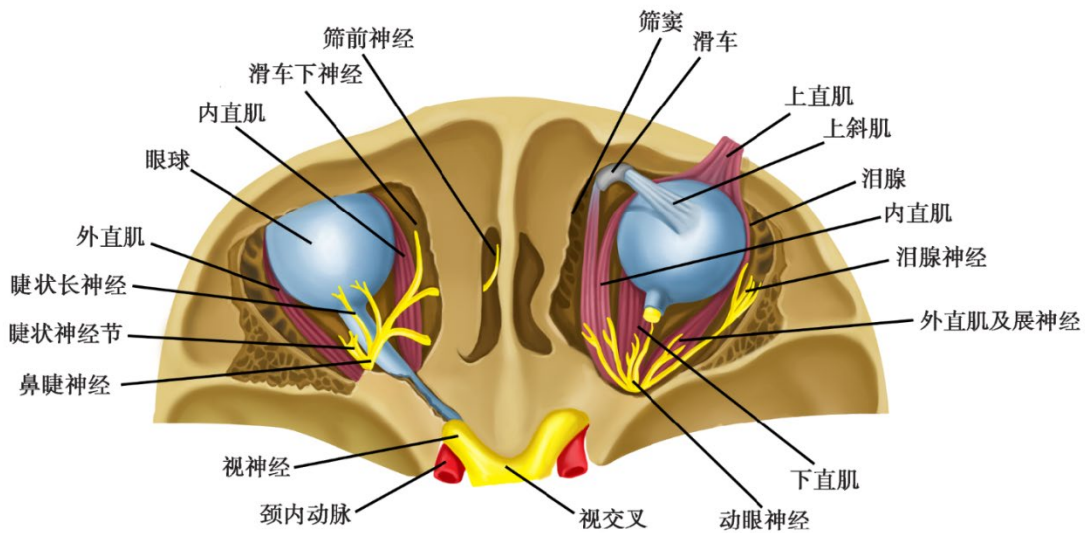
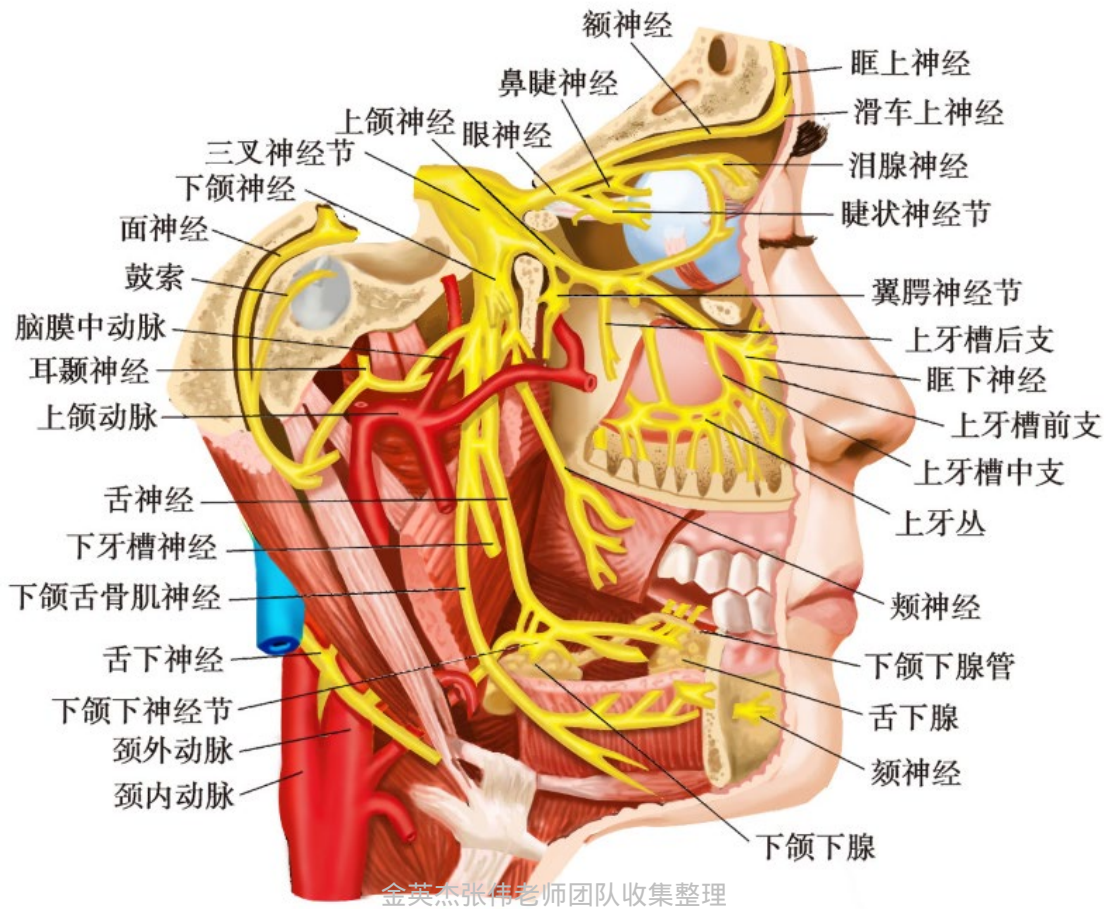


获取更多医考资料请关注



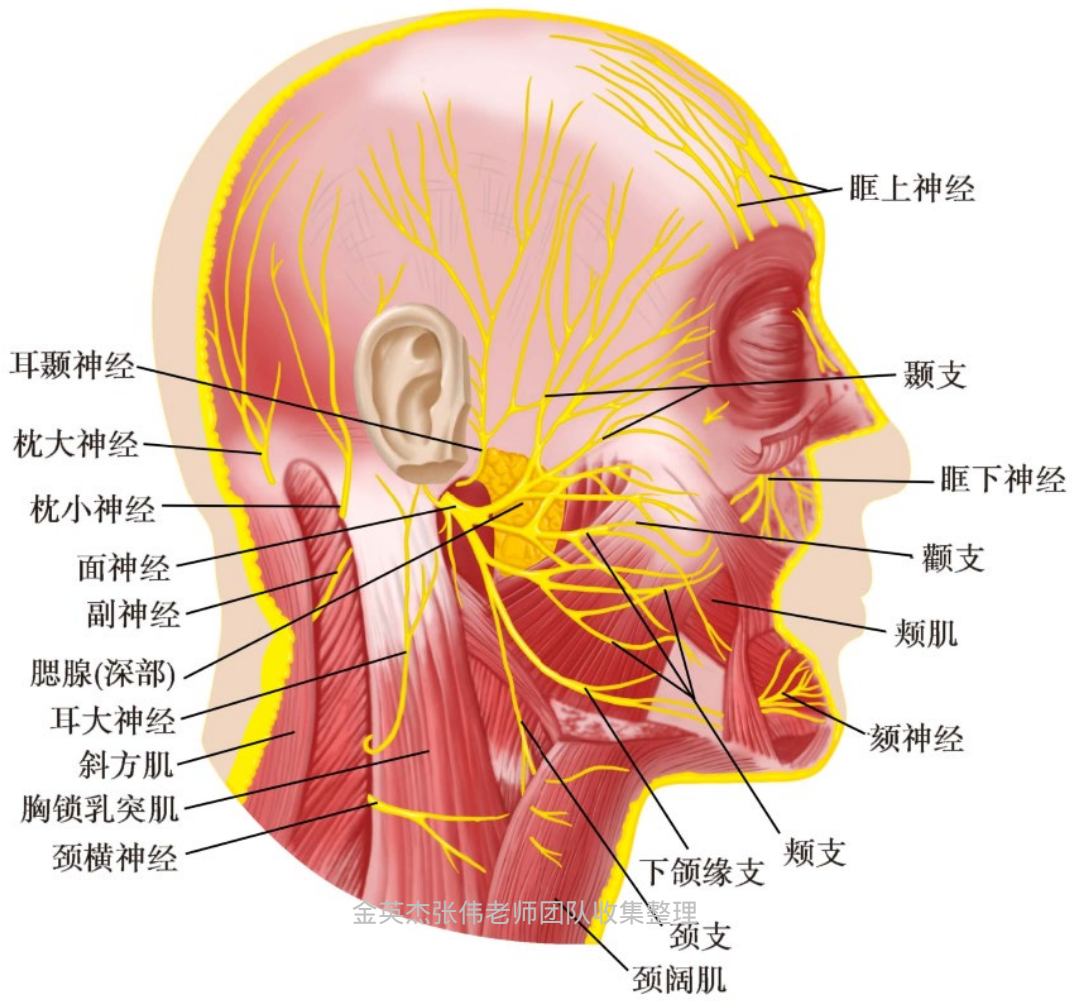
获取更多医考资料请关注





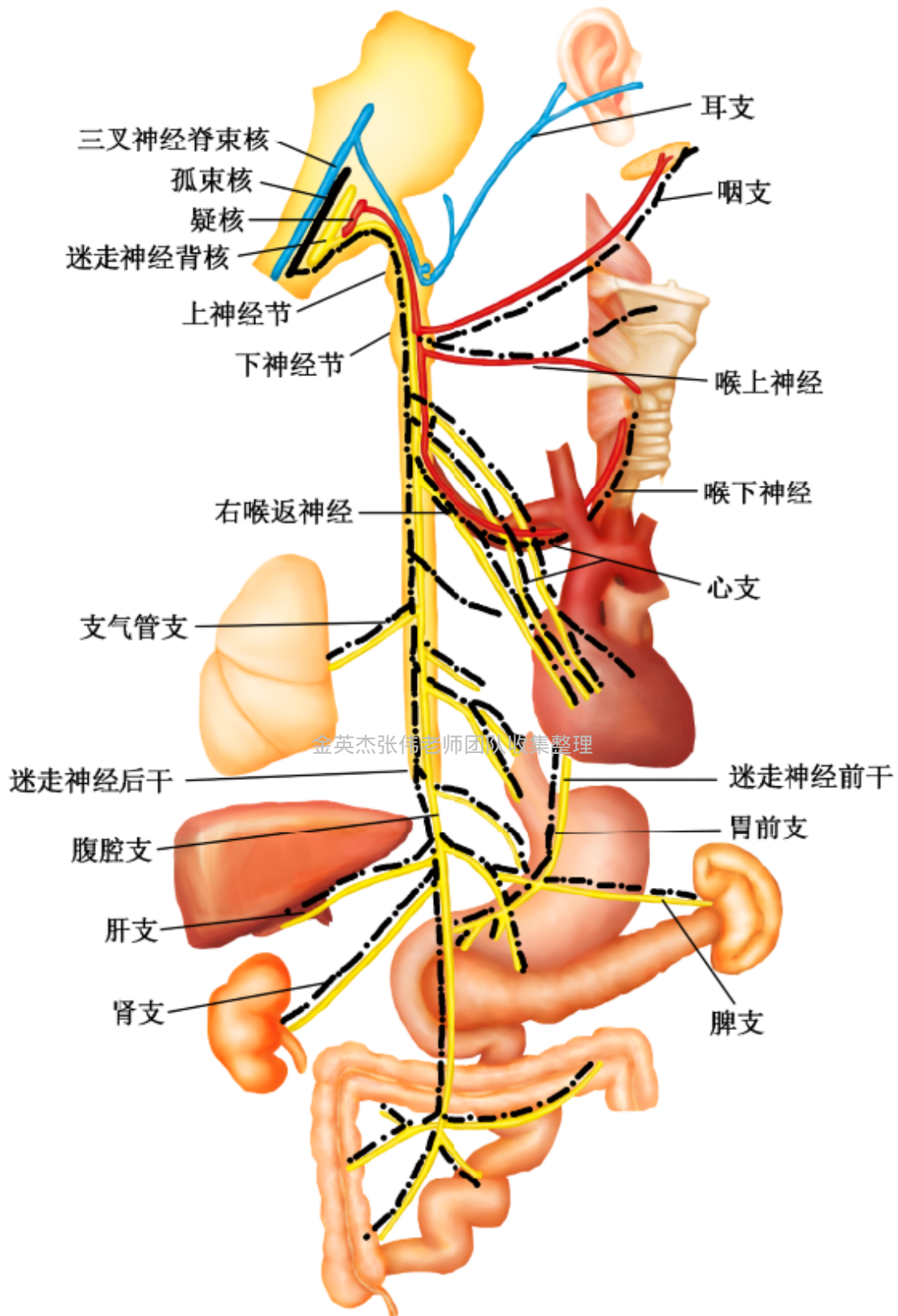
获取更多医考资料请关注





获取更多医考资料请关注

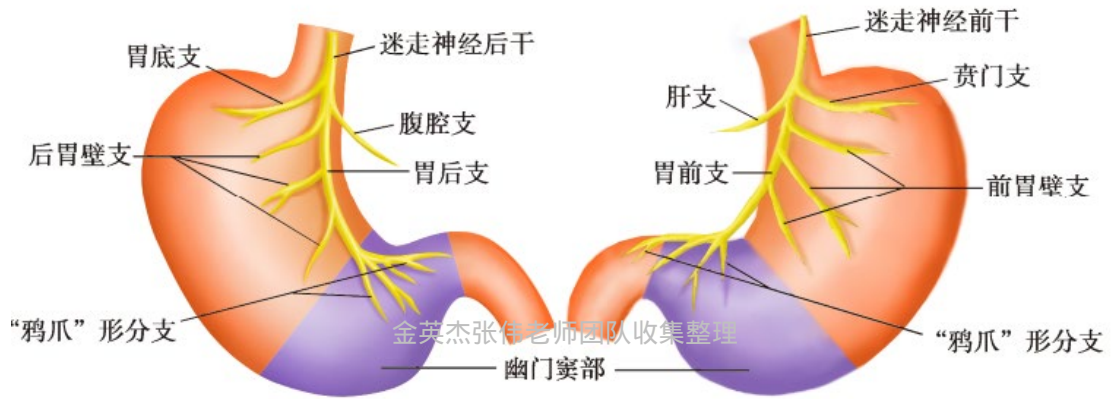
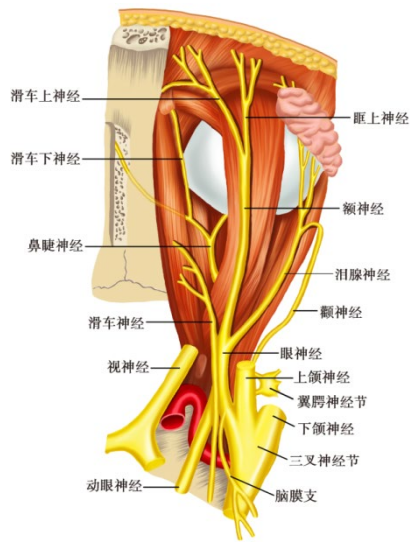




金英杰张伟老师

获取更多医考资料请关注

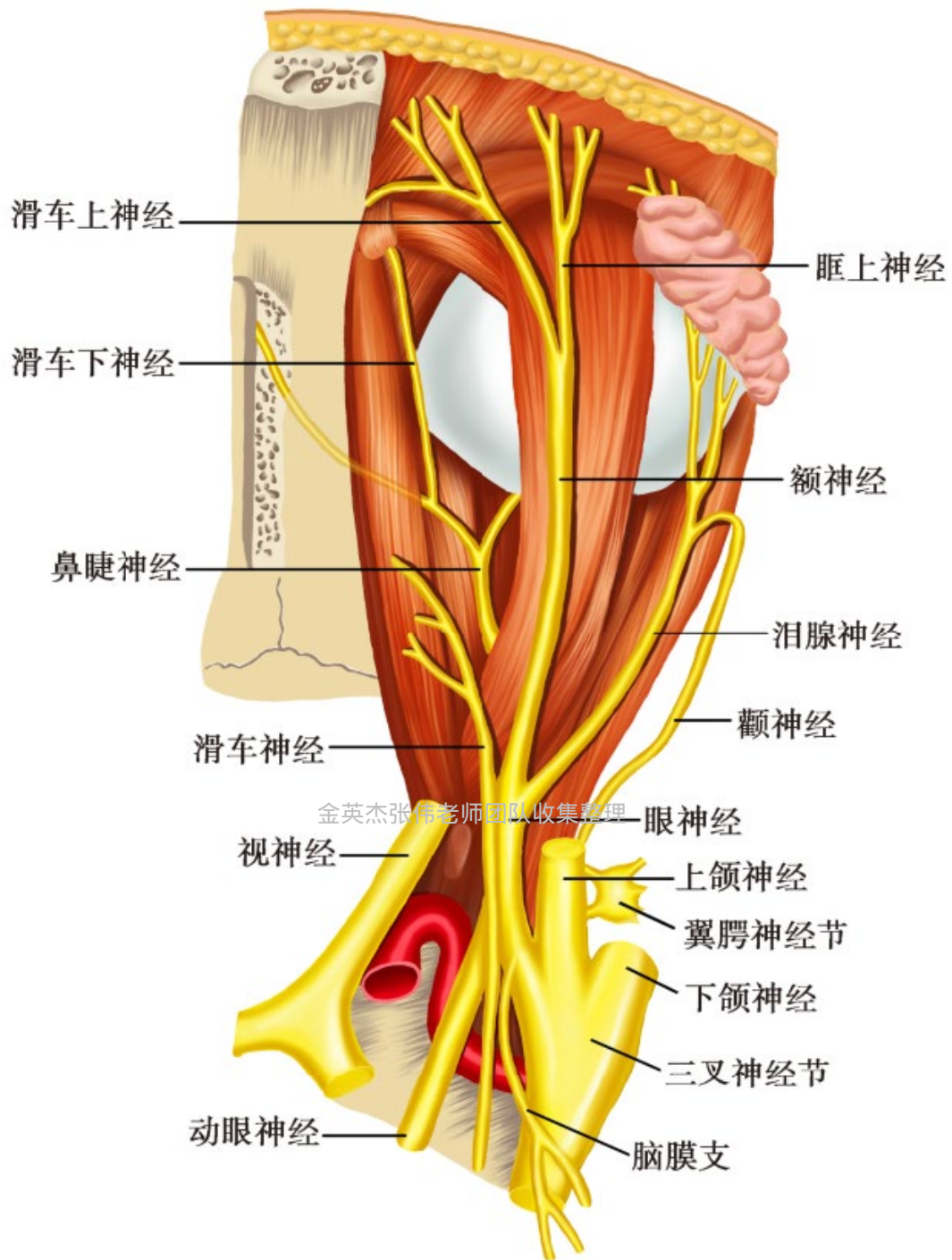




金英杰张佳老师

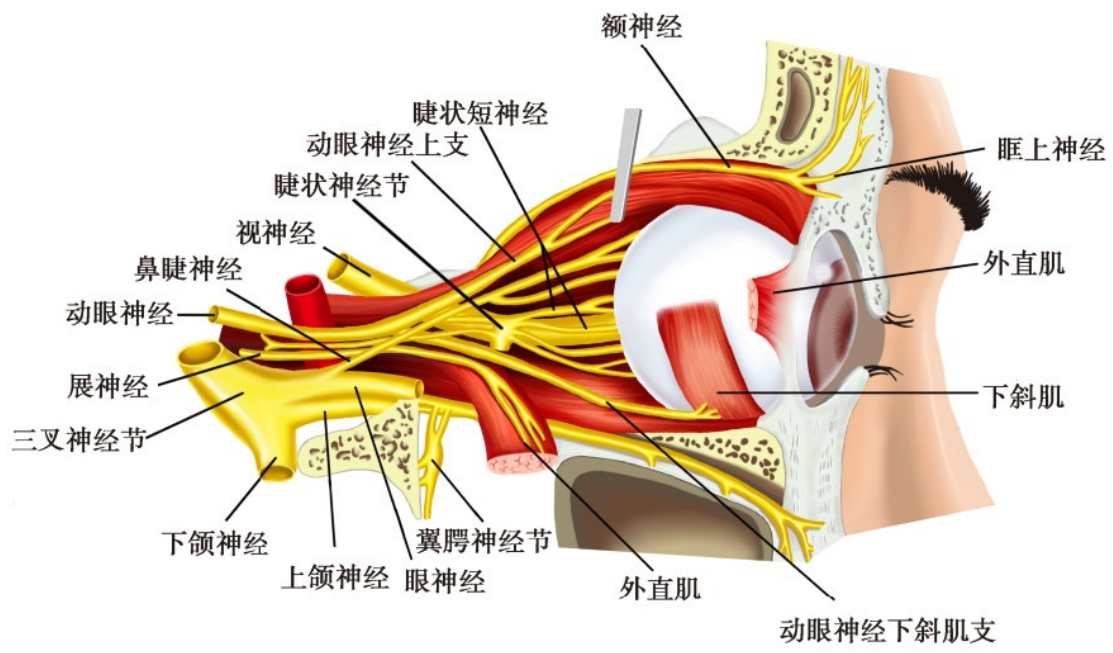
获取更多医考资料请关注





获取更多医考资料请关注





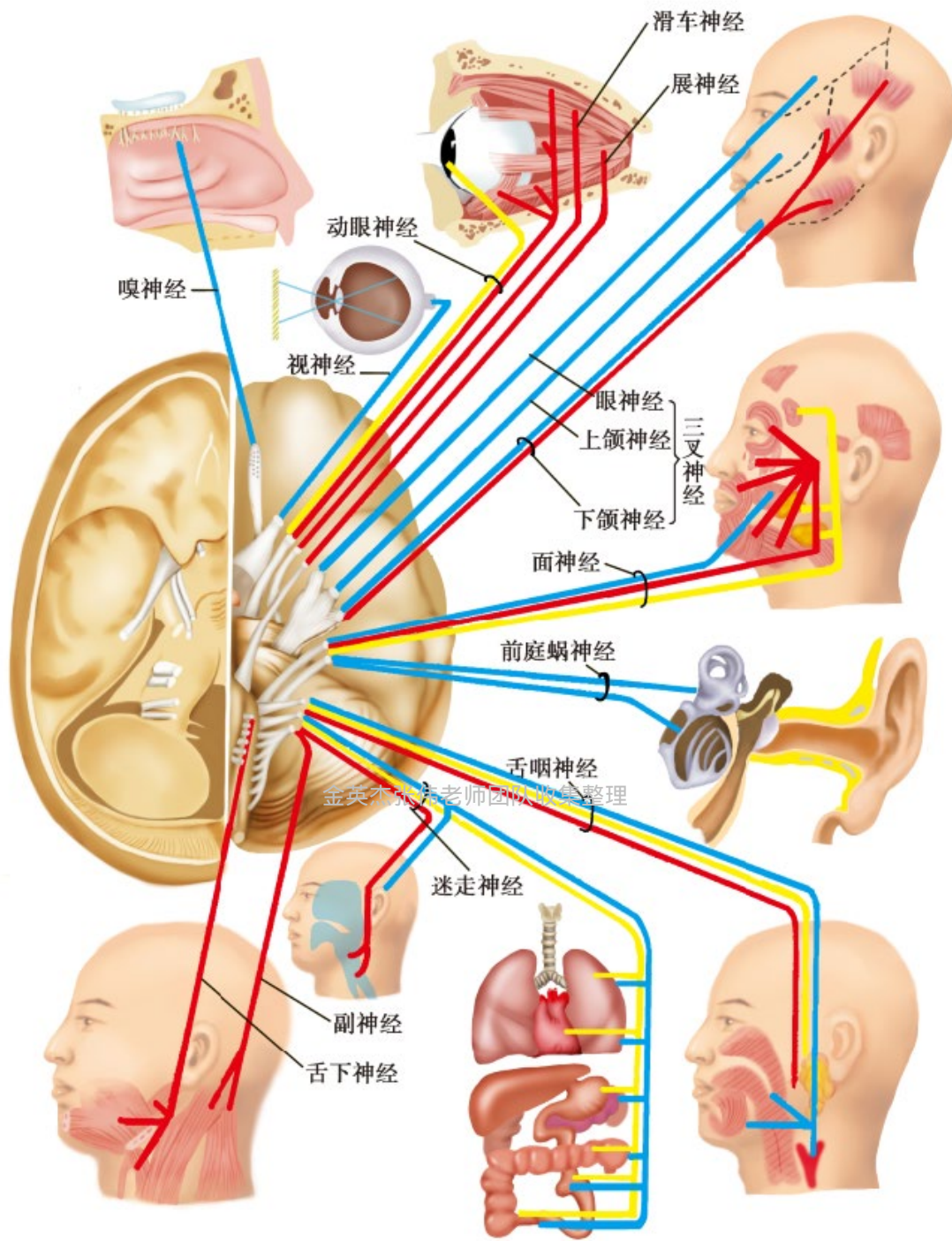
金英杰张伟老师团队收集整理



金英杰张伟老师

获取更多医考资料请关注





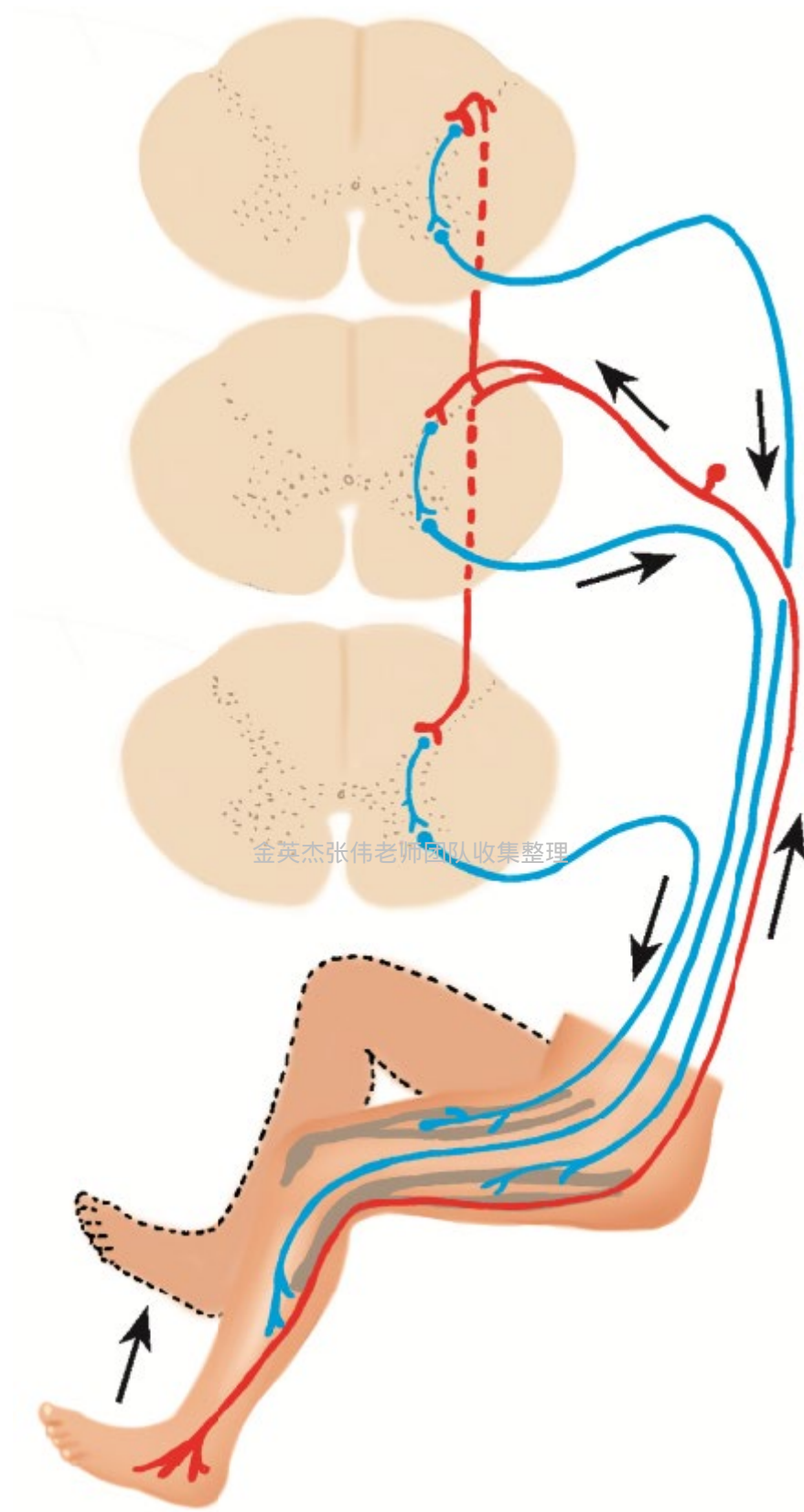
金英杰张为老师团队收集整理



金英杰张为老师

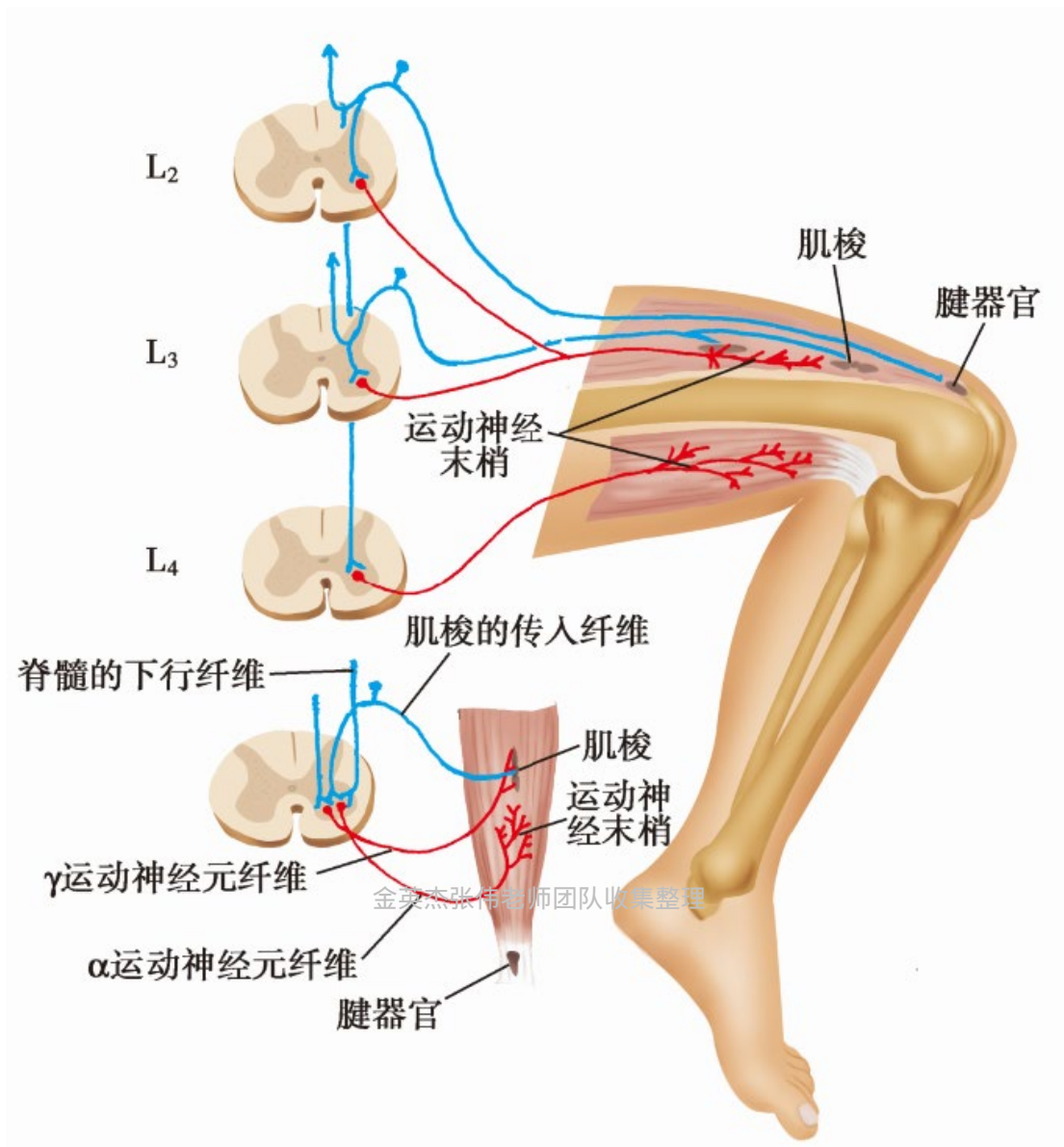
获取更多医考资料请关注





获取更多医考资料请关注

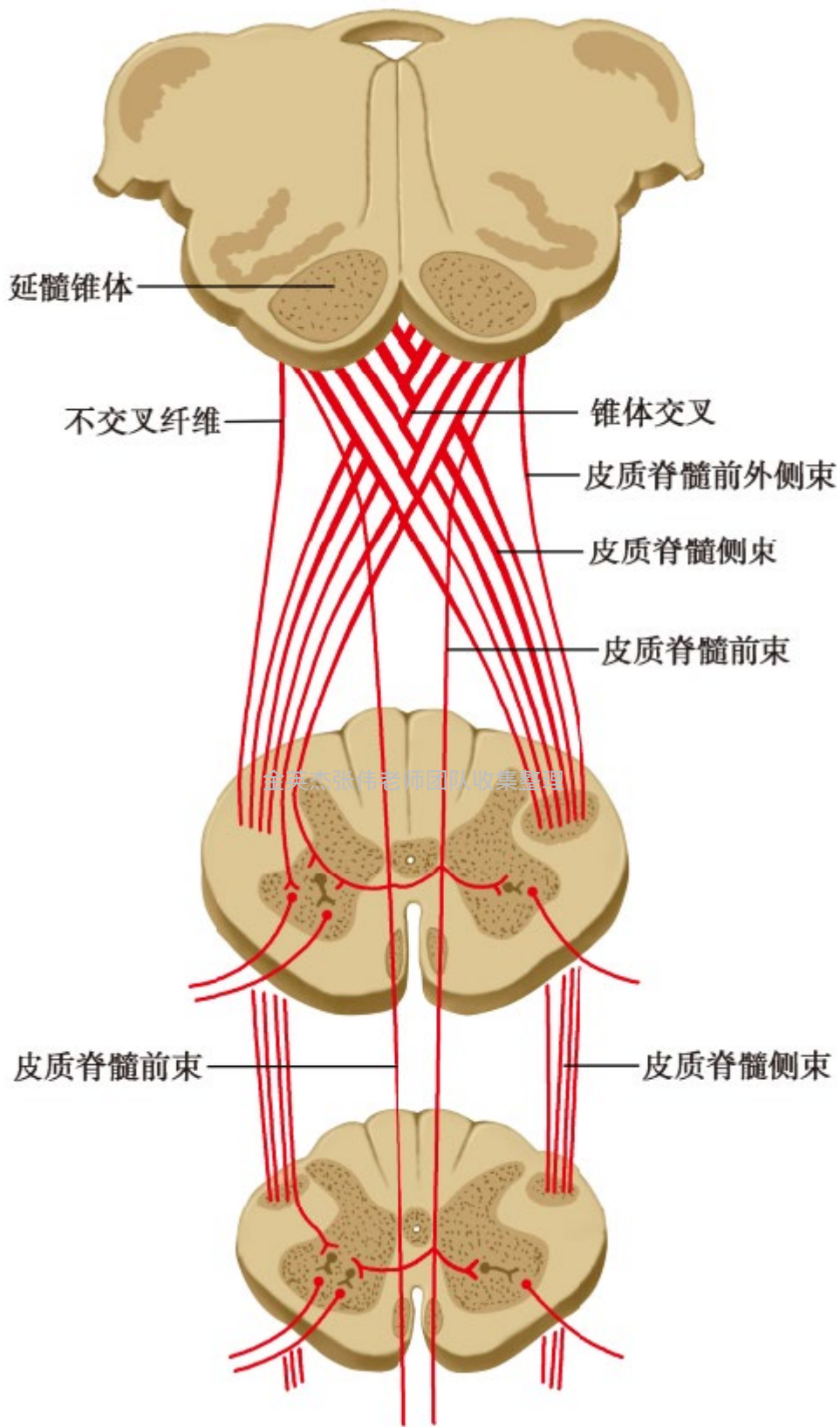




金英杰张伟老师

获取更多医考资料请关注





金英杰张伟老师



获取更多医考资料请关注

脊髓丘脑侧束

脊髓丘脑前束

金英杰张仕之团队收集整理



金英杰张仕之老师

S

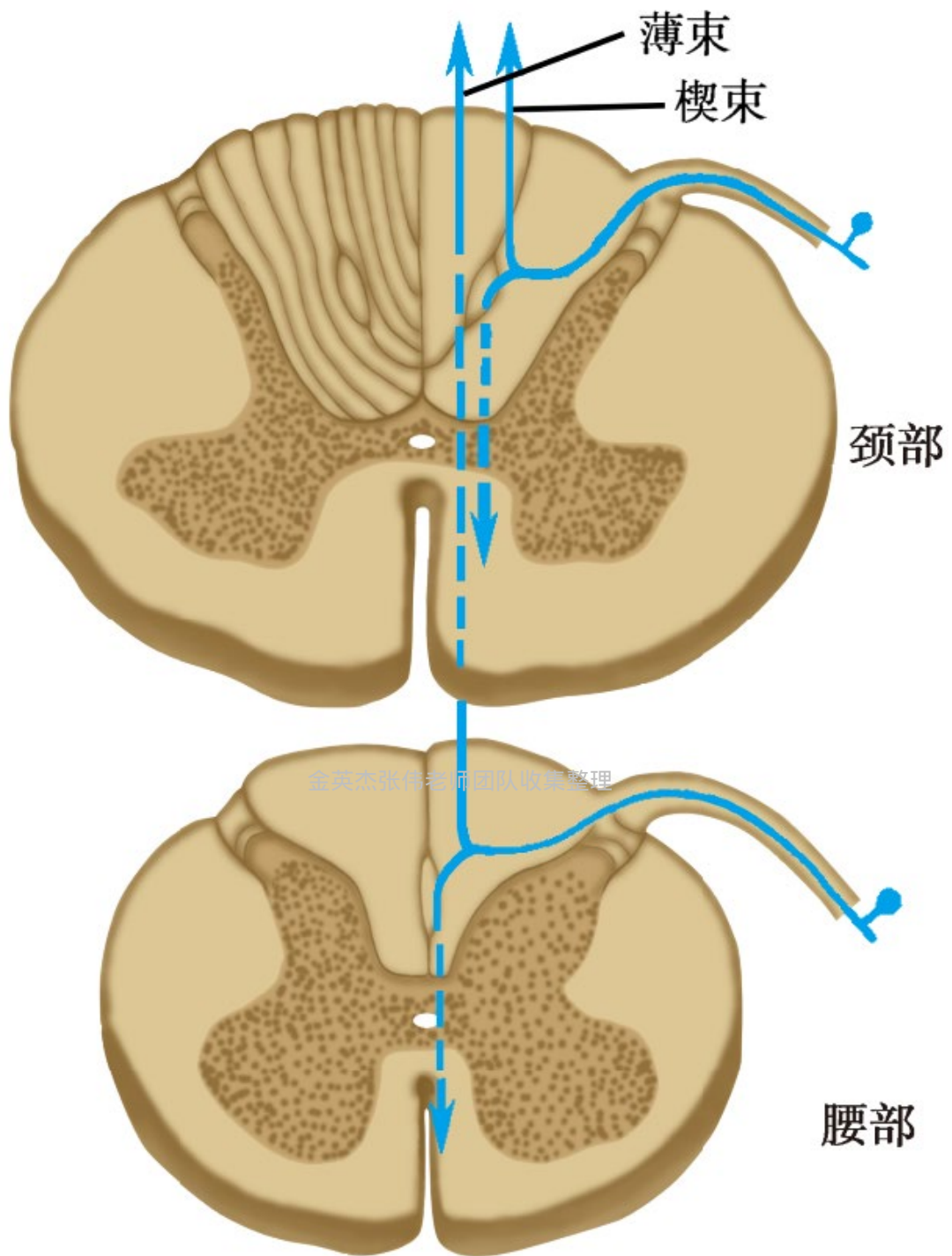
L

T

C

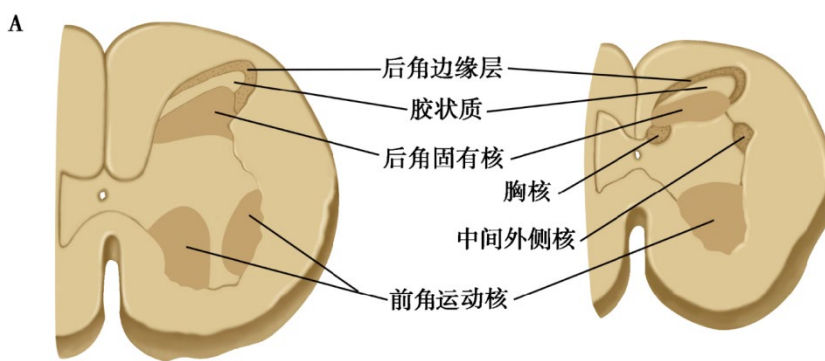
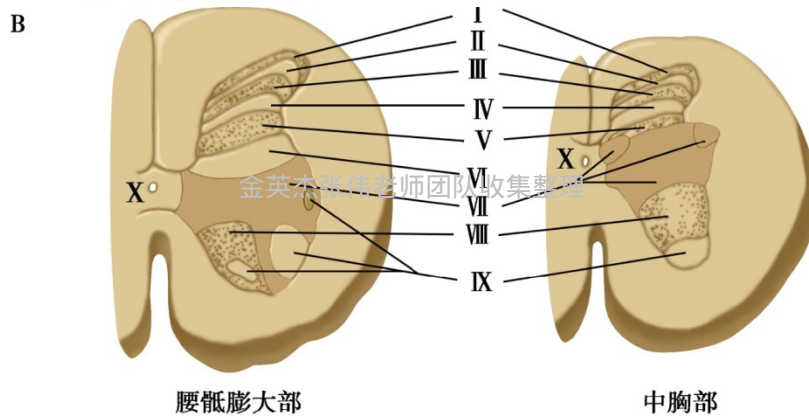
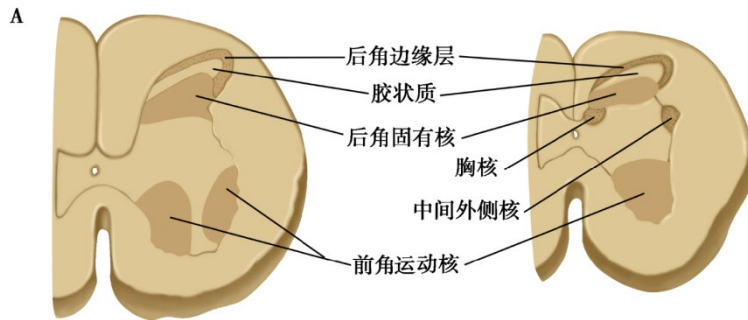
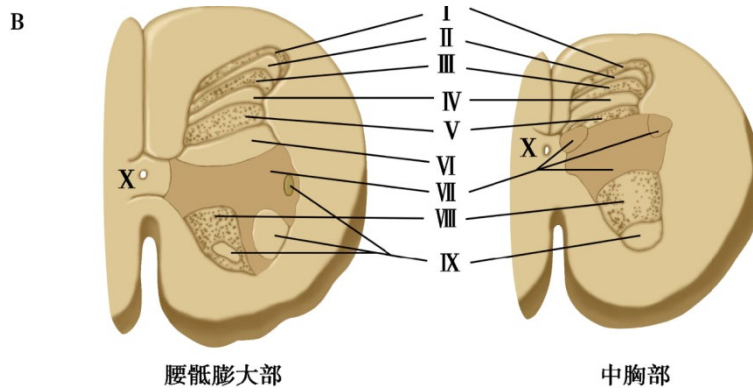
获取更多医考资料请关注

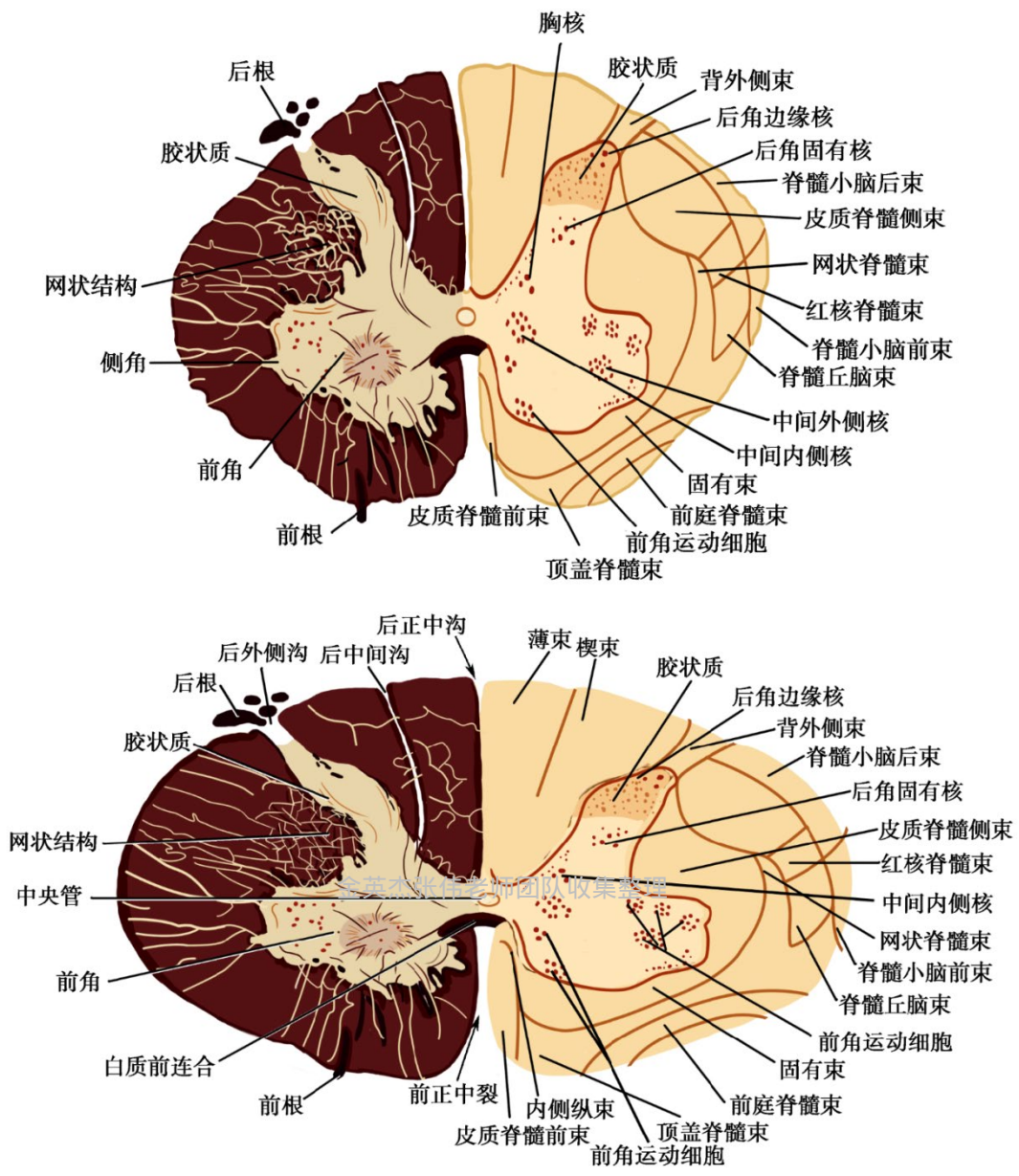




获取更多医考资料请关注



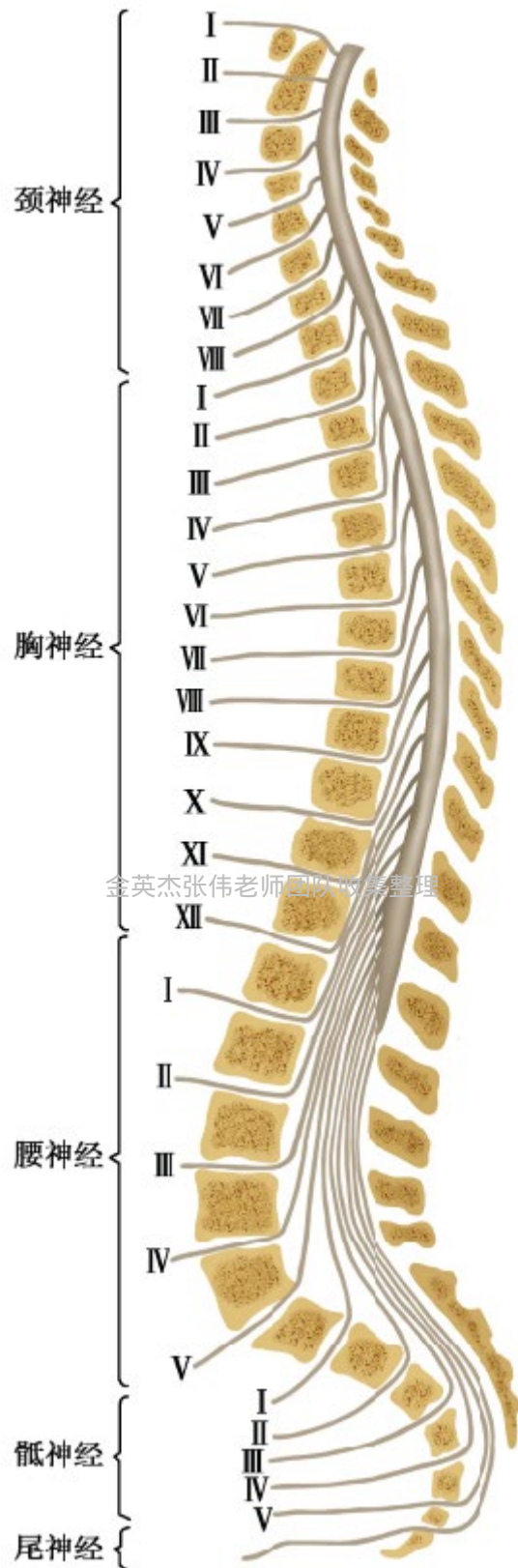




金英杰张伟老师

获取更多医考资料请关注

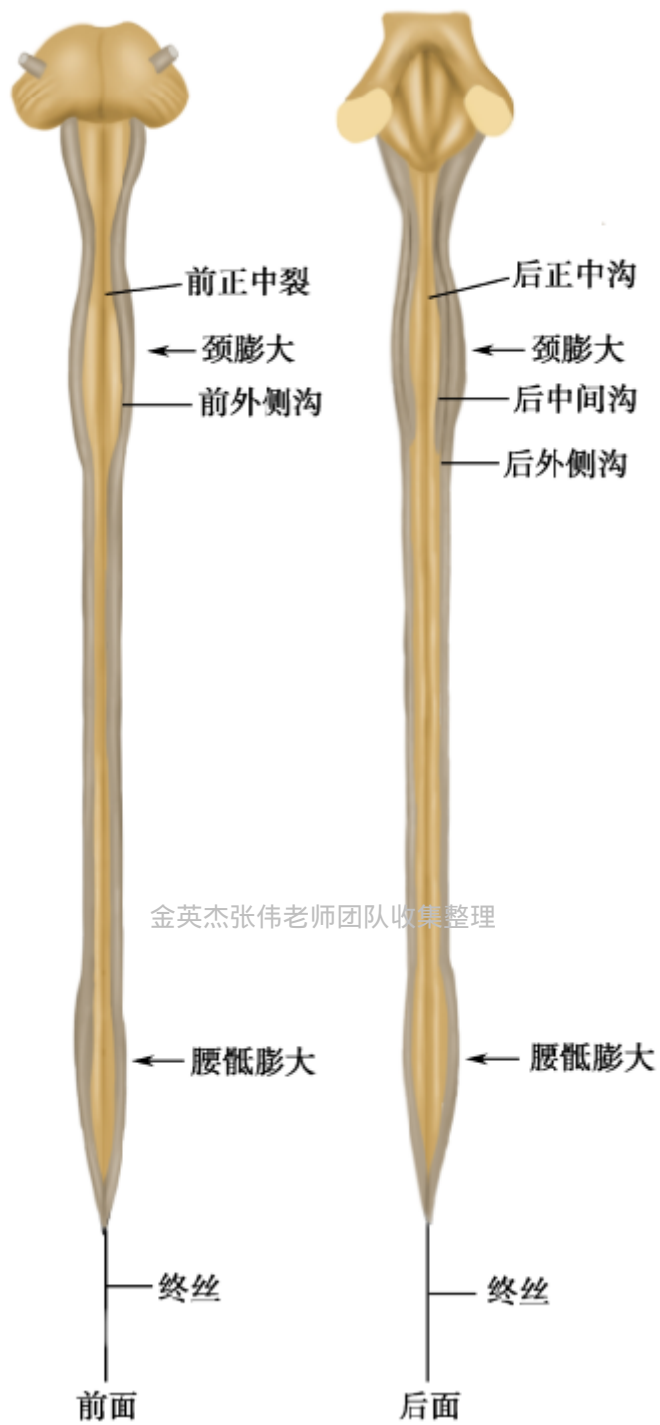




金英杰张伟老师

获取更多医考资料请关注

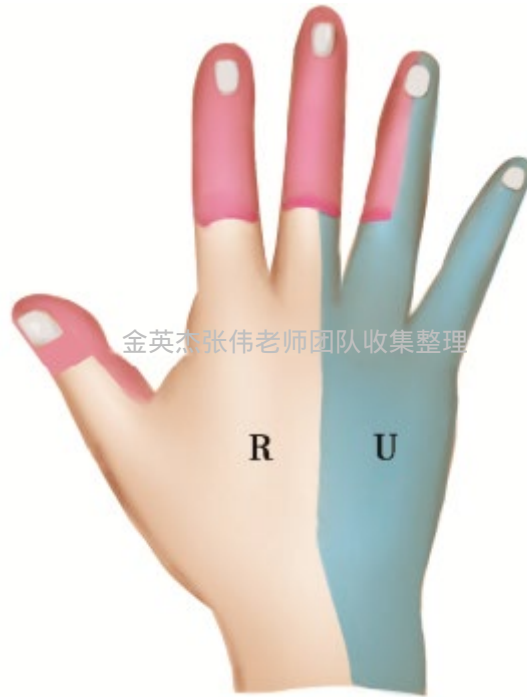



金英杰张伟老师

获取更多医考资料请关注





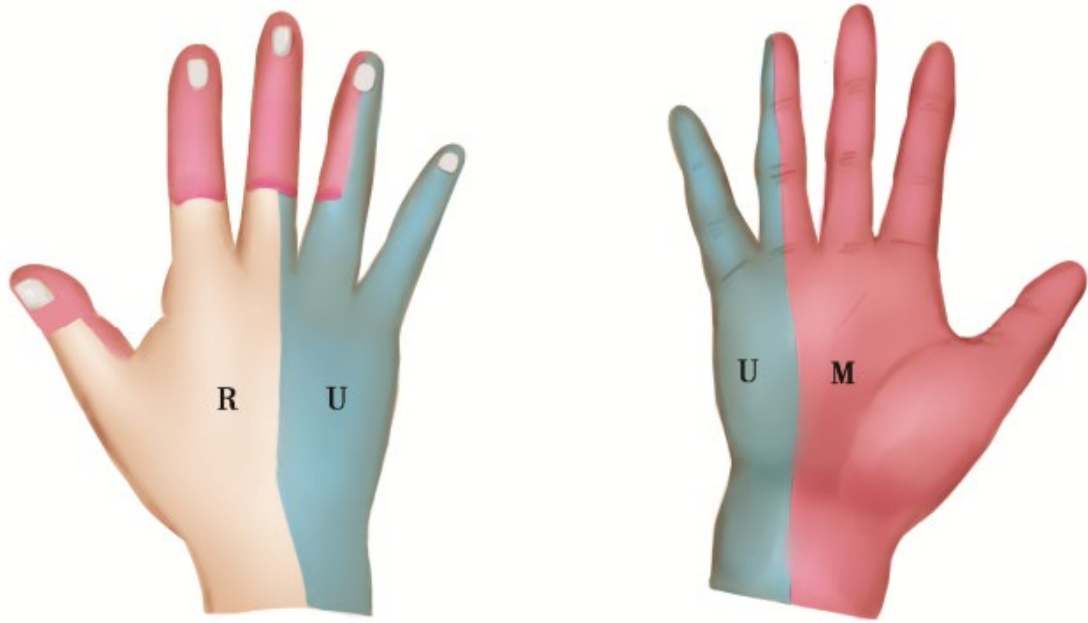
金英杰张伟老师团队收集整理



金英杰张伟老师

获取更多医考资料请关注



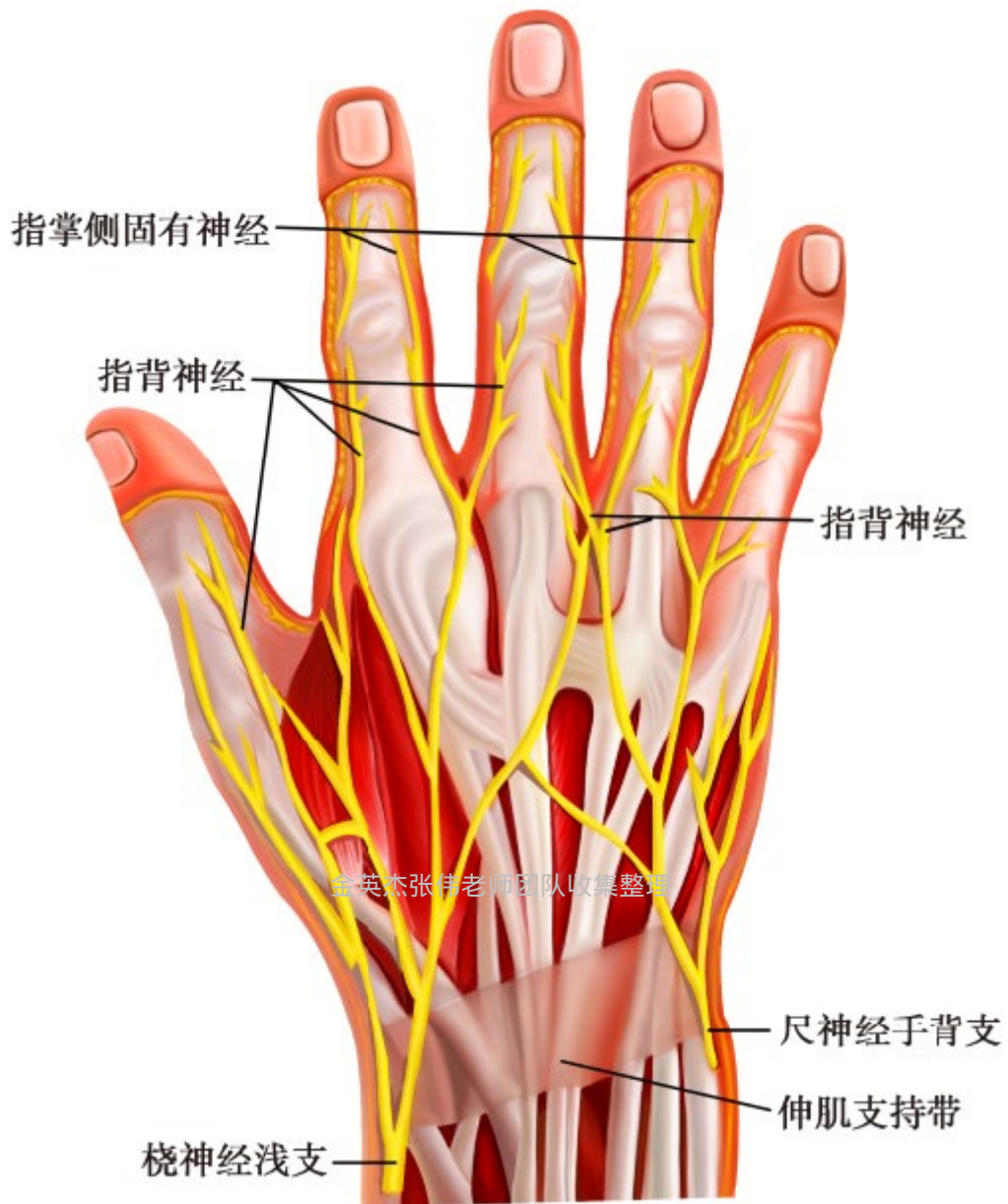


金英杰张伟老师团队收集整理



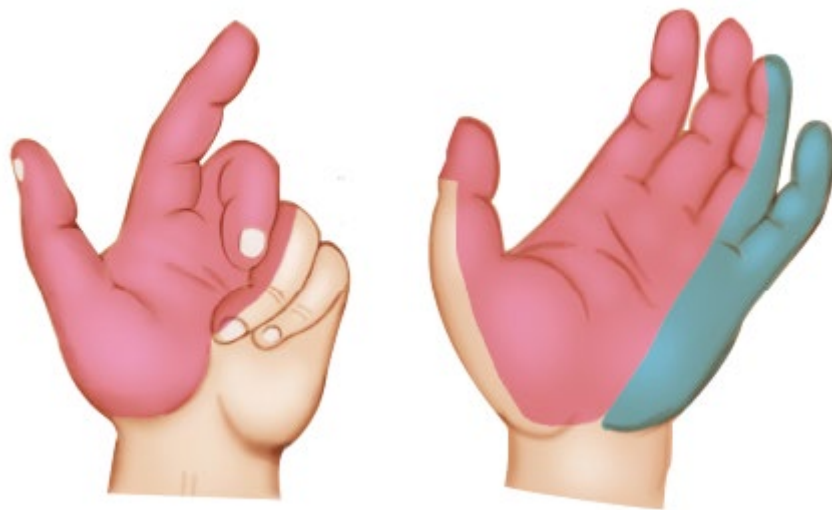
获取更多医考资料请关注





获取更多医考资料请关注



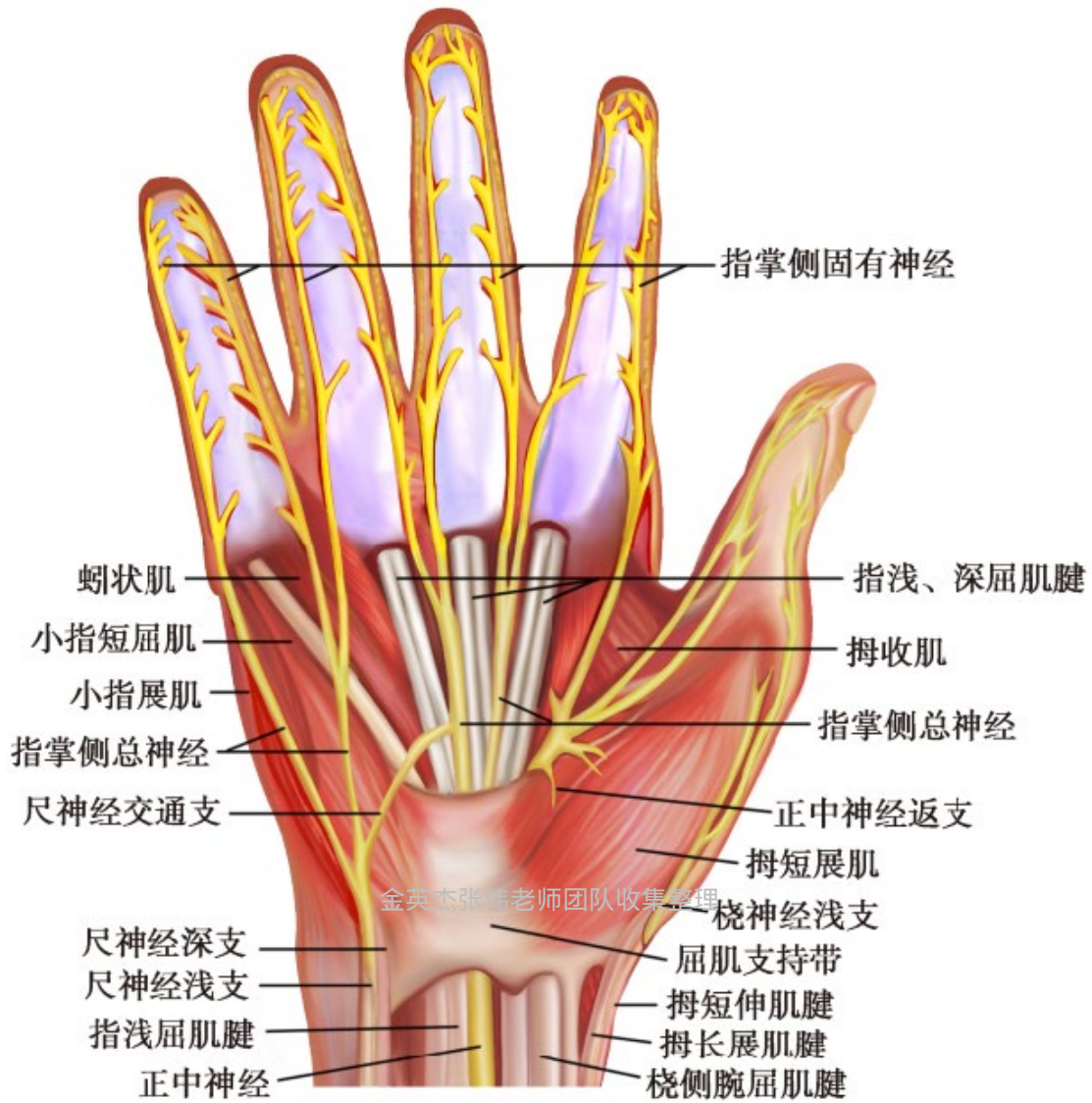


金英杰张伟老师团队收集整理

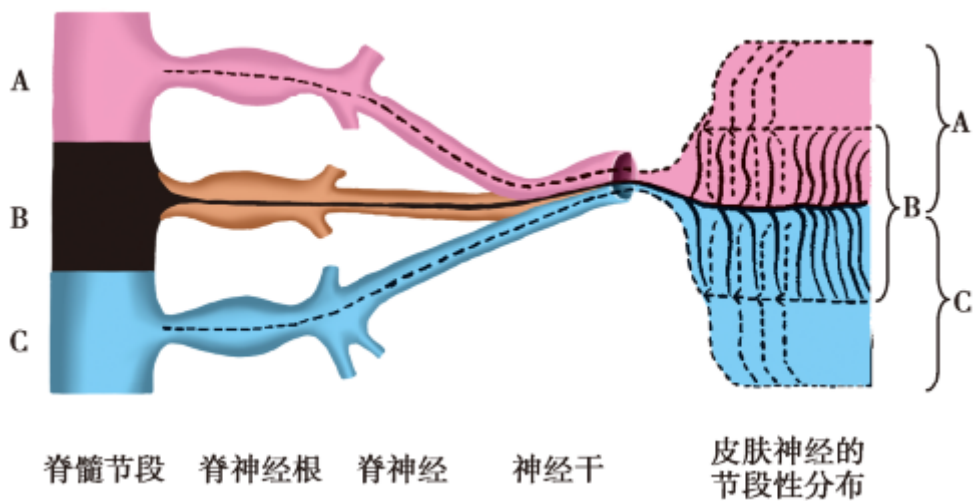


获取更多医考资料请关注



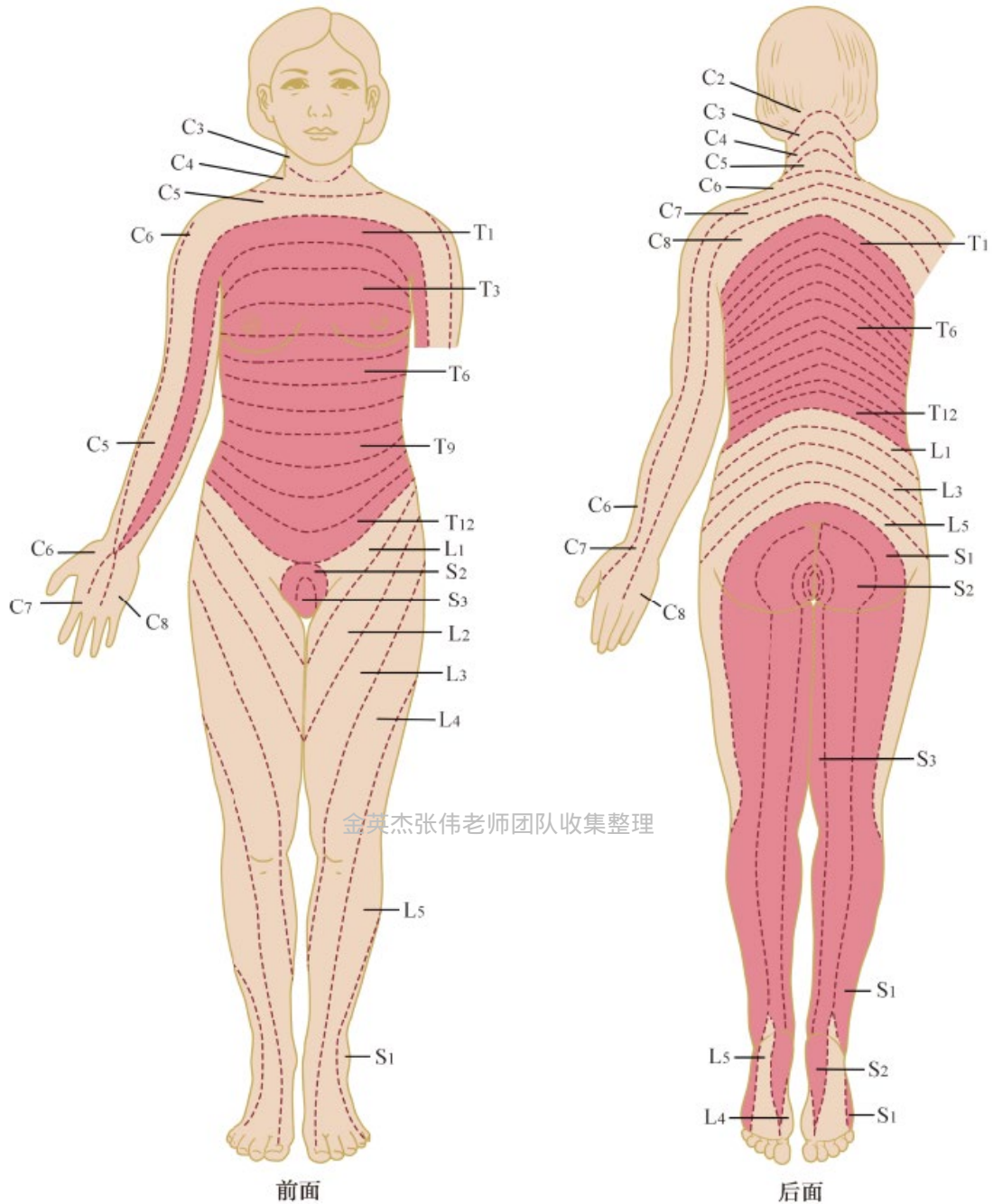


金英杰张伟老师团队收集整理



获取更多医考资料请关注





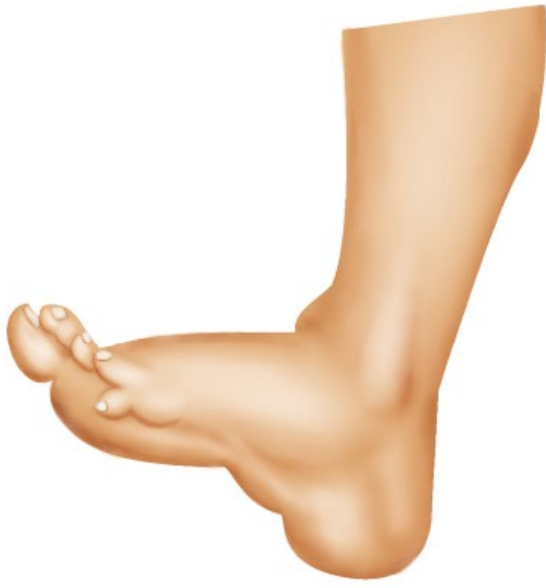金英杰张伟老师团队收集整理



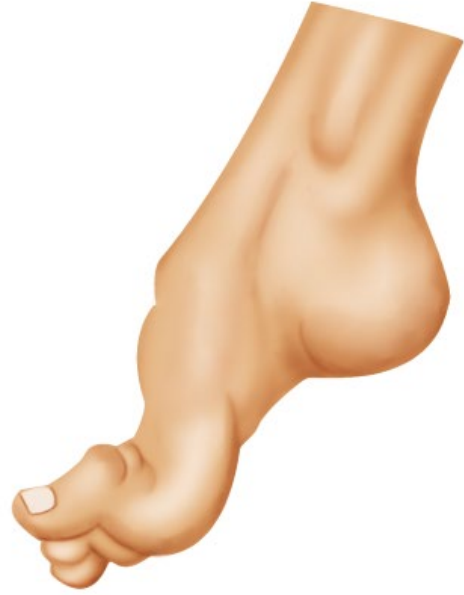金英杰张伟老师

获取更多医考资料请关注





钩状足(胫神经损伤)



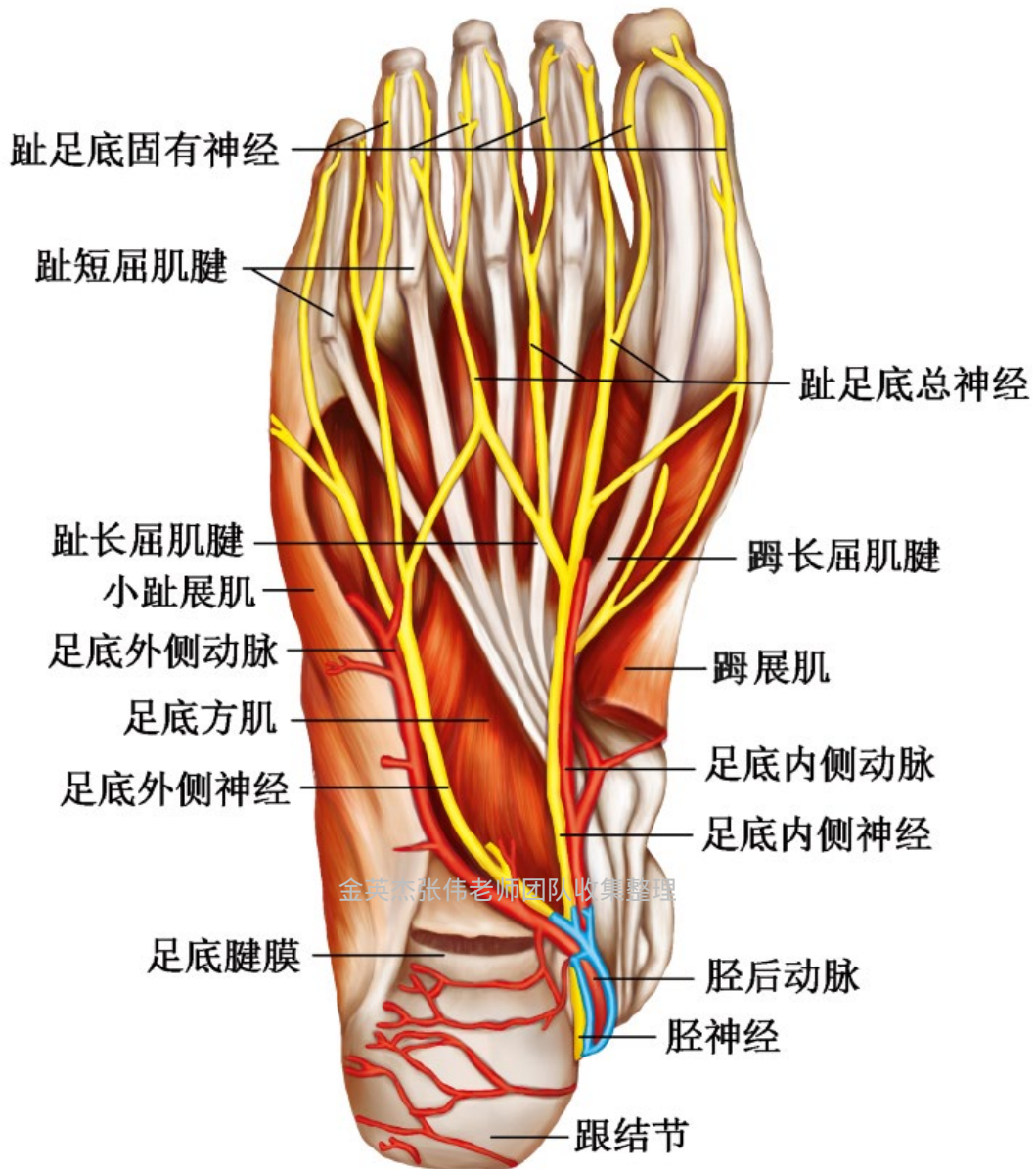
“马蹄”内翻足(腓总神经损伤)

金英杰张伟老师团队收集整理



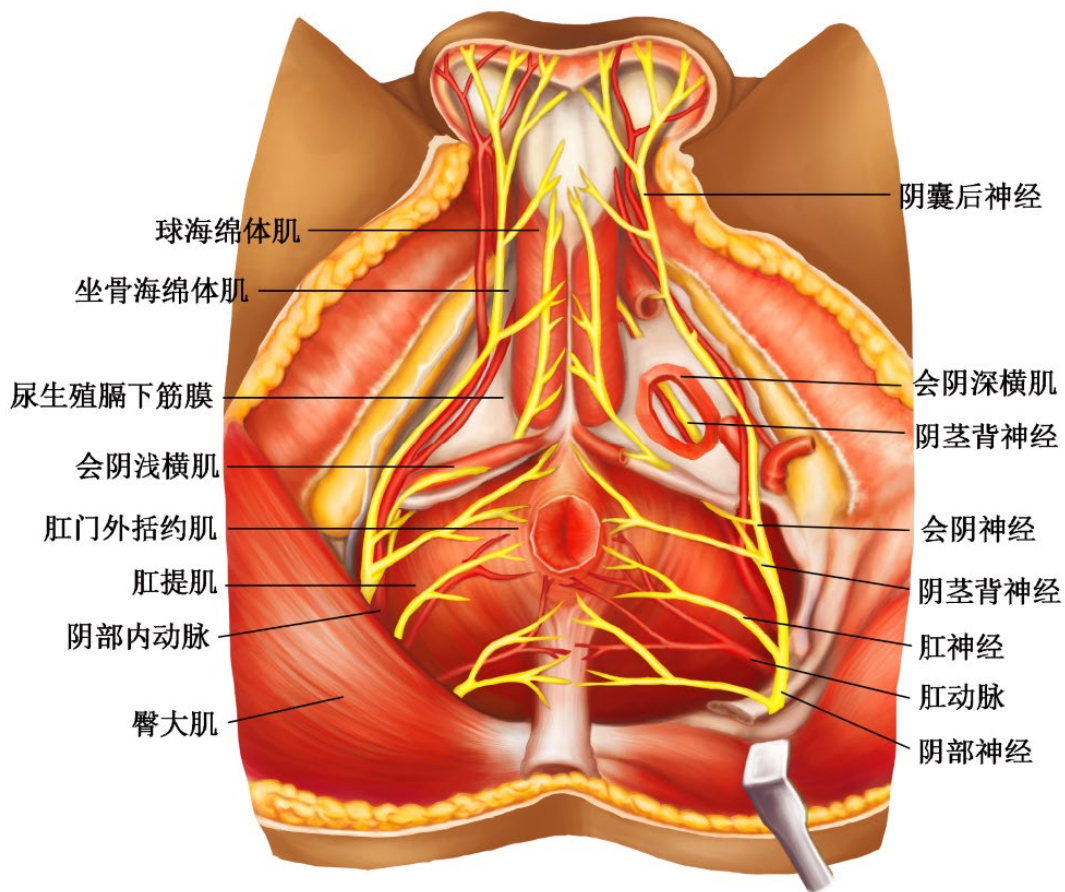
获取更多医考资料请关注





获取更多医考资料请关注





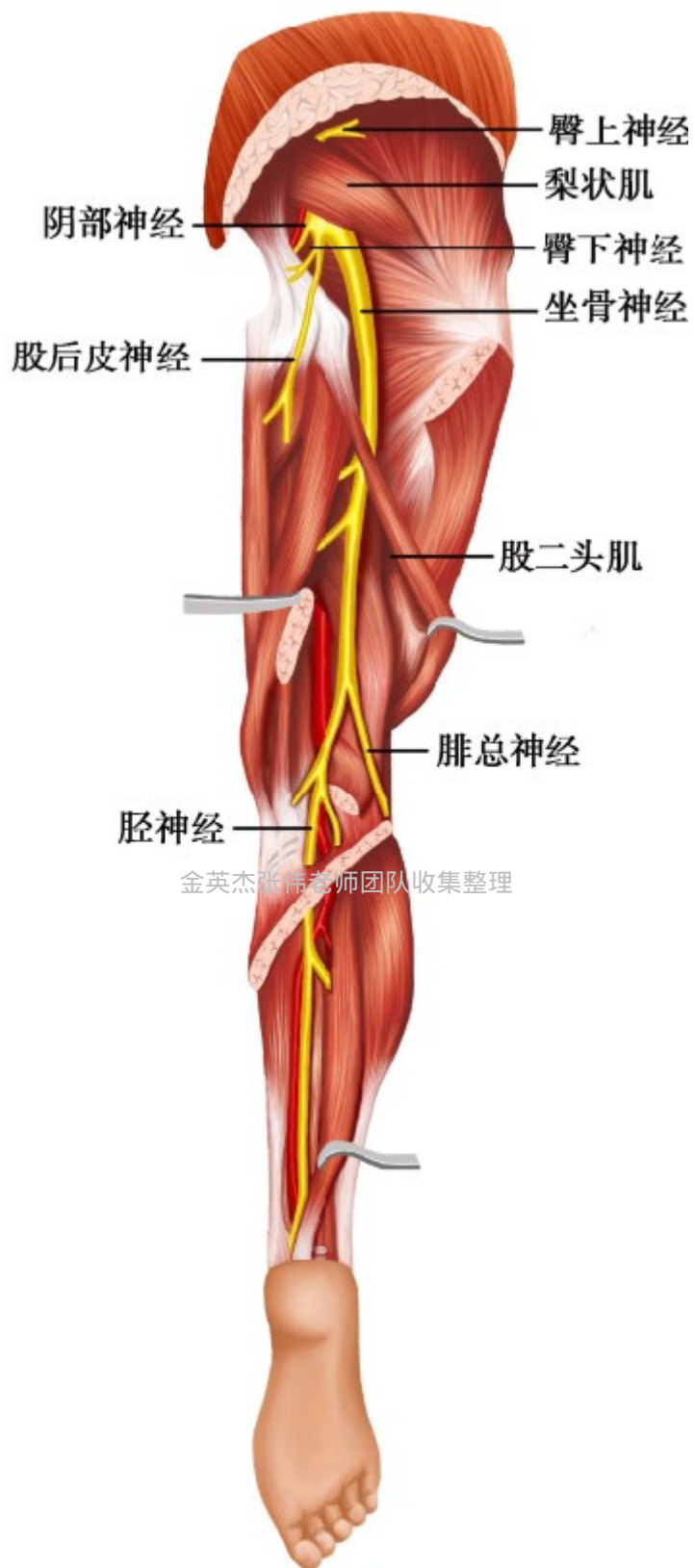
金英杰张伟老师团队收集整理



金英杰张伟老师

获取更多医考资料请关注



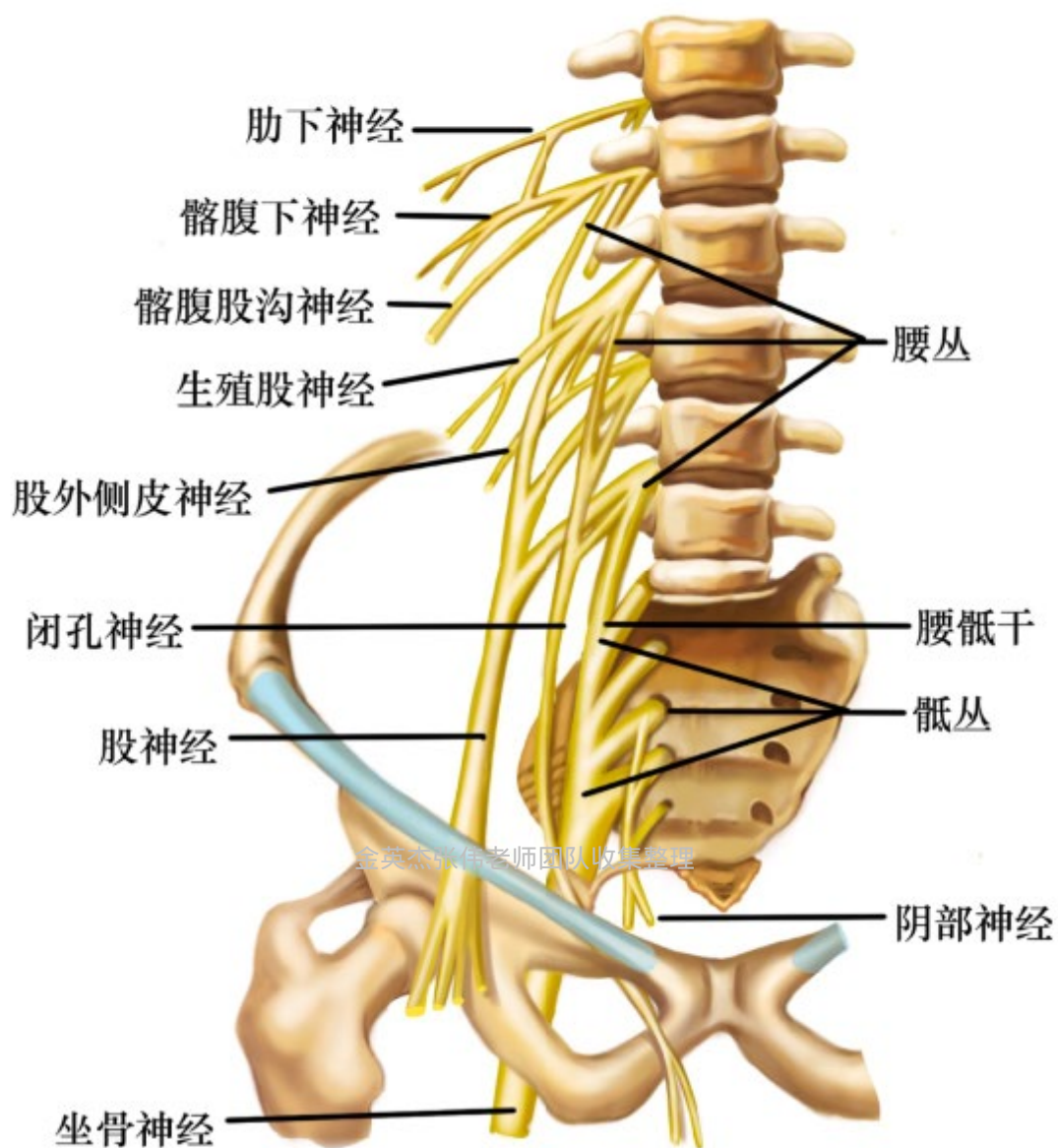


金英杰张伟老师团队收集整理



获取更多医考资料请关注

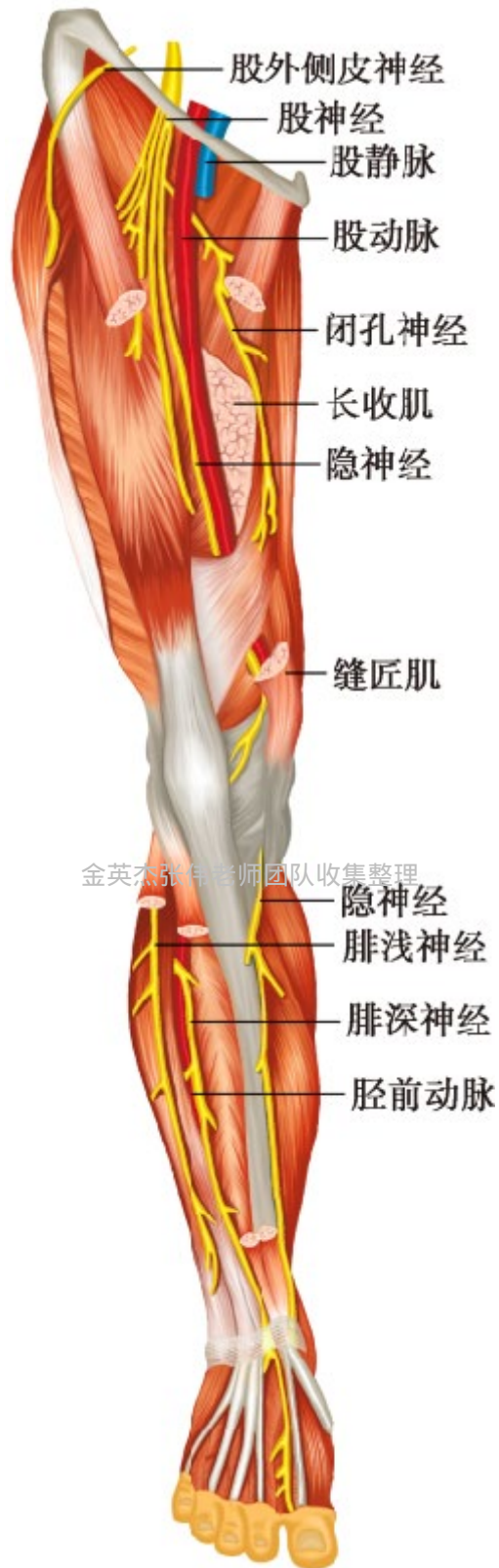




金英杰张伟老师

获取更多医考资料请关注





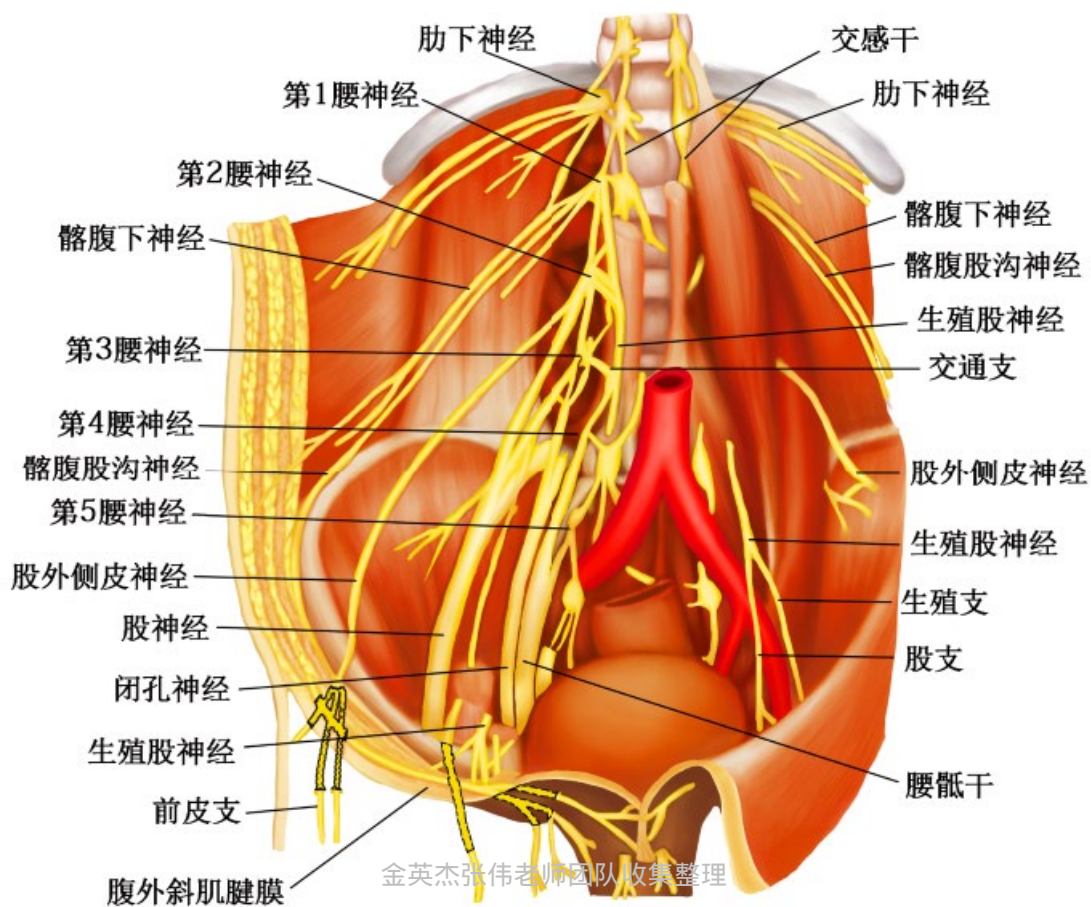
金英杰张宇老师团队收集整理



金英杰张宇老师

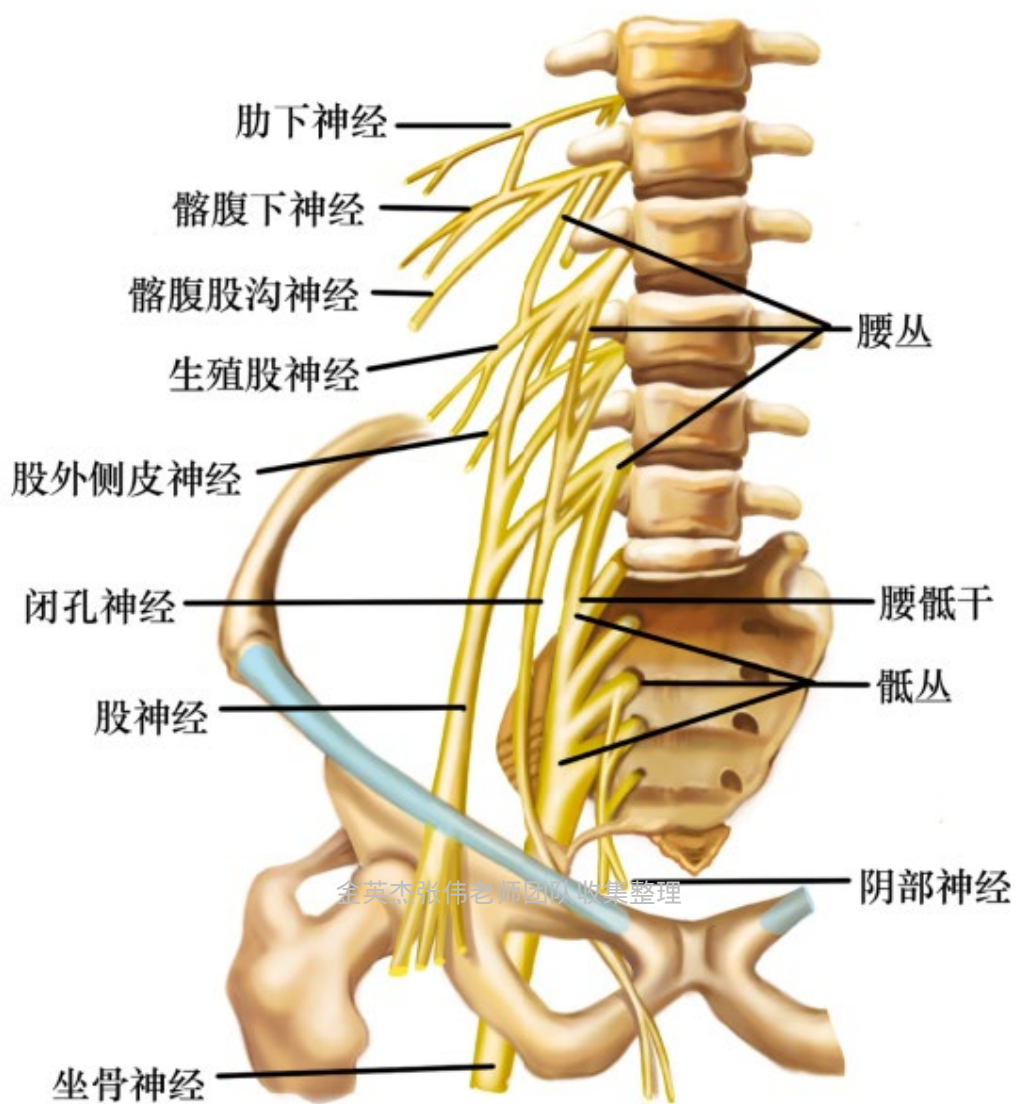
获取更多医考资料请关注





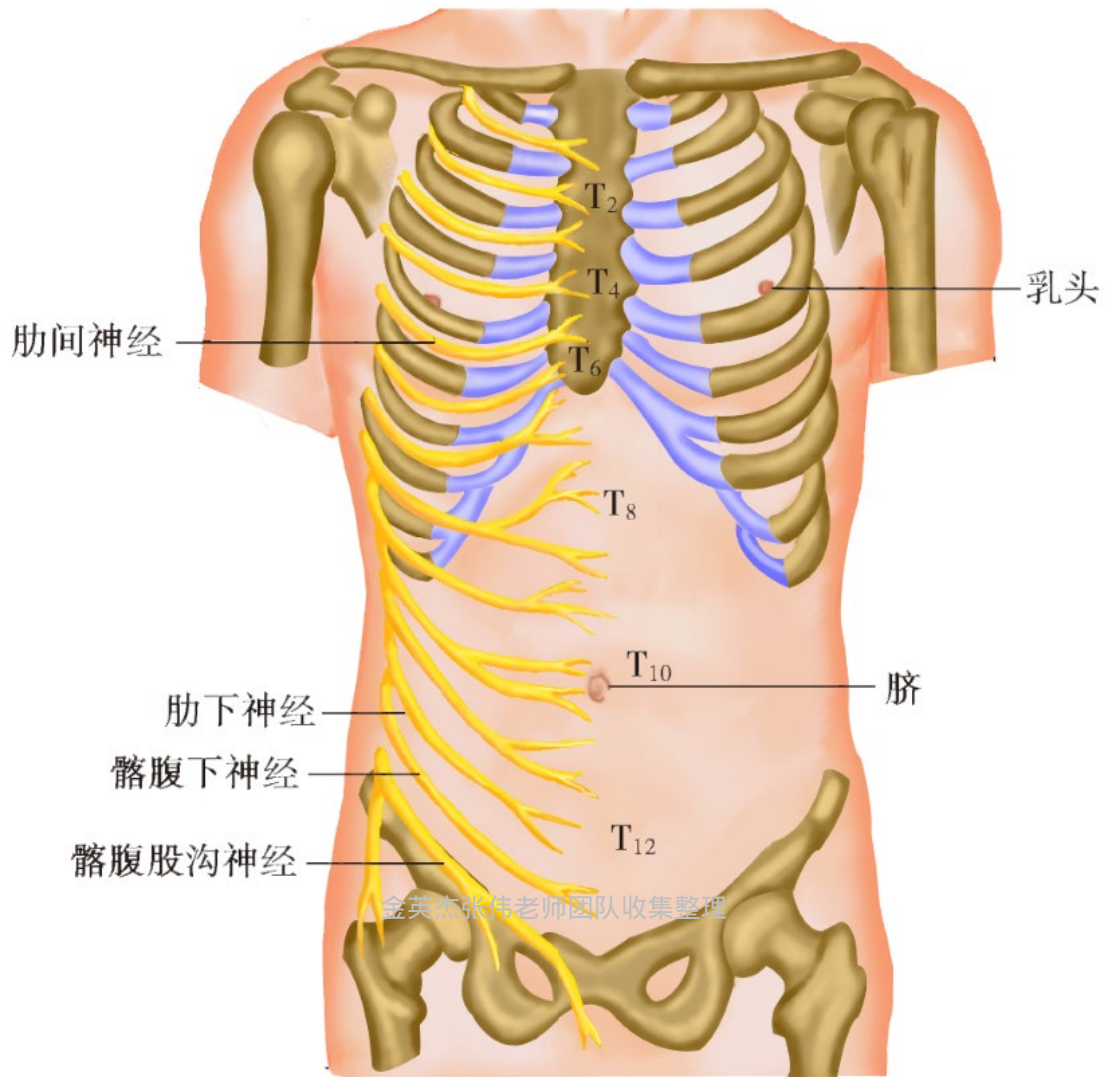
获取更多医考资料请关注





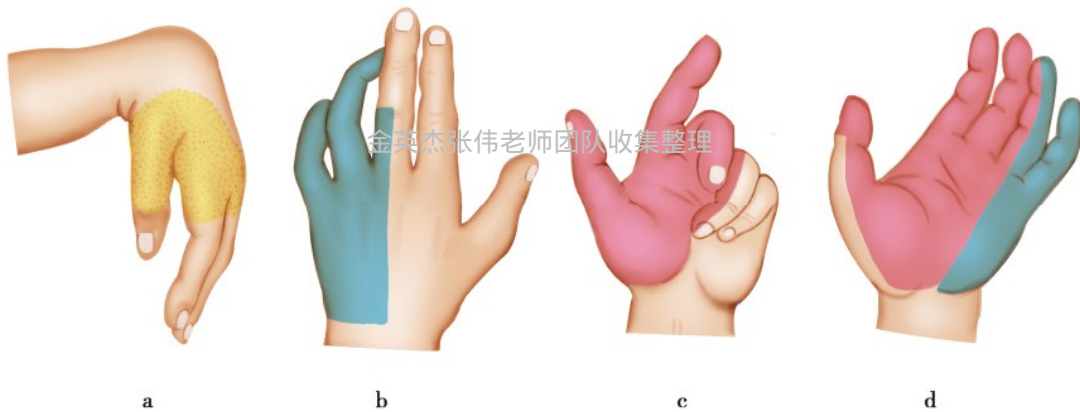
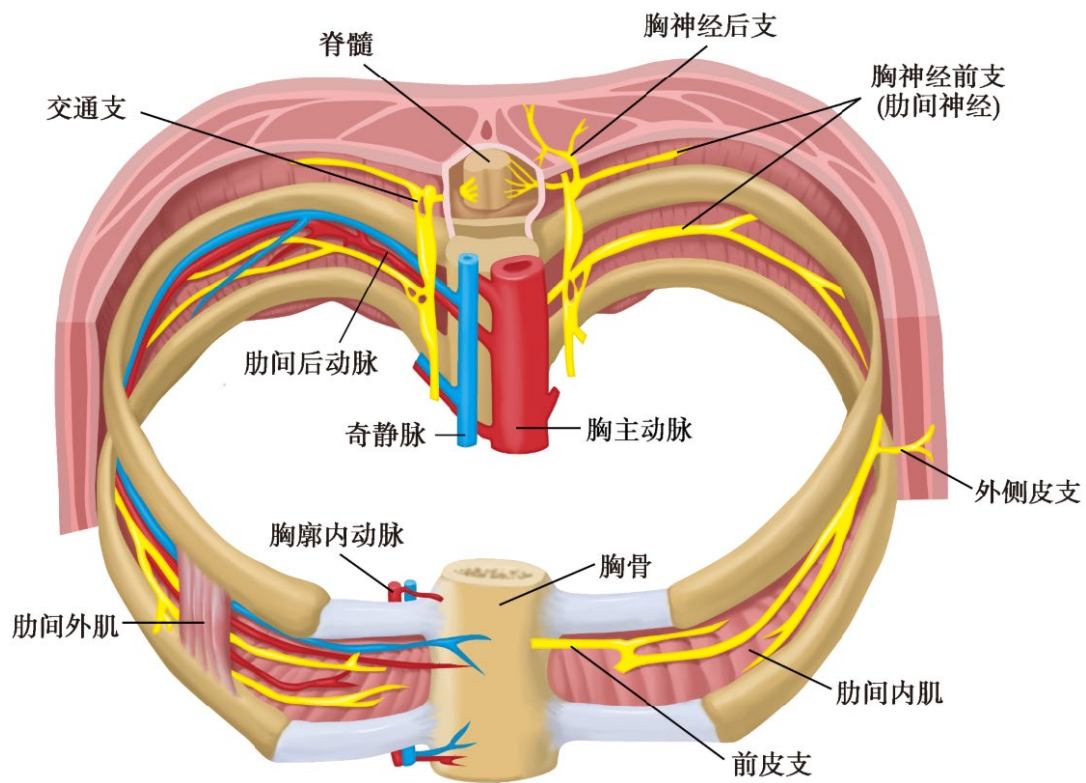
获取更多医考资料请关注





获取更多医考资料请关注





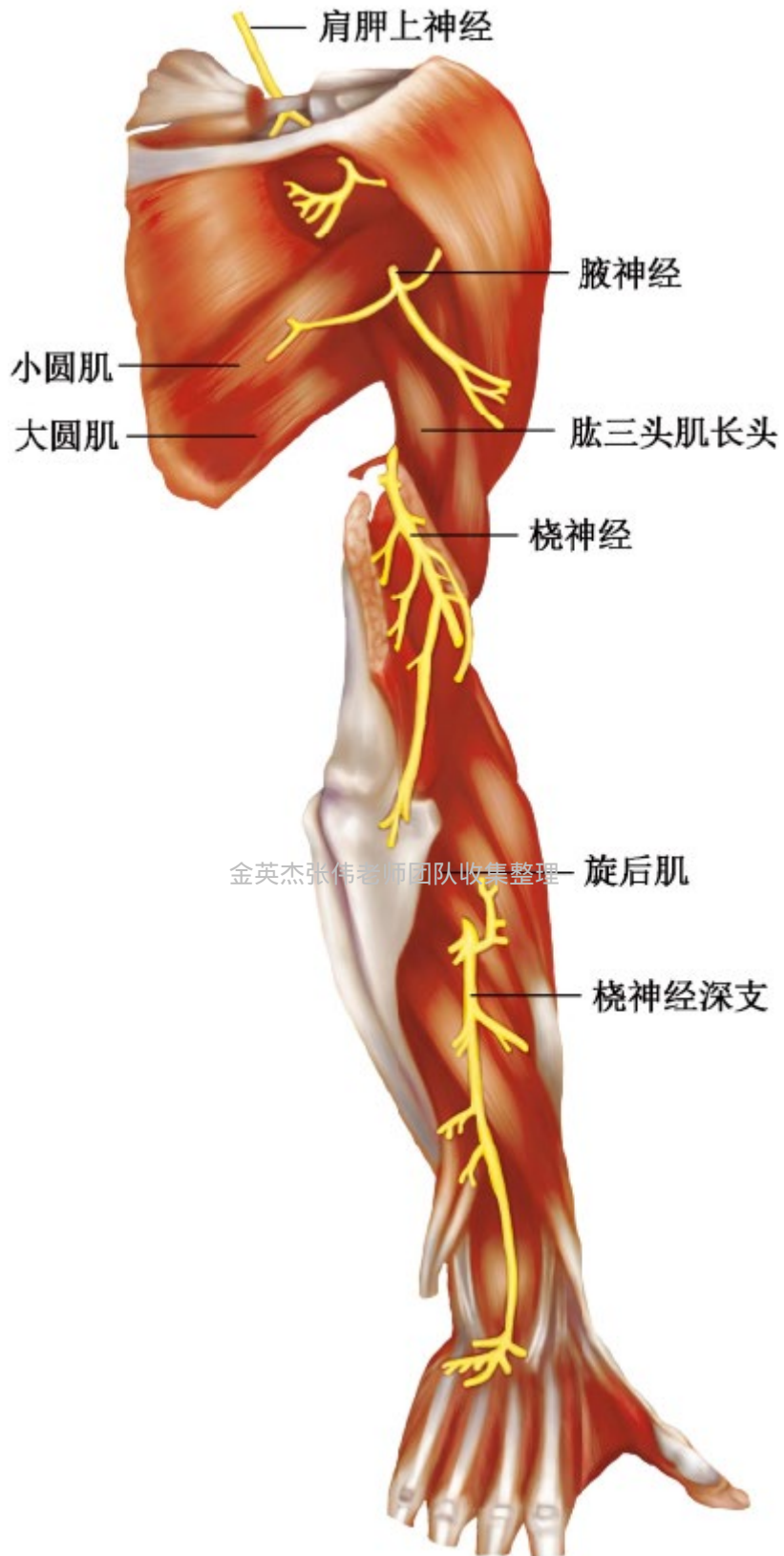
金英杰张伟老师团队收集整理



金英杰张伟老师

获取更多医考资料请关注

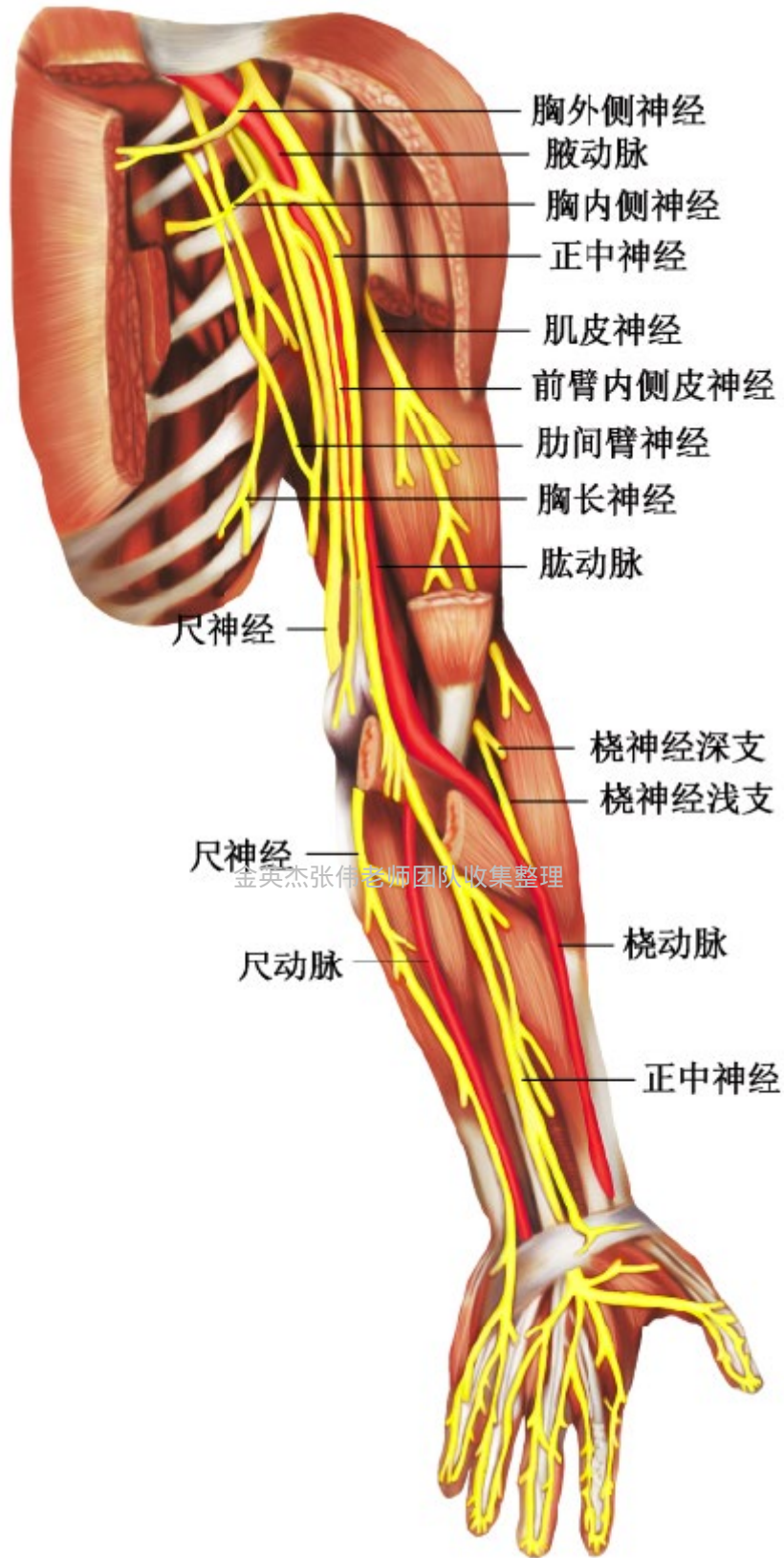




金英杰张伟老师

获取更多医考资料请关注





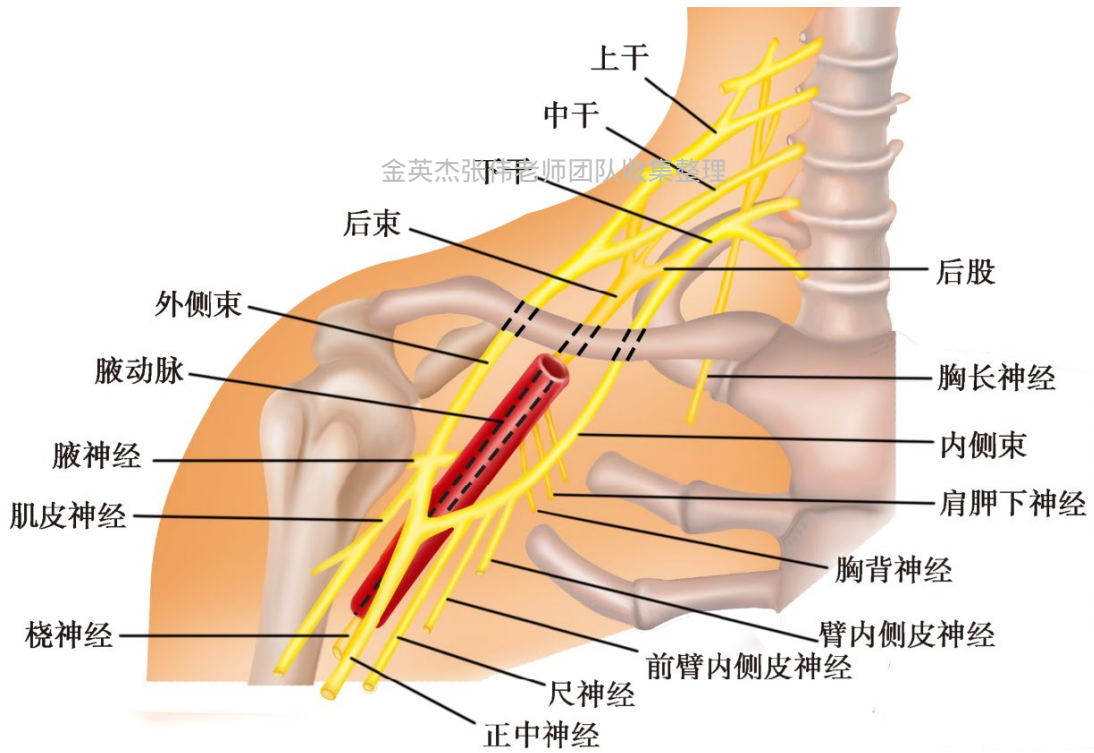
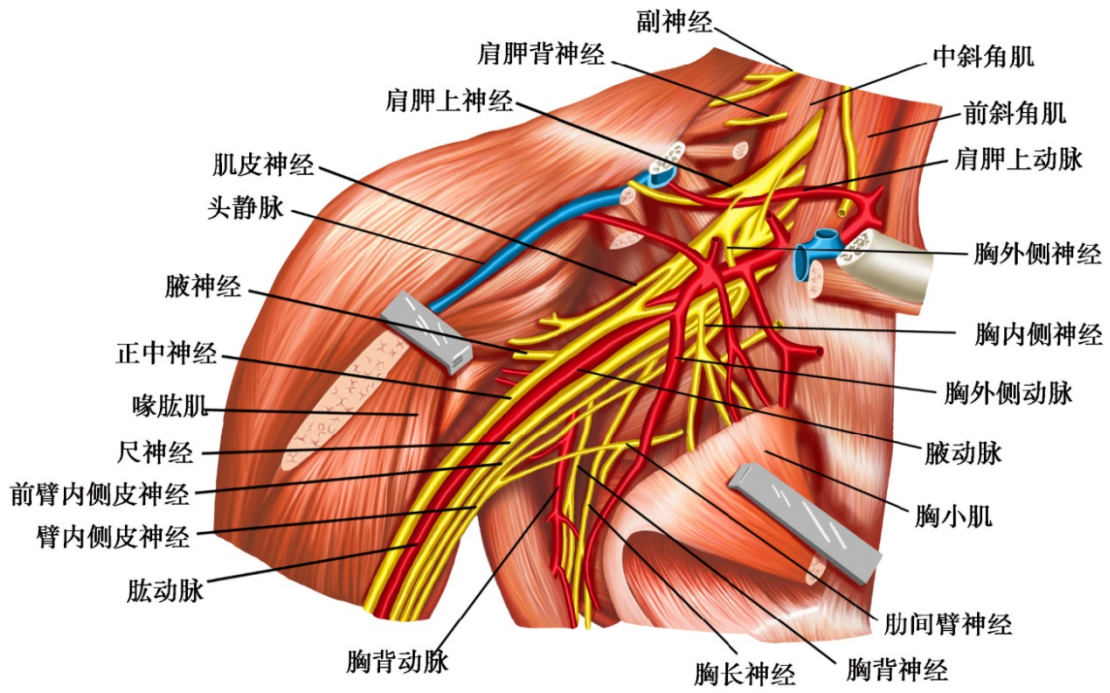
金英杰张伟老师团队收集整理



金英杰张伟老师

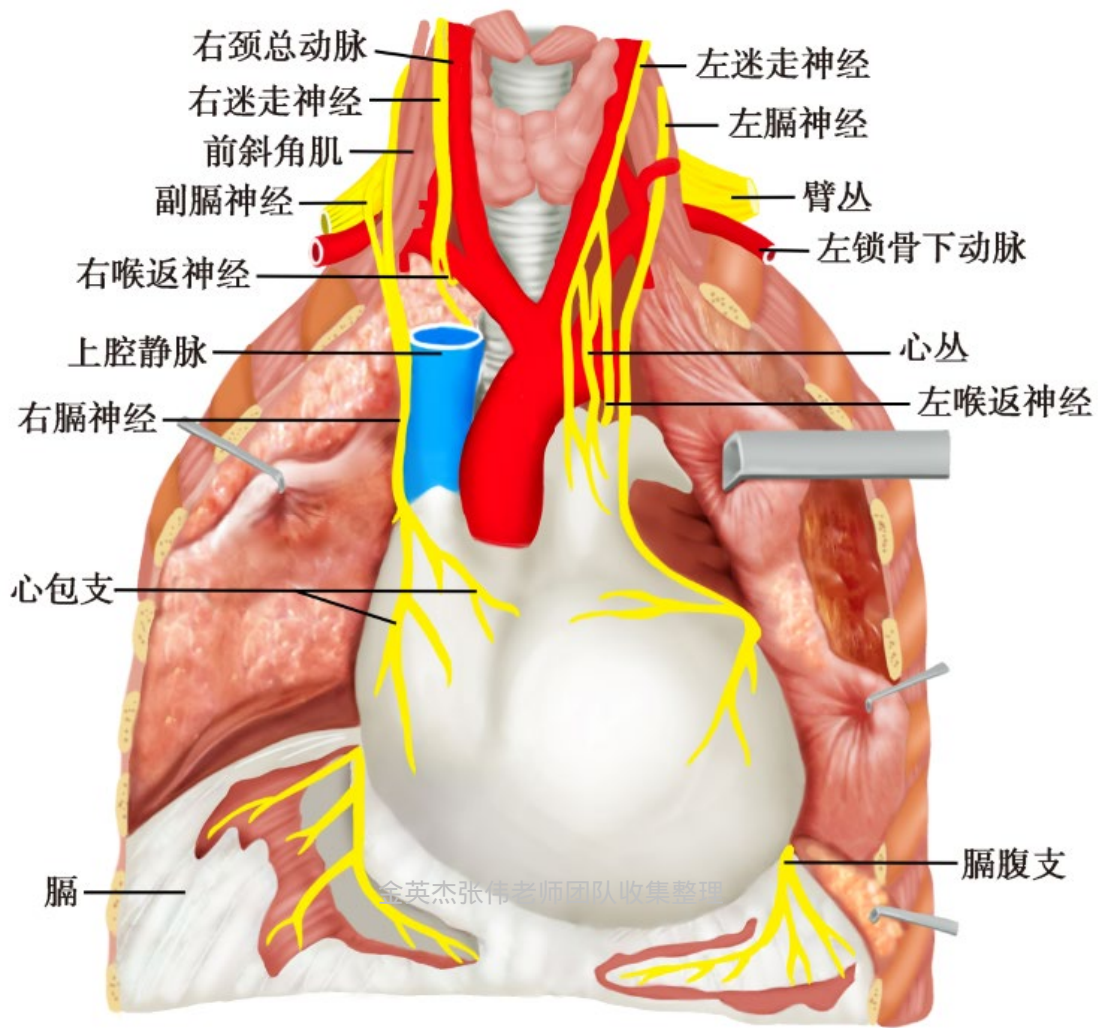


获取更多医考资料请关注



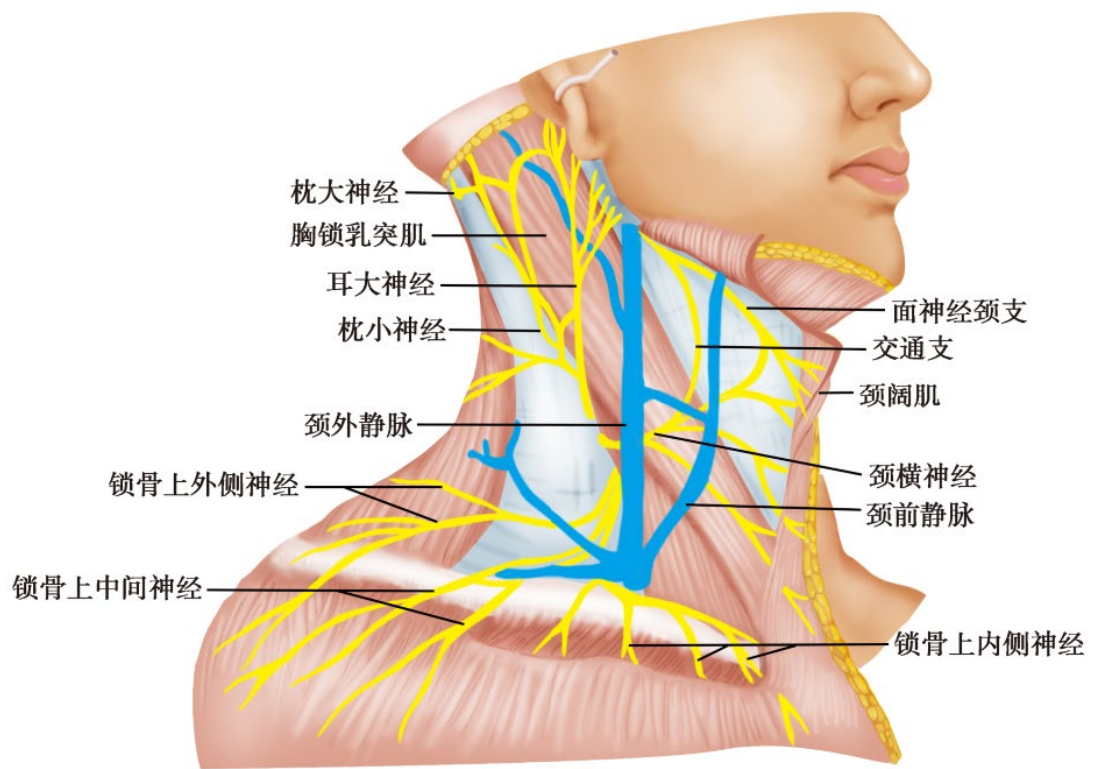
获取更多医考资料请关注





获取更多医考资料请关注



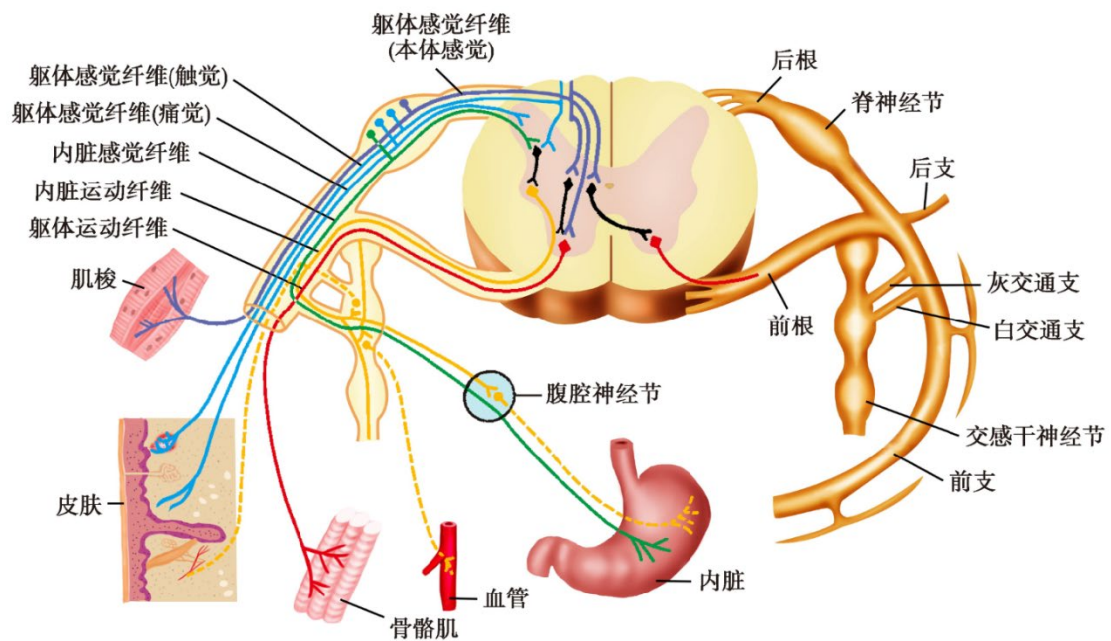
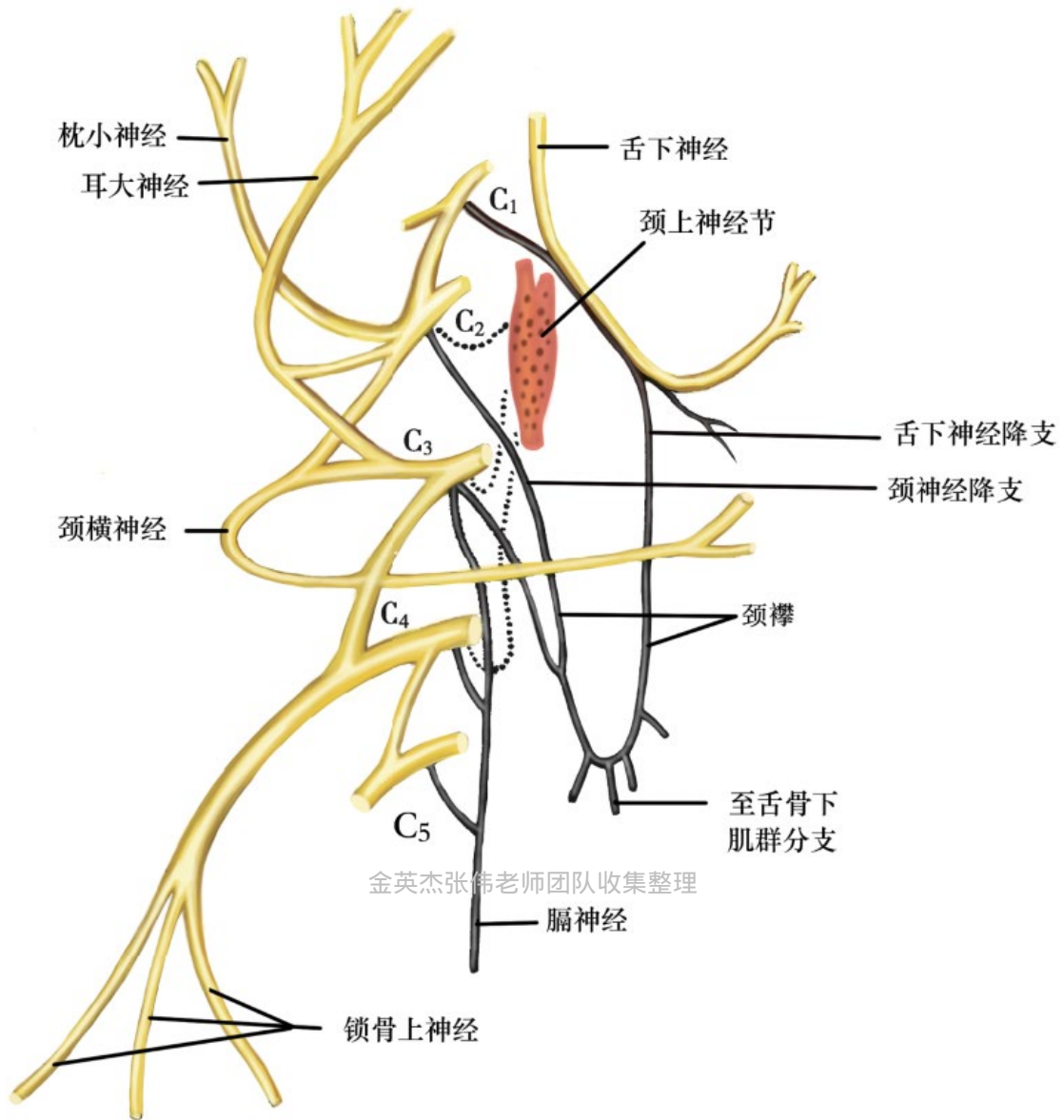


金英杰张伟老师团队收集整理



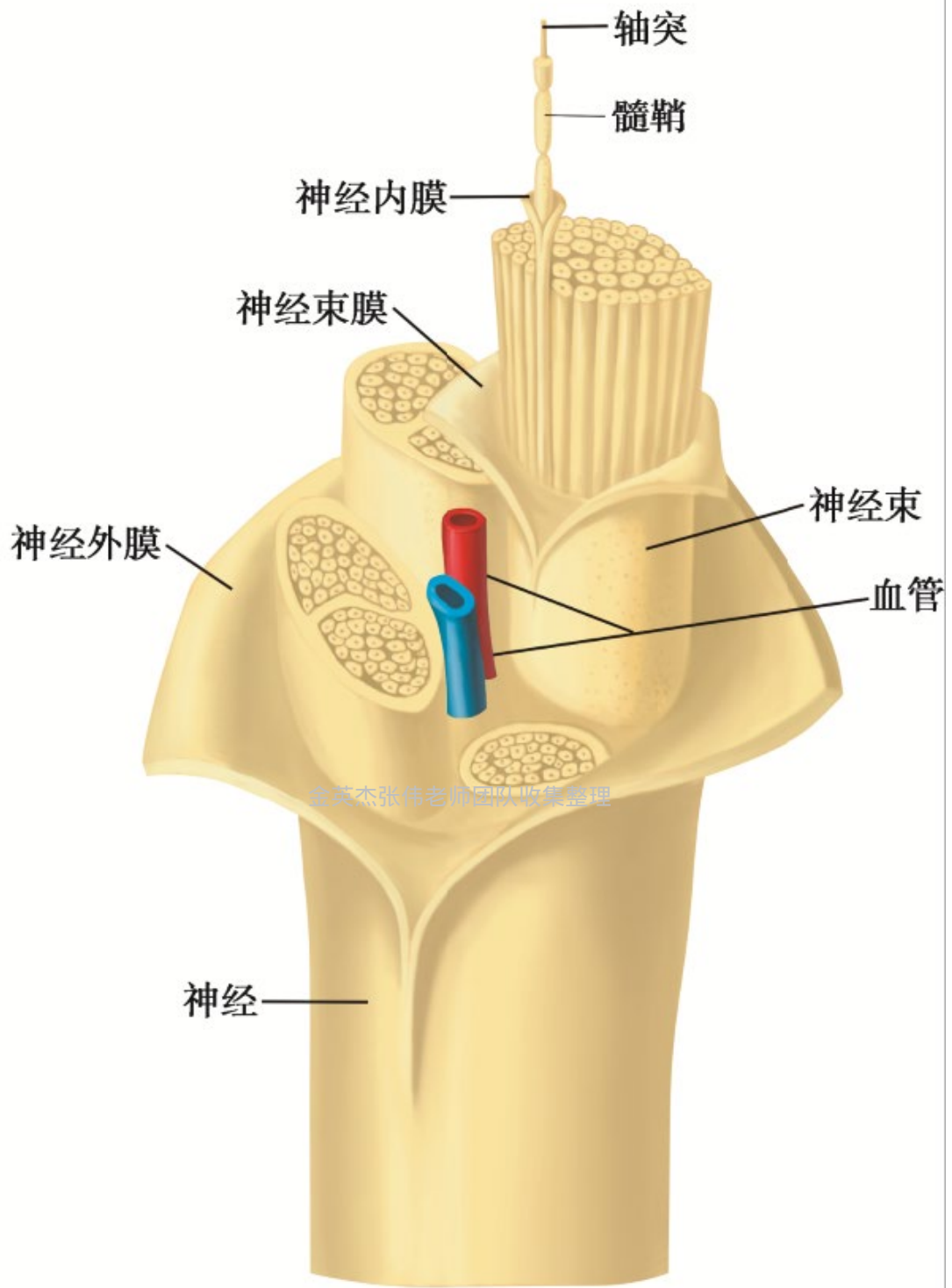
获取更多医考资料请关注





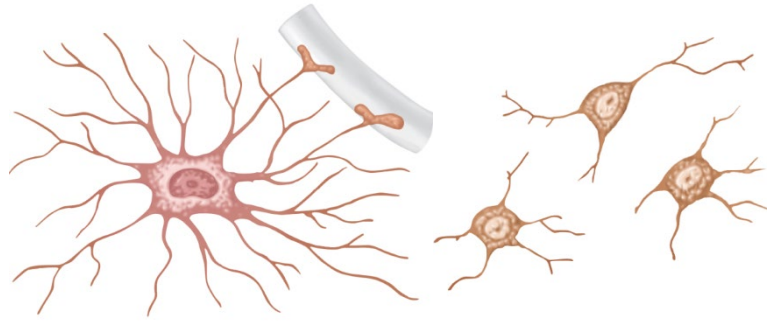
获取更多医考资料请关注





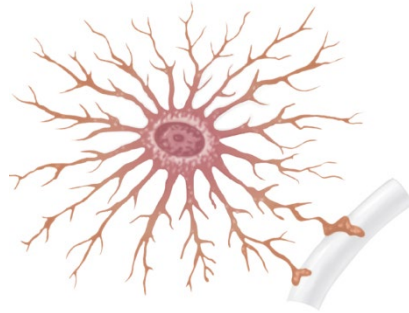
获取更多医考资料请关注



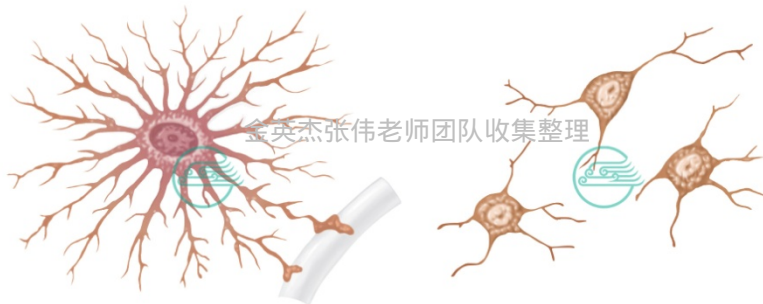


纤维性星形胶质细胞

少突胶质细胞

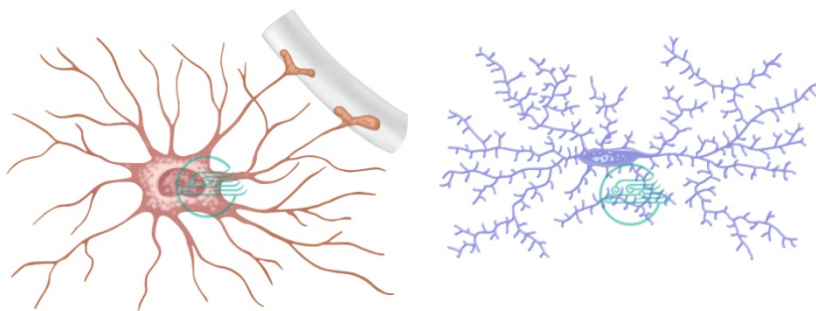


原浆性星形胶质细胞



原浆性星形胶质细胞

少突胶质细胞



纤维性星形胶质细胞

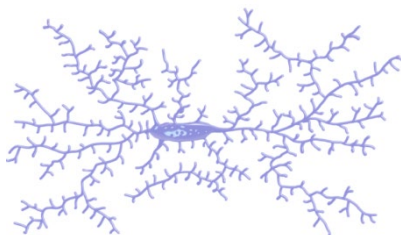
小胶质细胞



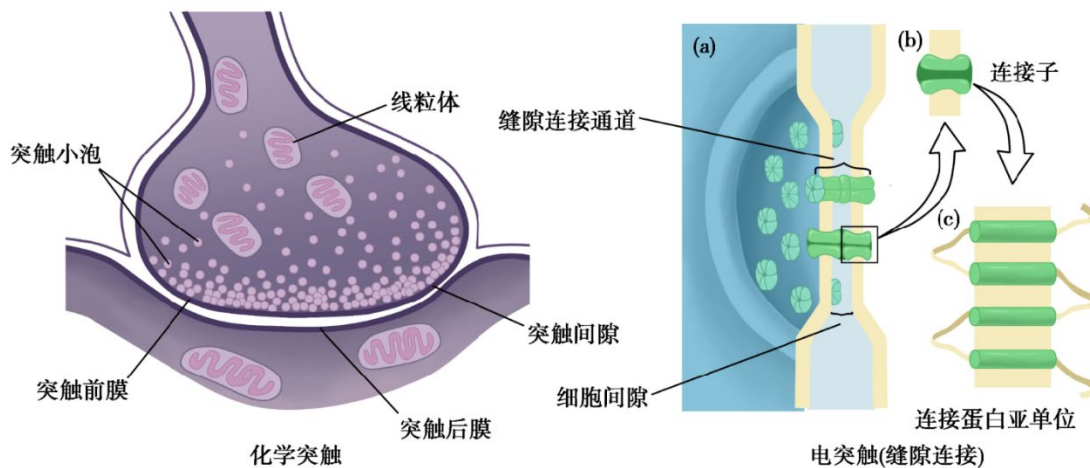
金英杰张伟老师

获取更多医考资料请关注

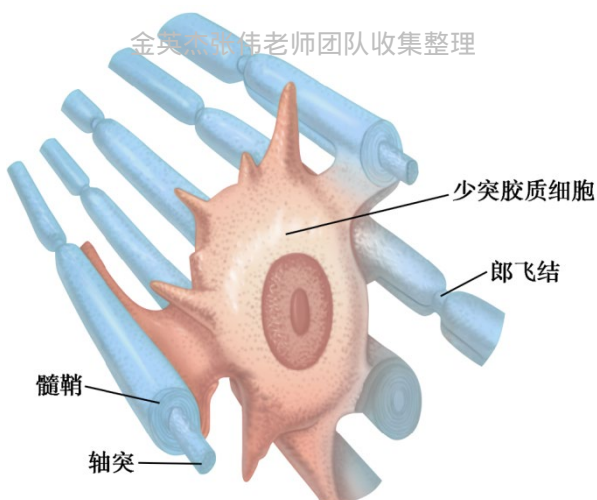




小胶质细胞



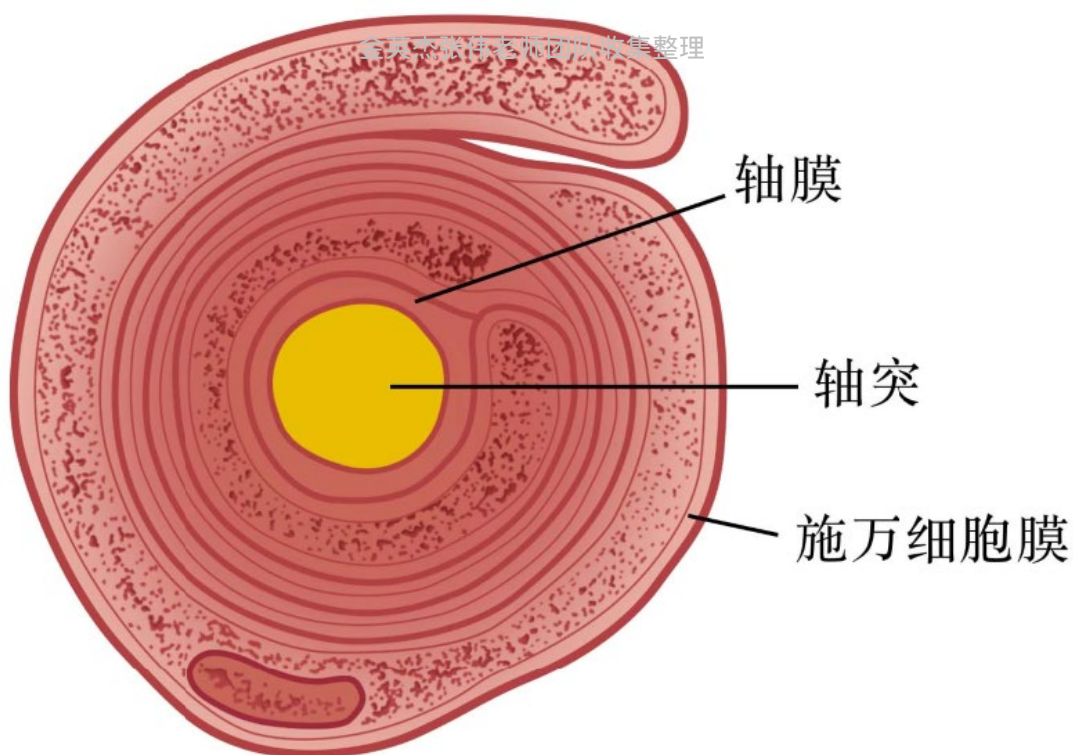
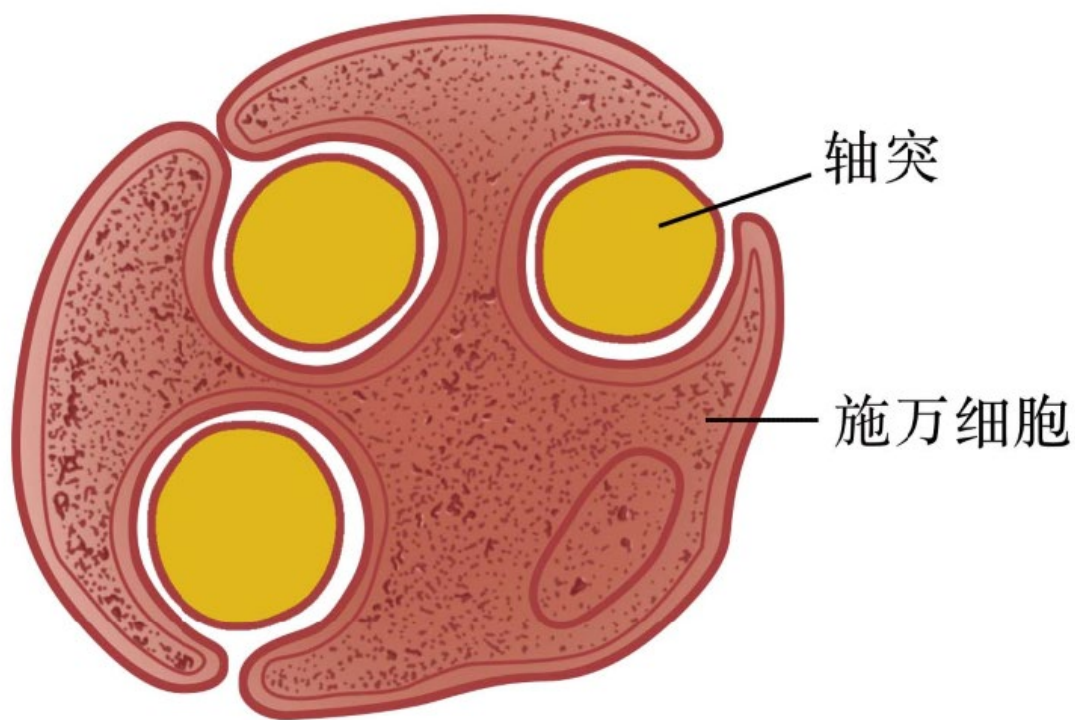
金英杰张伟老师团队收集整理



金英杰张伟老师

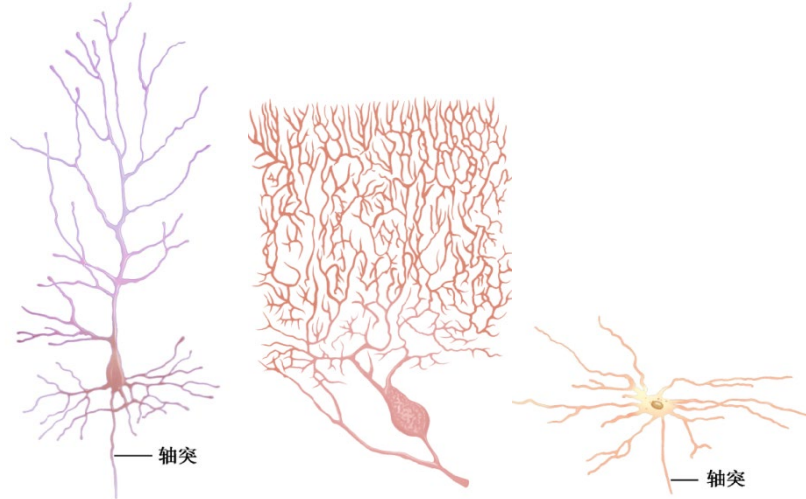
获取更多医考资料请关注






获取更多医考资料请关注





大脑皮质锥体细胞 (多极神经元) 小脑梨状细胞 (多极神经元) 脊髓前角细胞 (多极神经元)



脑干神经细胞 (多极神经元)

嗅细胞 (双极神经元)

脊神经节细胞 (假单极神经元)

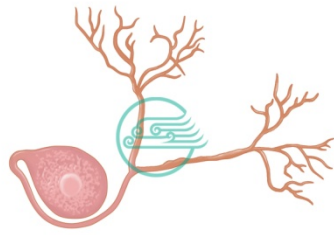
金英杰张伟老师团队收集整理



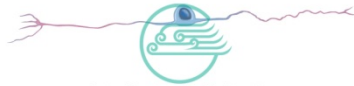金英杰张伟老师

获取更多医考资料请关注

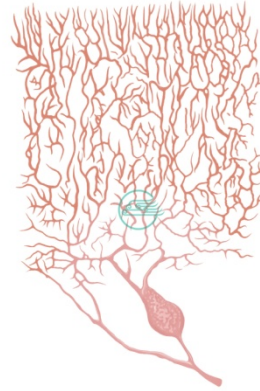



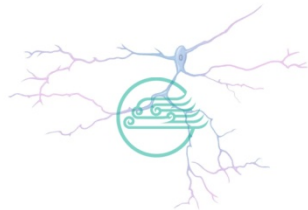脊神经节细胞（假单极神经元）



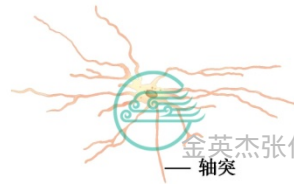
嗅细胞（双极神经元）



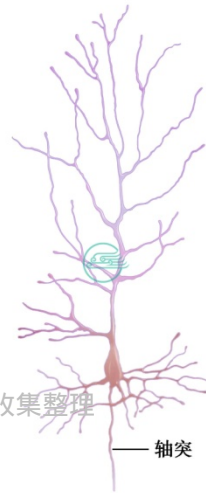
小脑梨状细胞（多级神经元）



脑干神经细胞（多级神经元）



脊髓前角细胞（多级神经元）



大脑皮质锥体细胞（多级神经元）

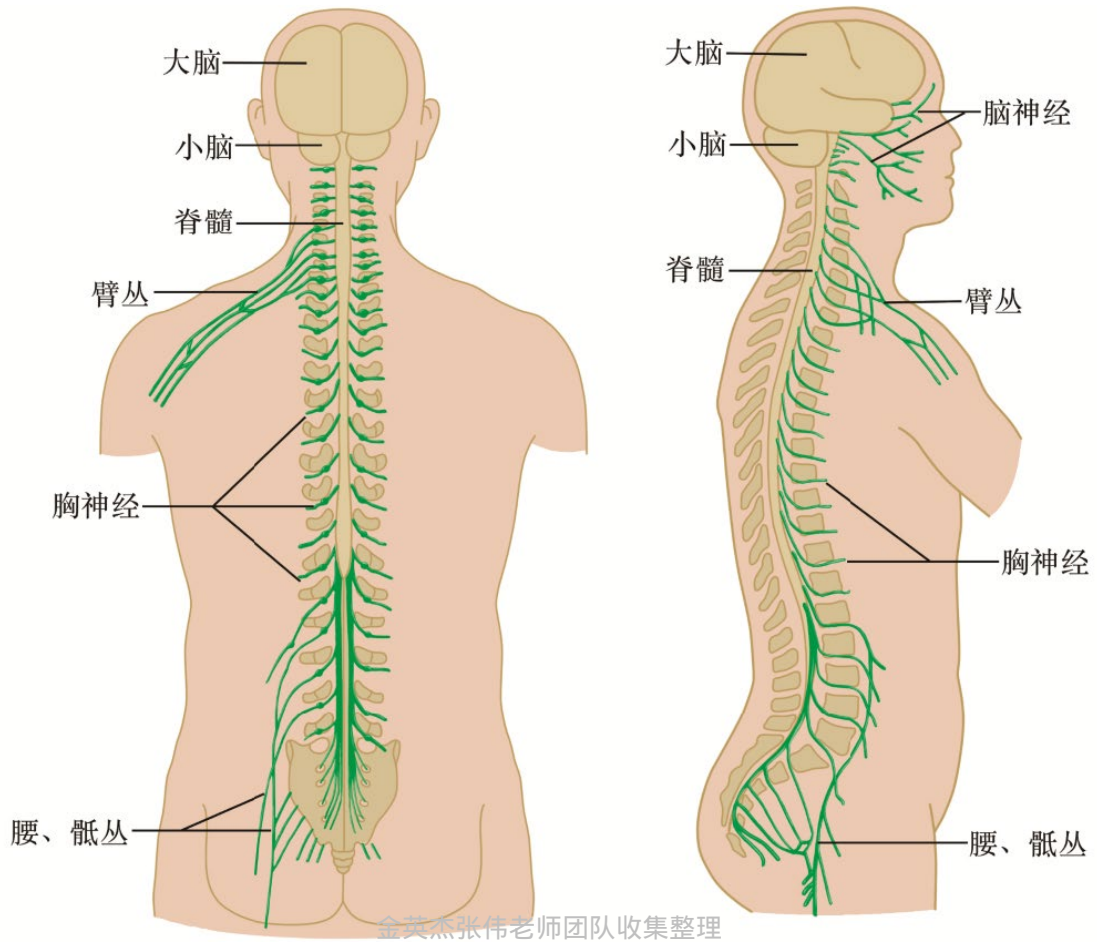
金英杰张伟老师团队收集整理



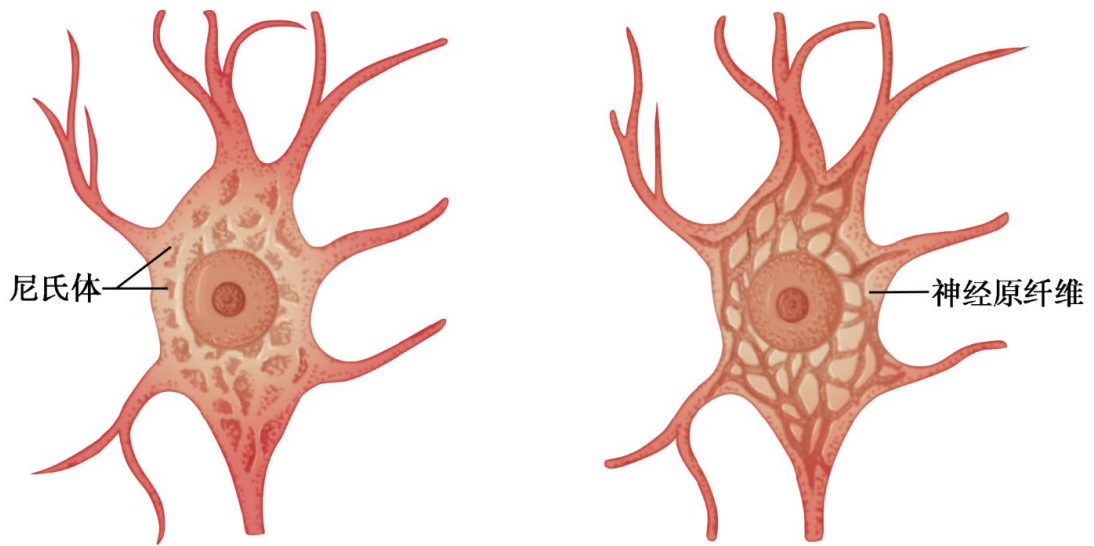
金英杰张伟老师

获取更多医考资料请关注



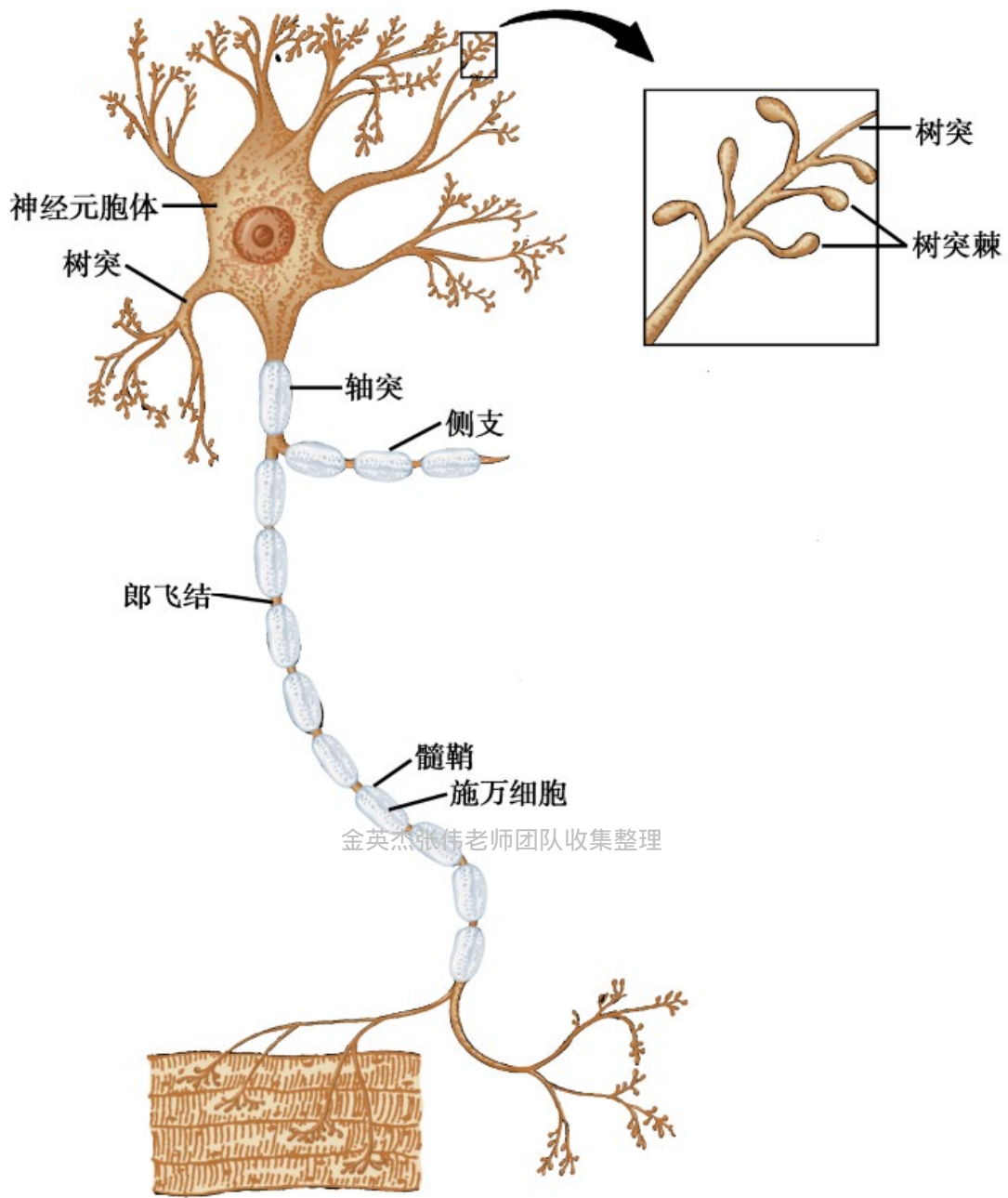


金英杰张伟老师



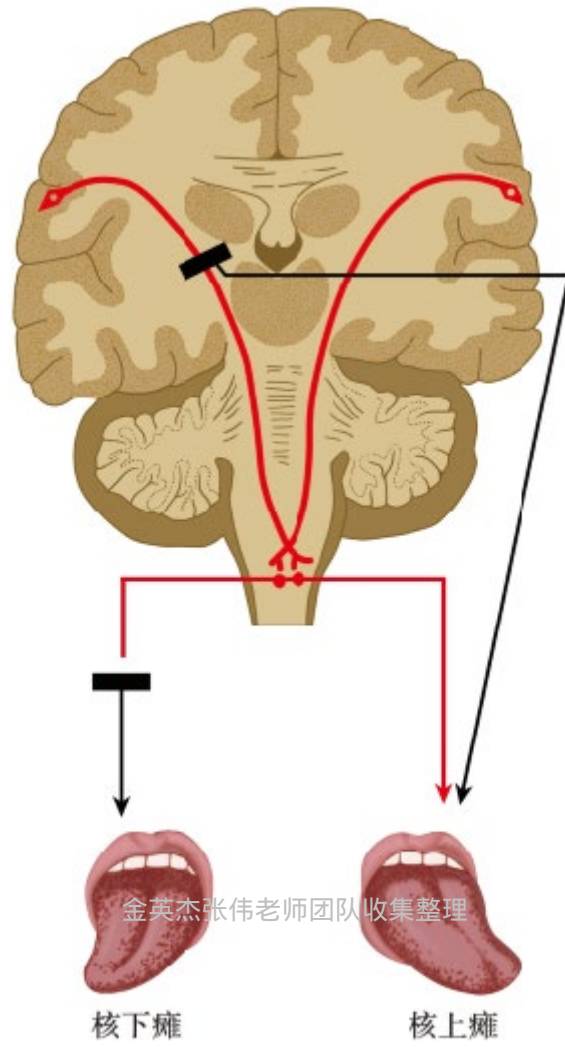
获取更多医考资料请关注





获取更多医考资料请关注





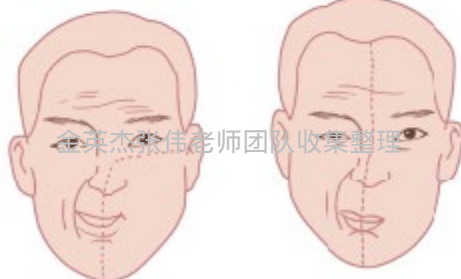
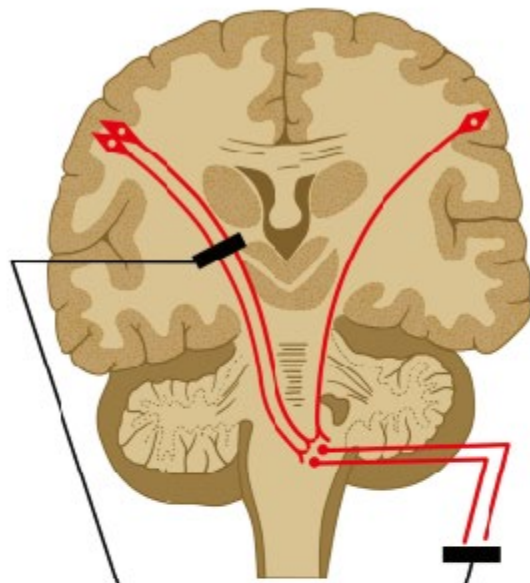
金英杰张伟老师团队收集整理



金英杰张伟老师

获取更多医考资料请关注





核上瘫

核下瘫

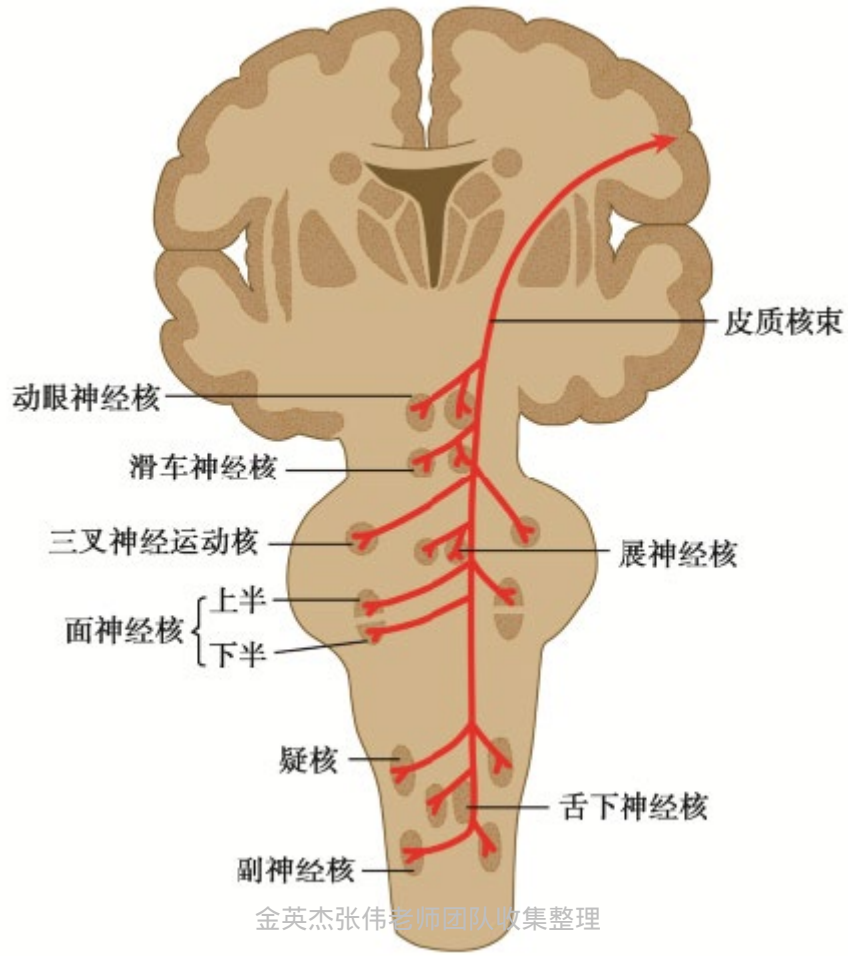
金英杰张伟老师团队收集整理



金英杰张伟老师

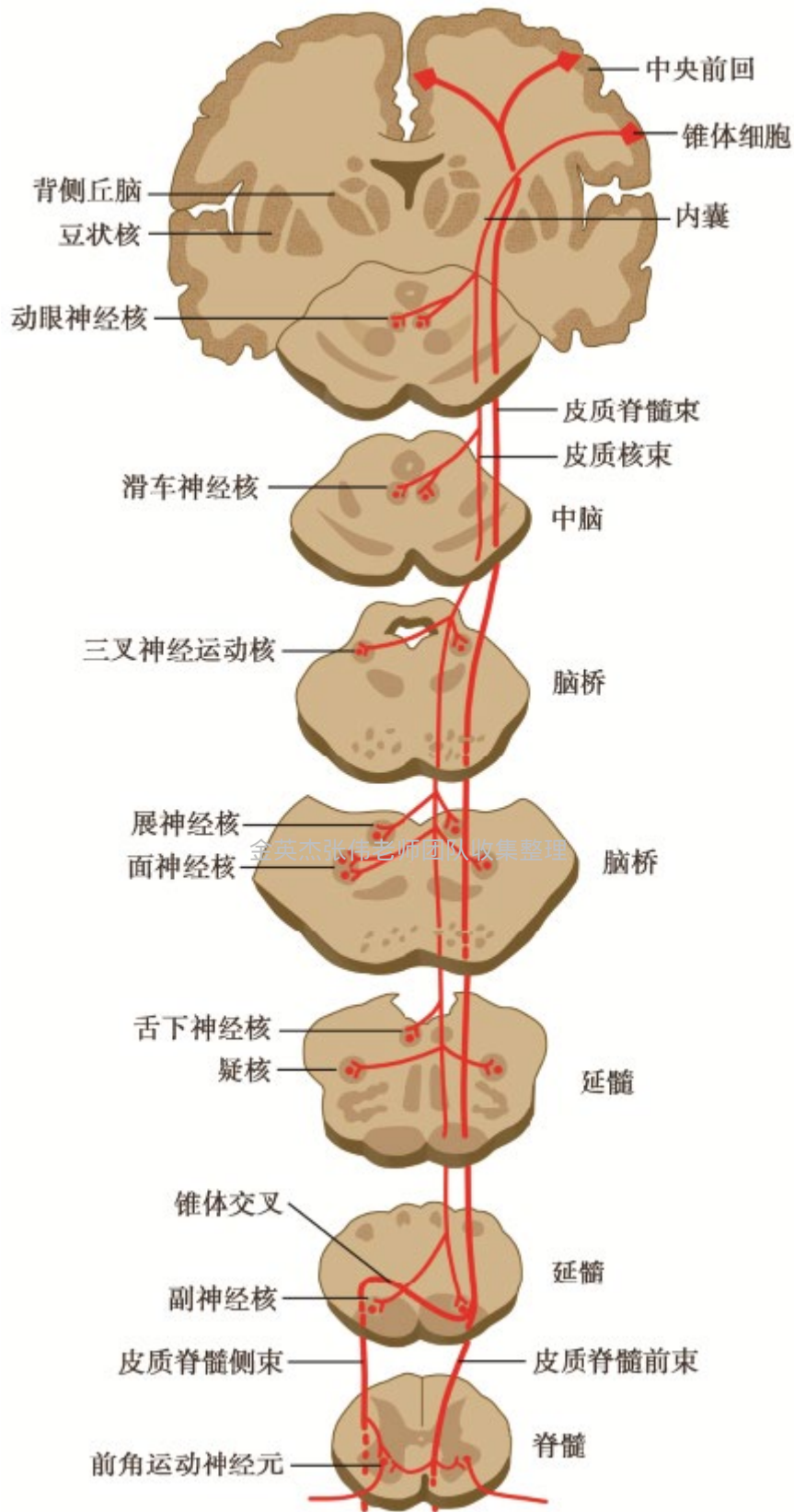
获取更多医考资料请关注





获取更多医考资料请关注

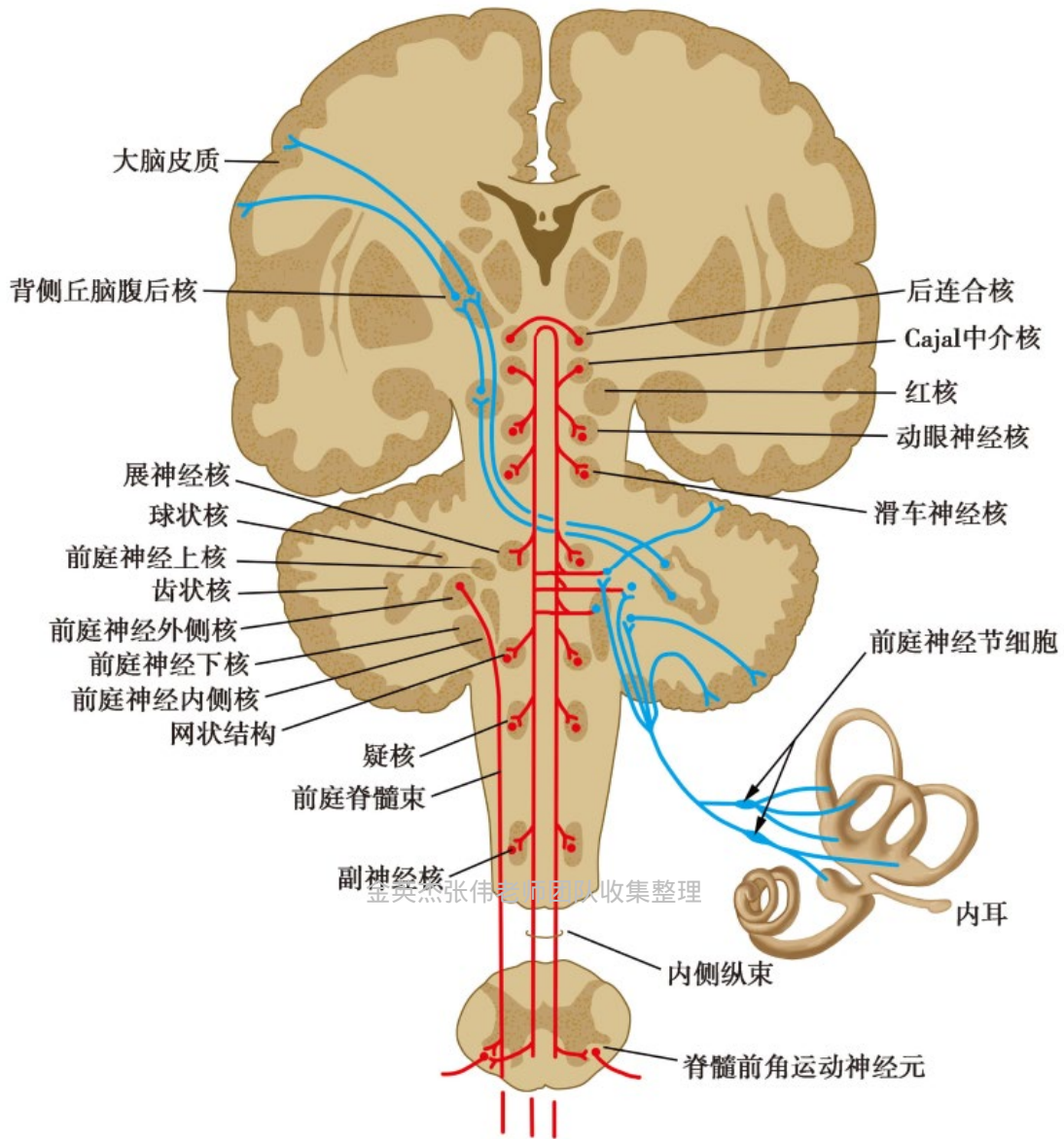




金英杰张伟老师

获取更多医考资料请关注





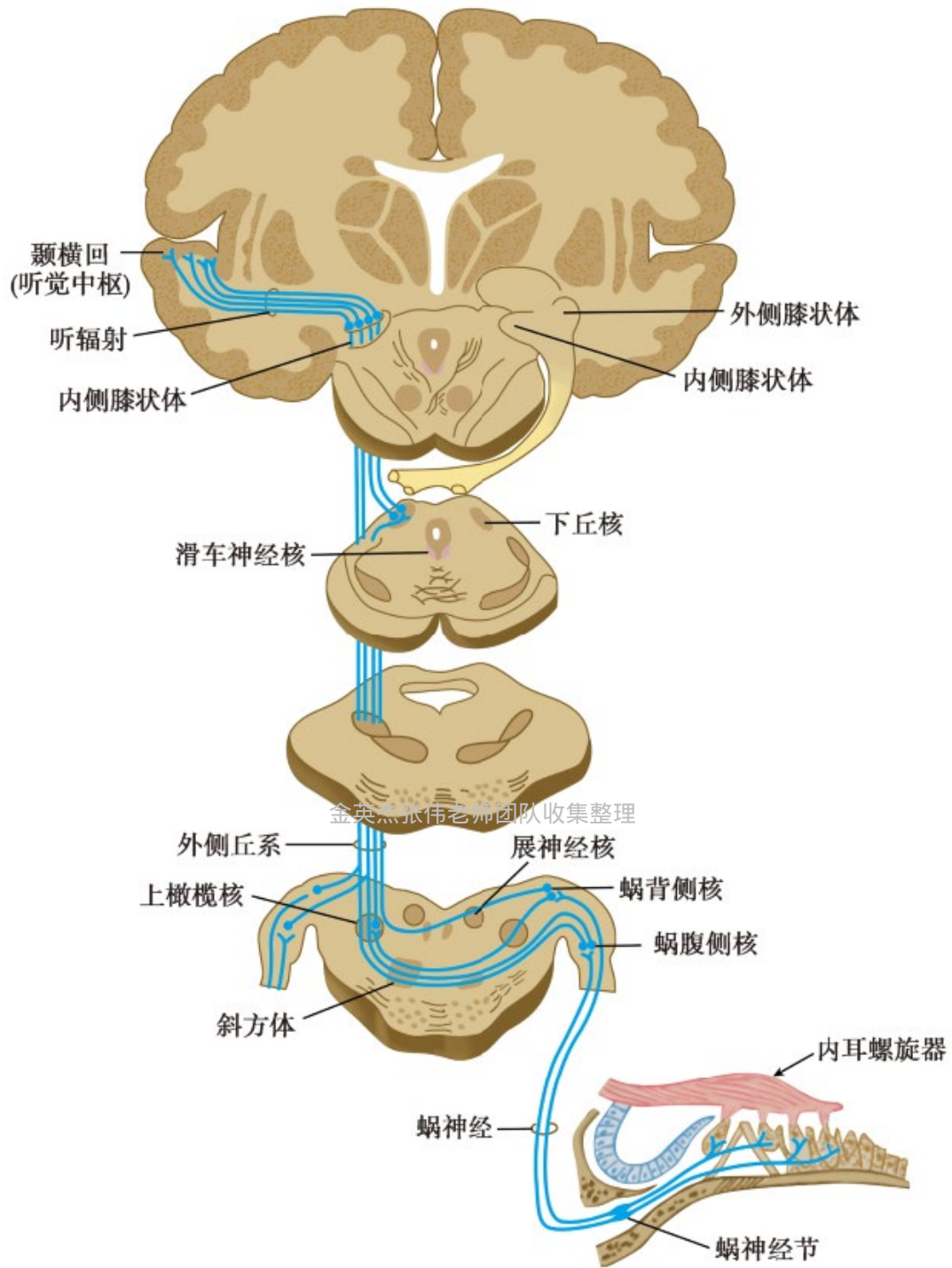
金英杰张伟老师团队收集整理



金英杰张伟老师

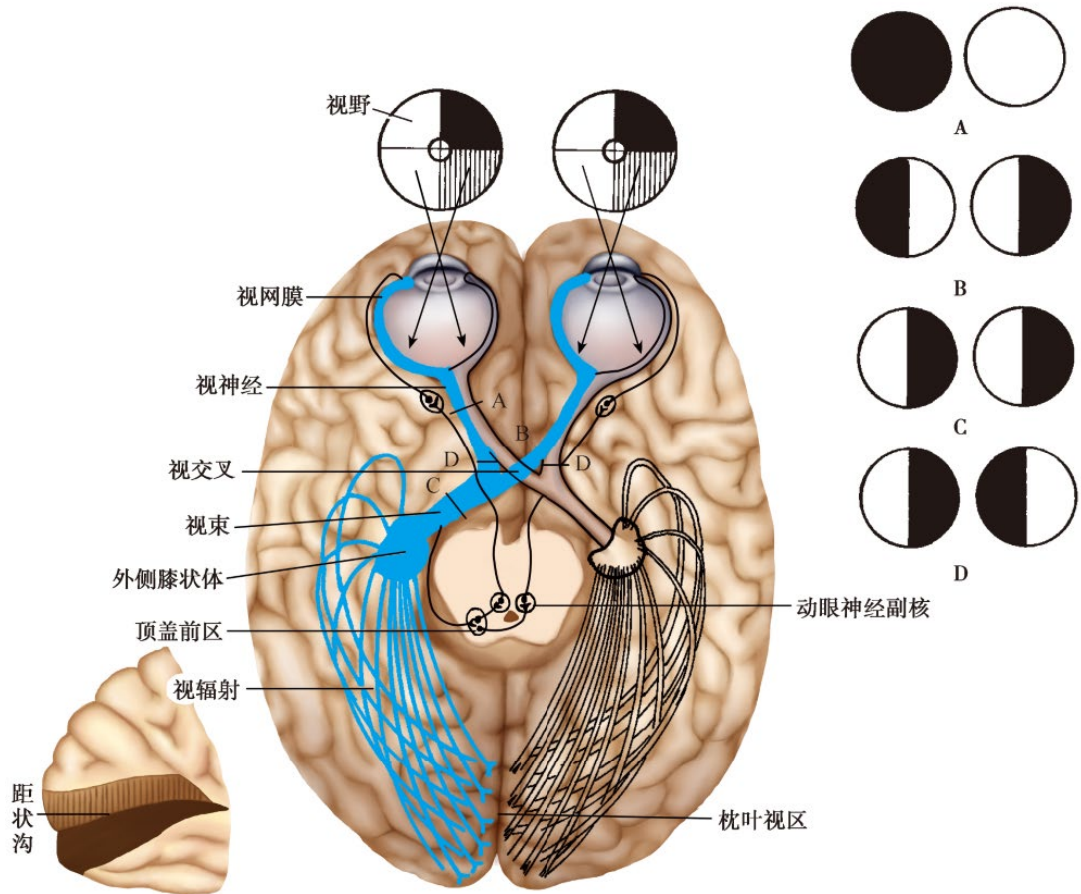
获取更多医考资料请关注





获取更多医考资料请关注





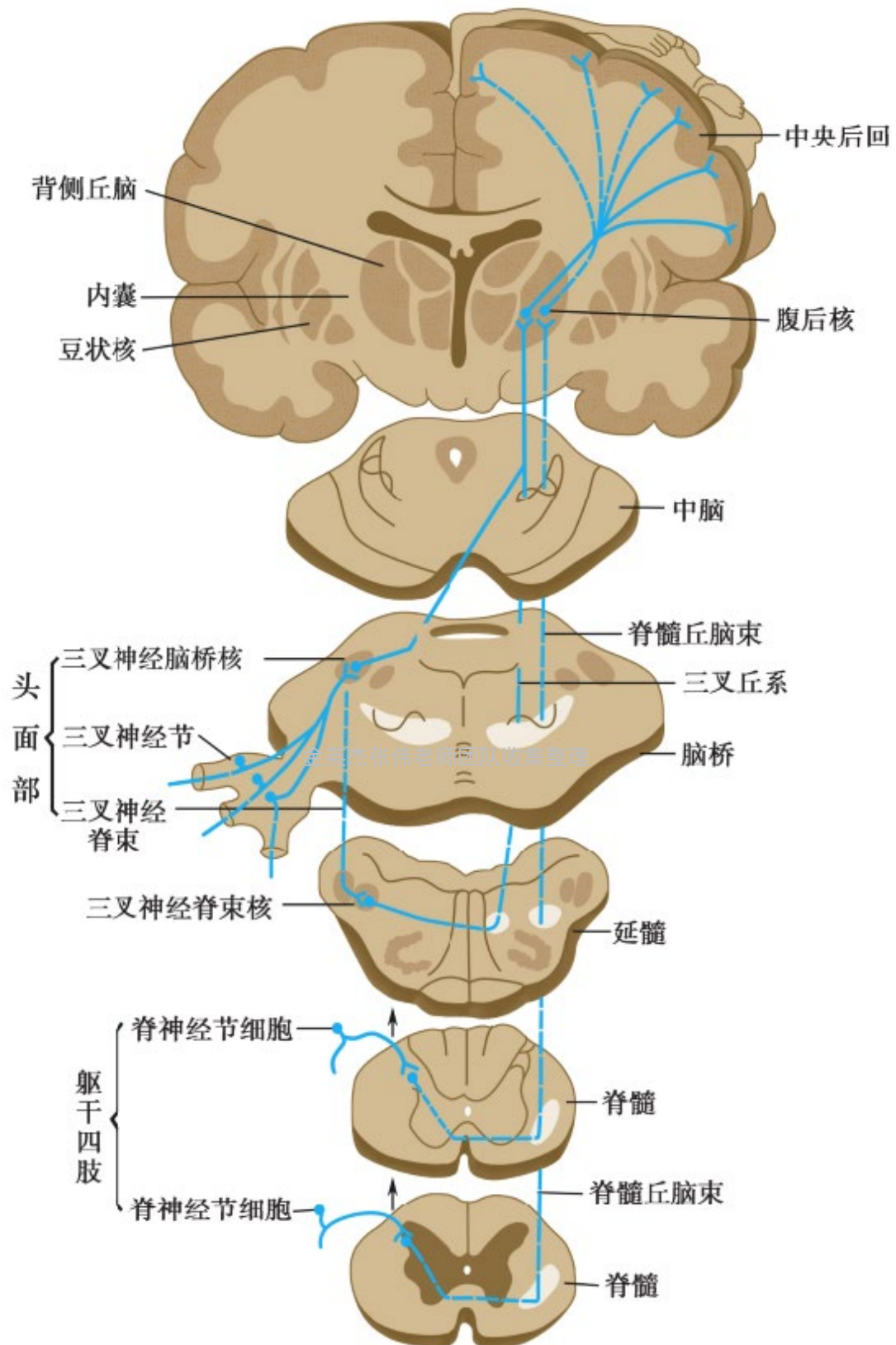
金英杰张伟老师团队收集整理



金英杰张伟老师

获取更多医考资料请关注

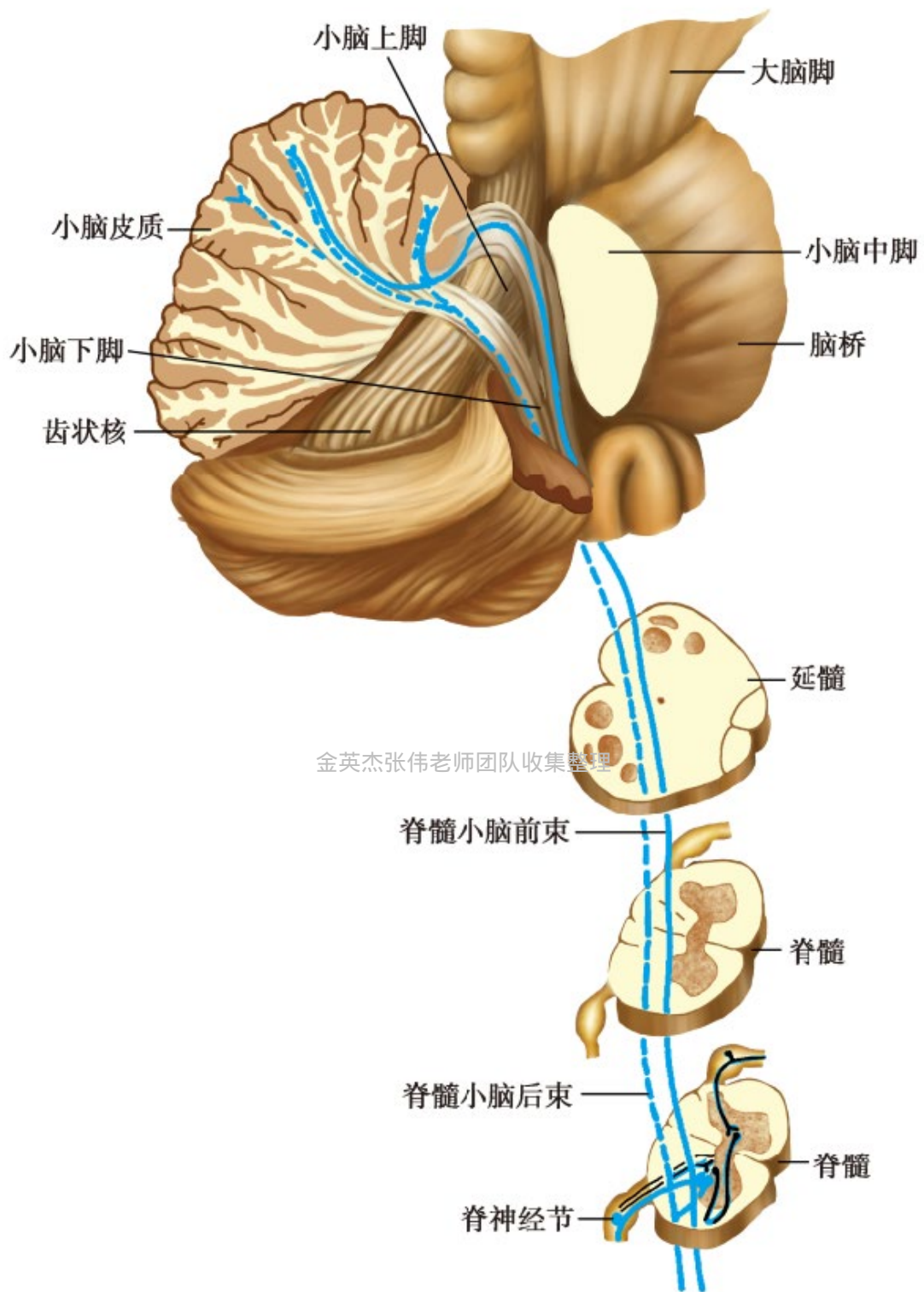




金英杰张伟老师

获取更多医考资料请关注





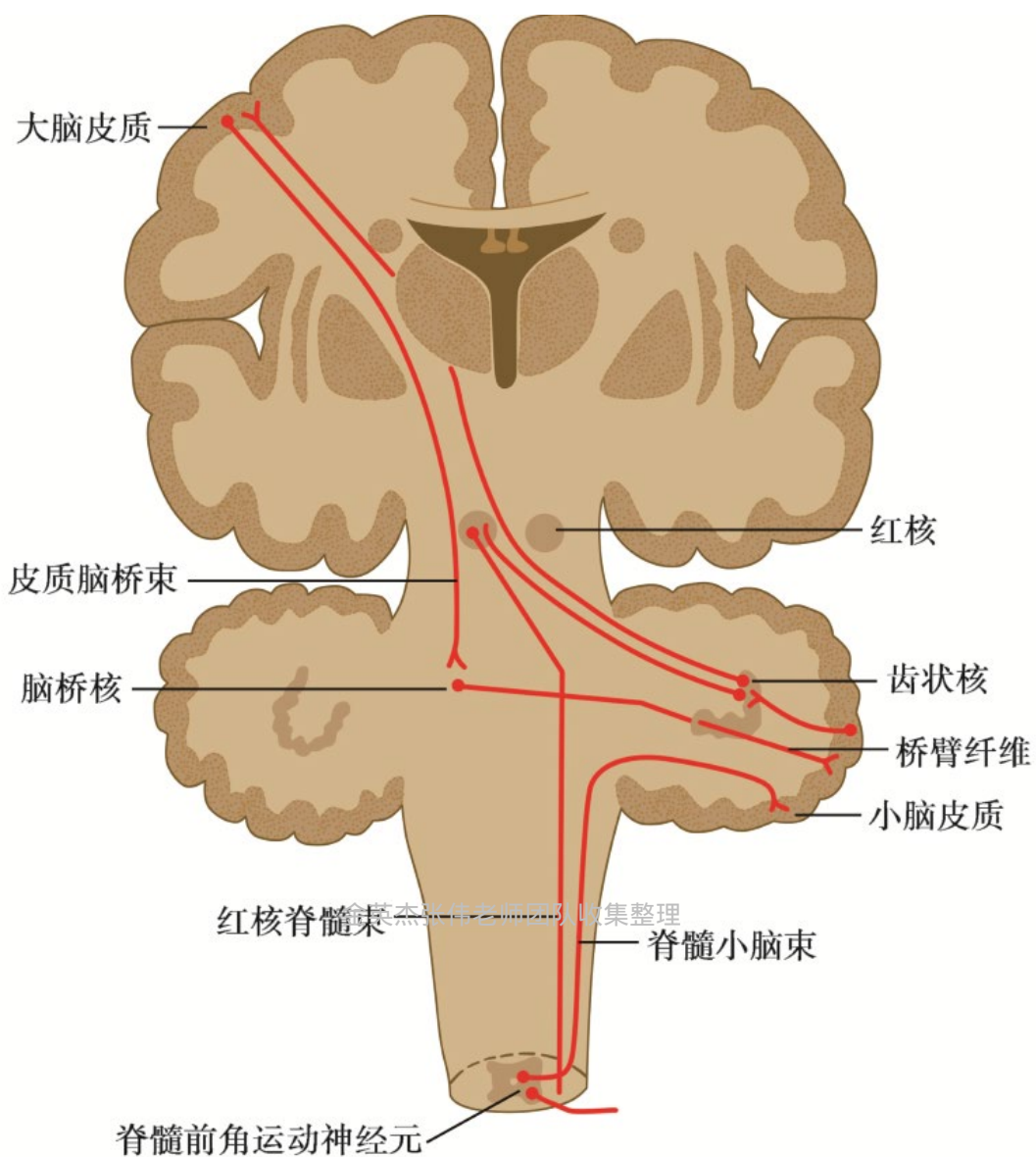
金英杰张伟老师团队收集整理



金英杰张伟老师

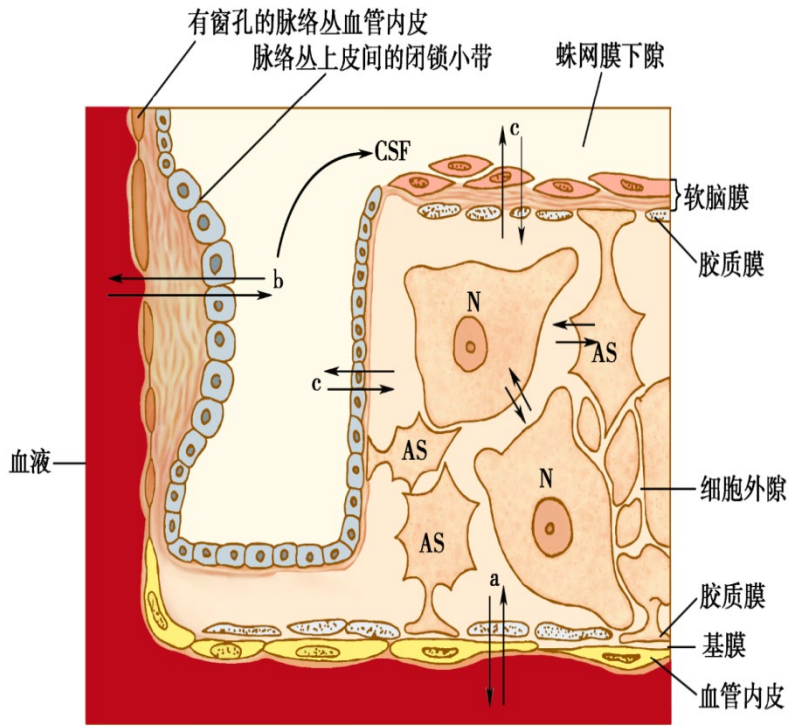
获取更多医考资料请关注





获取更多医考资料请关注



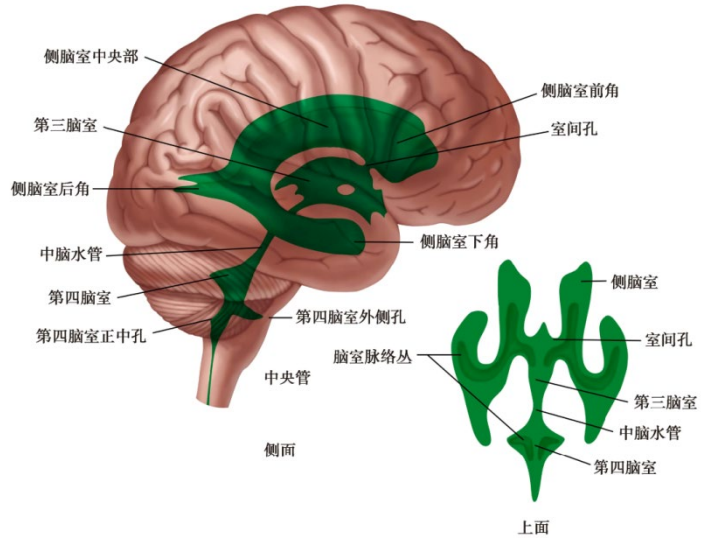
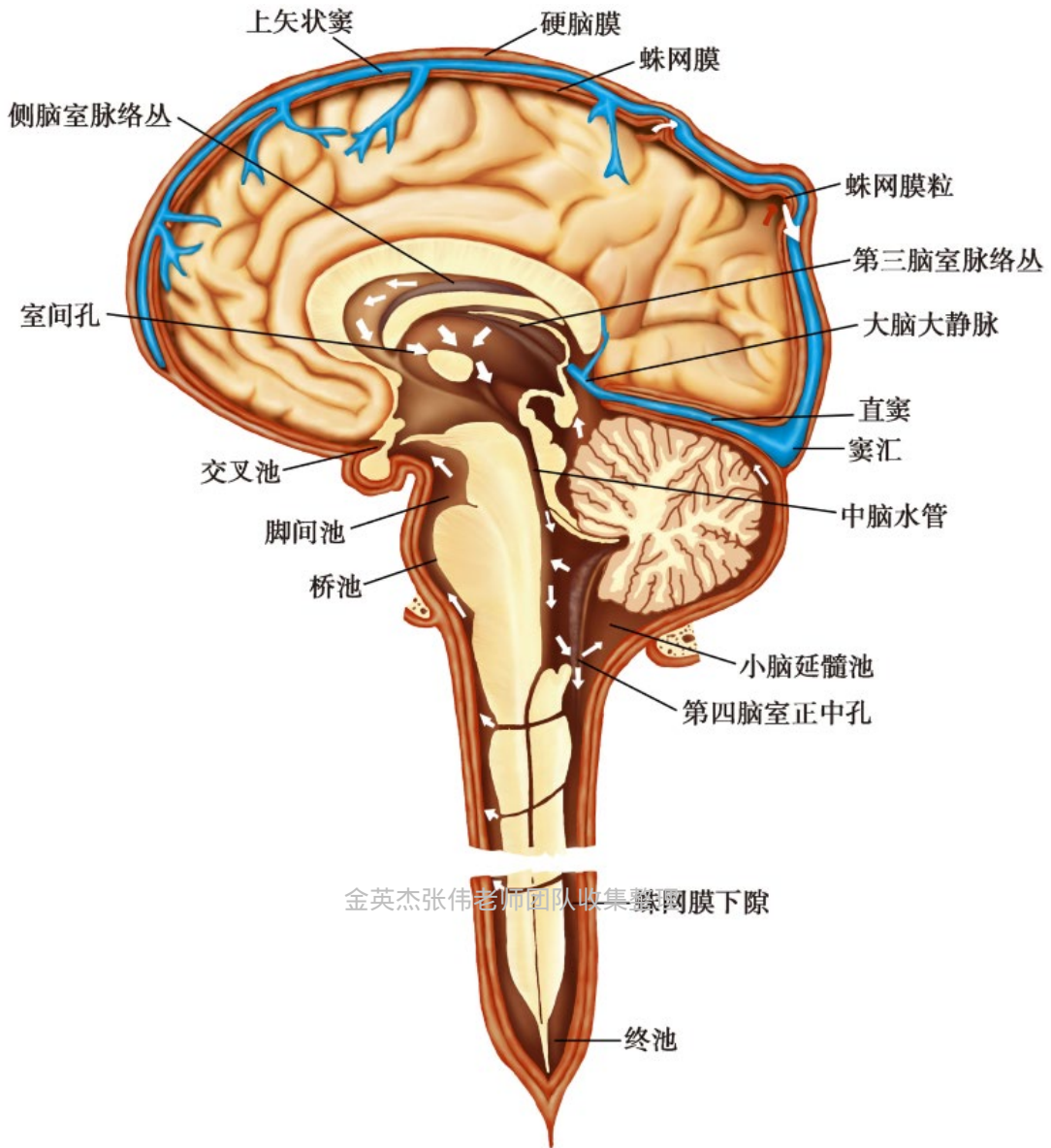


金英杰张伟老师团队收集整理



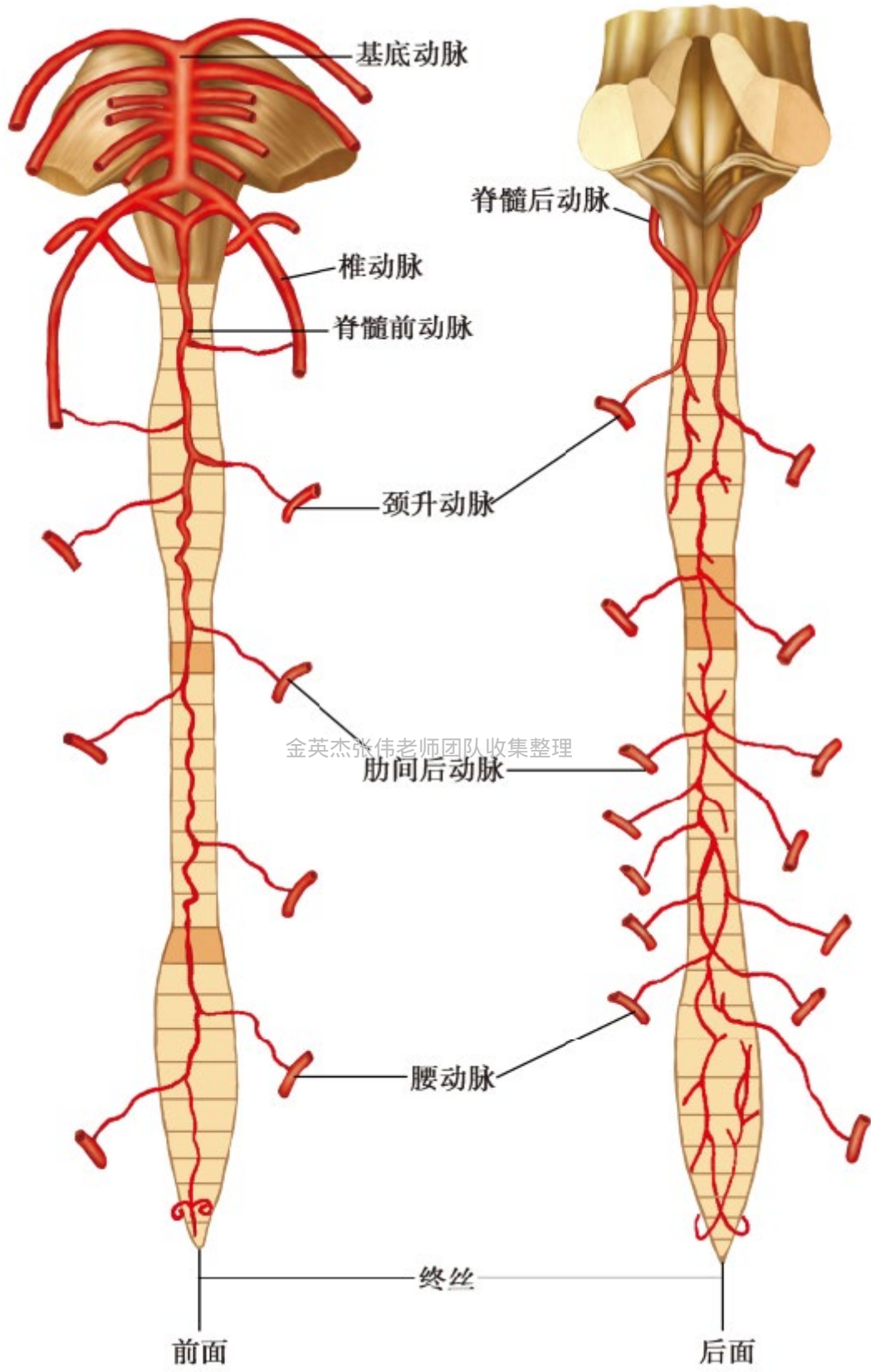
获取更多医考资料请关注





获取更多医考资料请关注



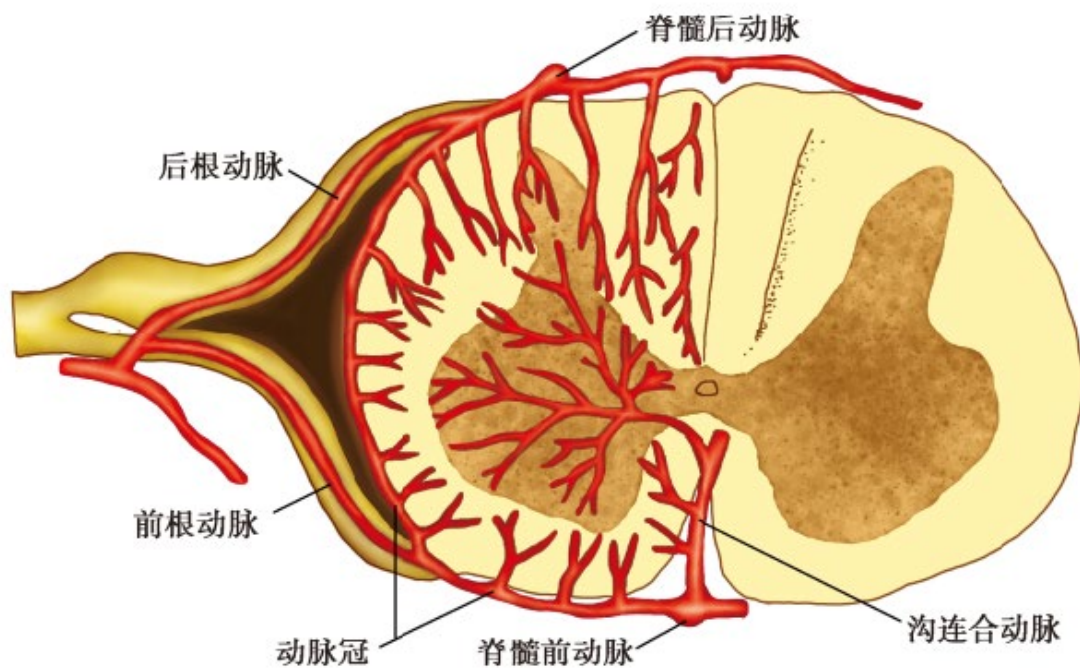


金英杰张伟老师团队收集整理



获取更多医考资料请关注



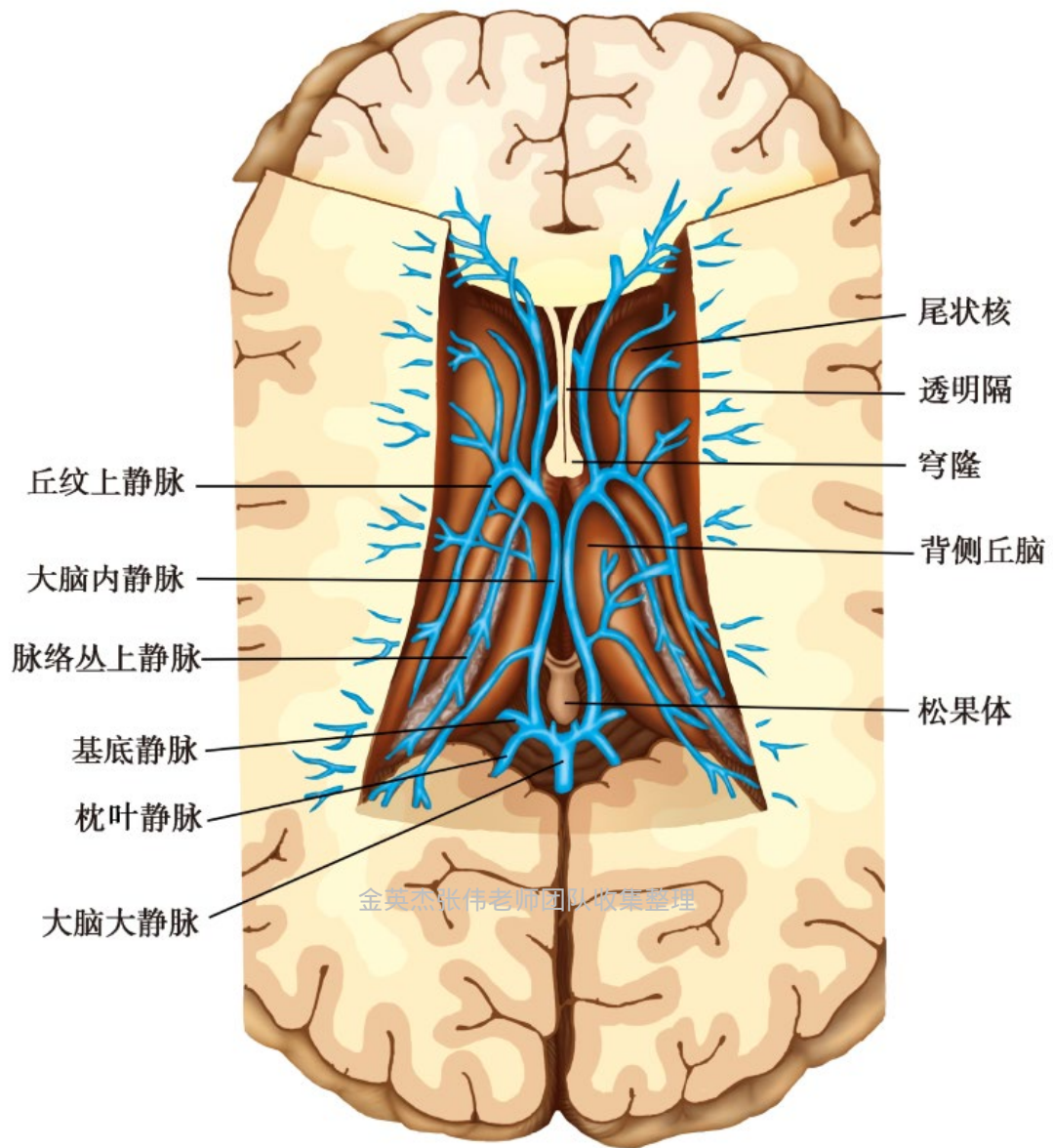


金英杰张伟老师团队收集整理



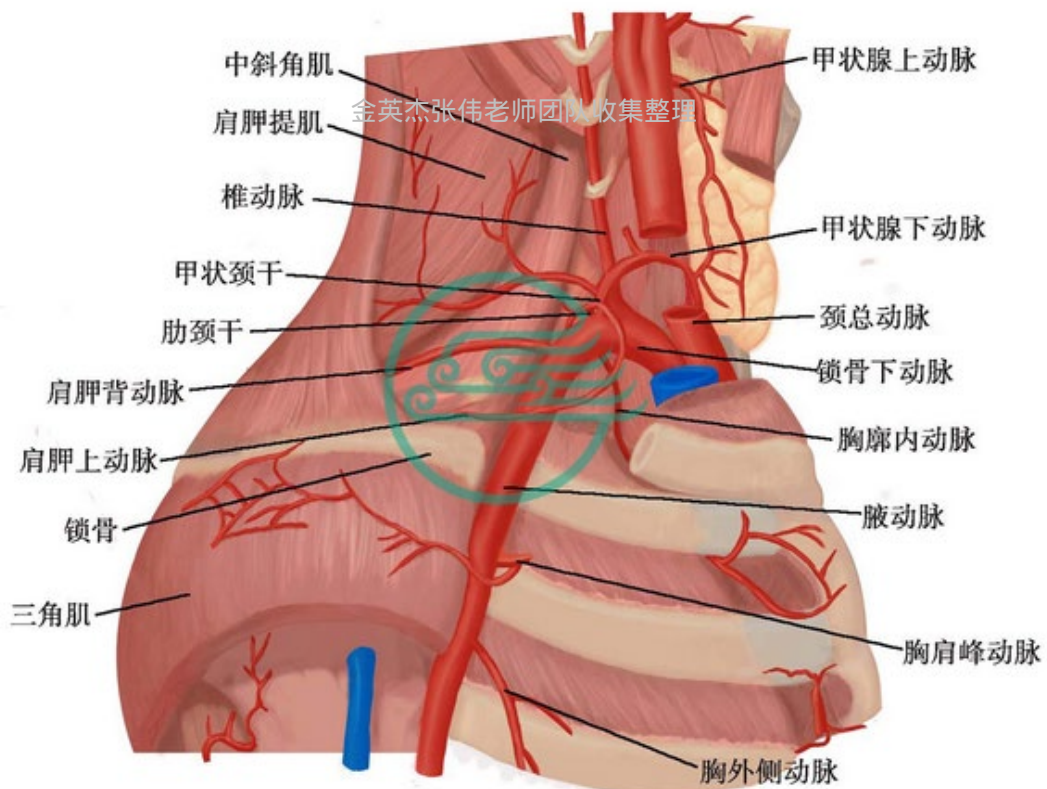
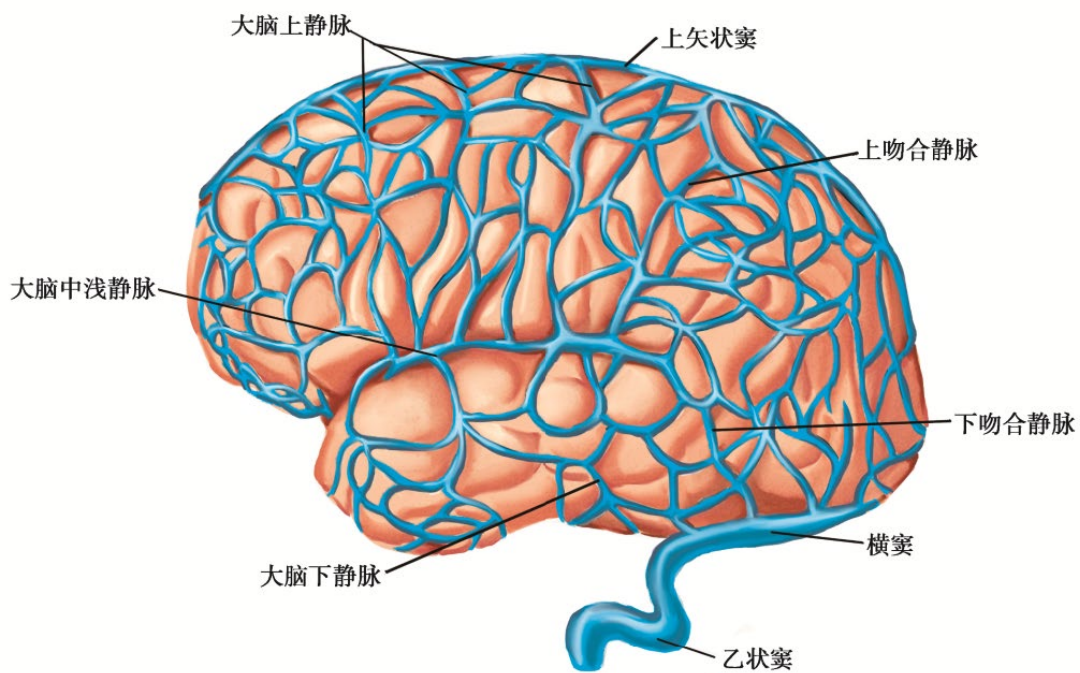
获取更多医考资料请关注





获取更多医考资料请关注

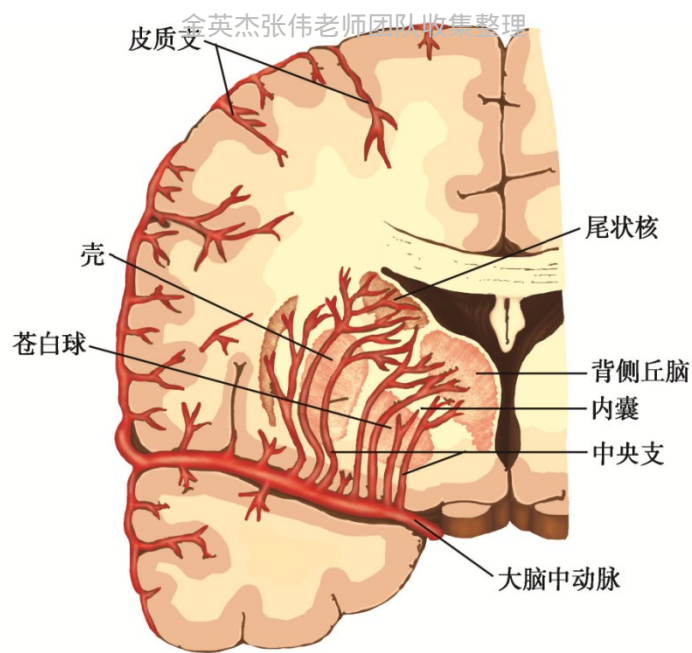
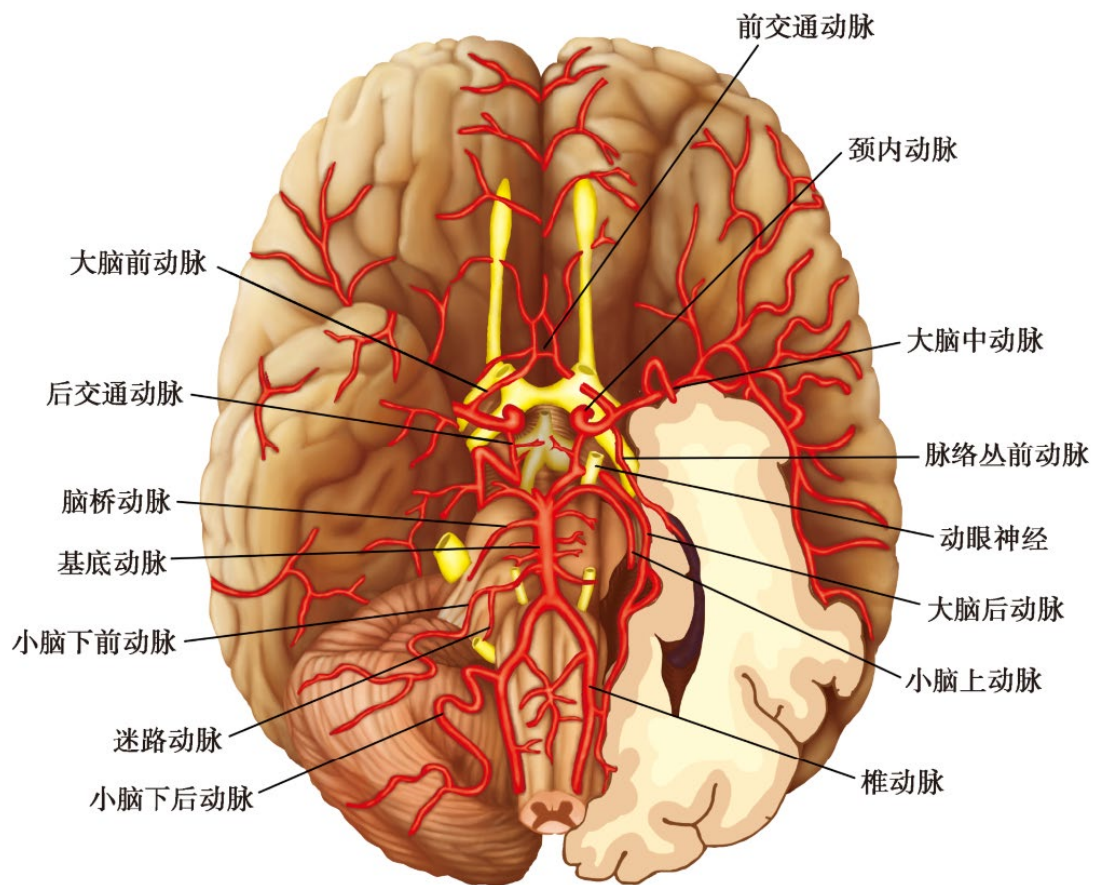




金英杰张伟老师

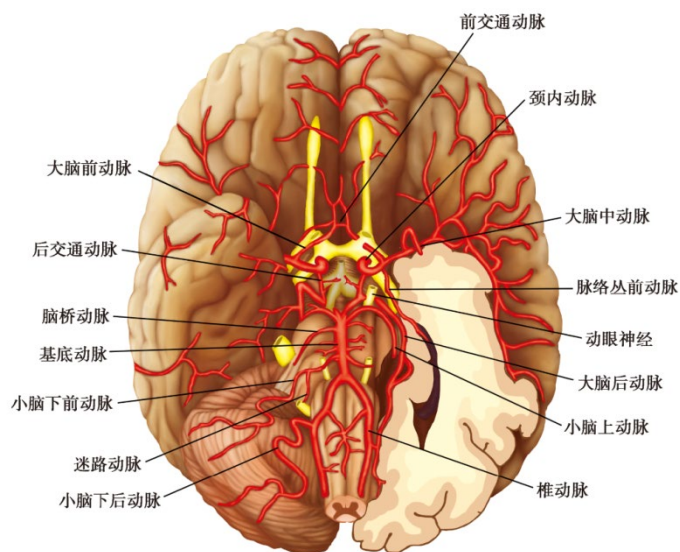
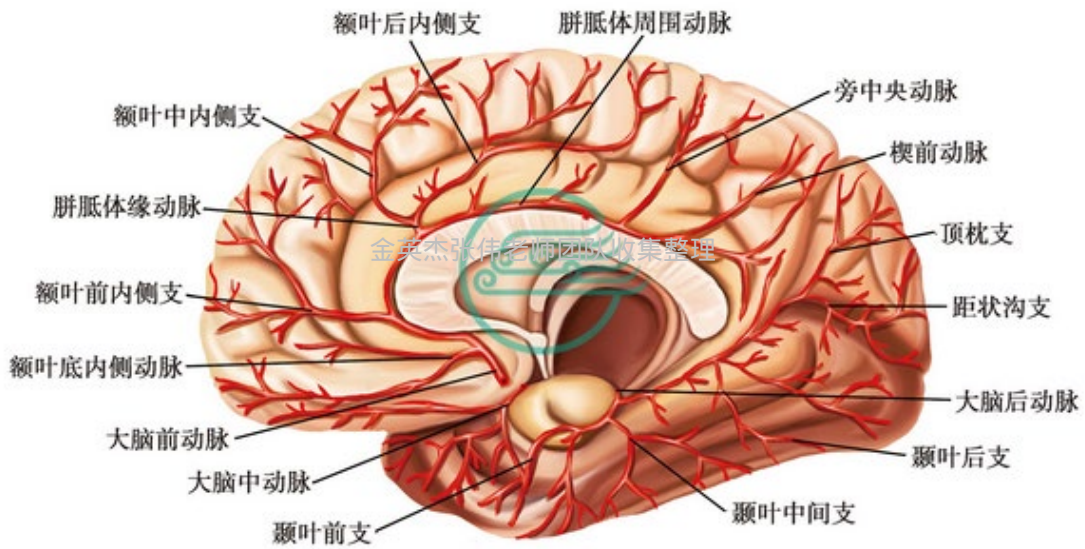
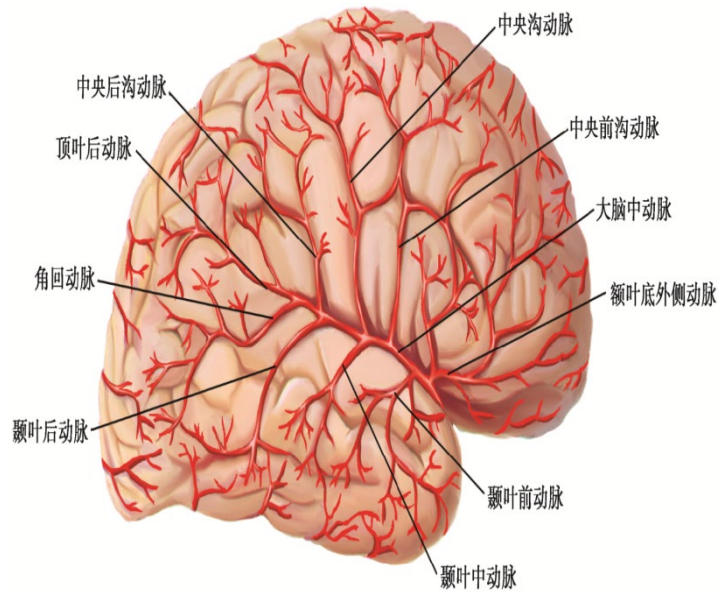
获取更多医考资料请关注





获取更多医考资料请关注

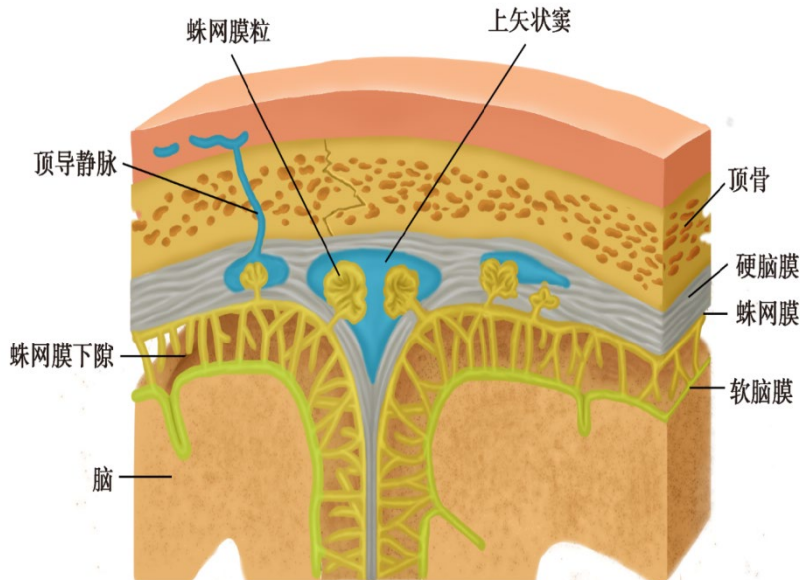
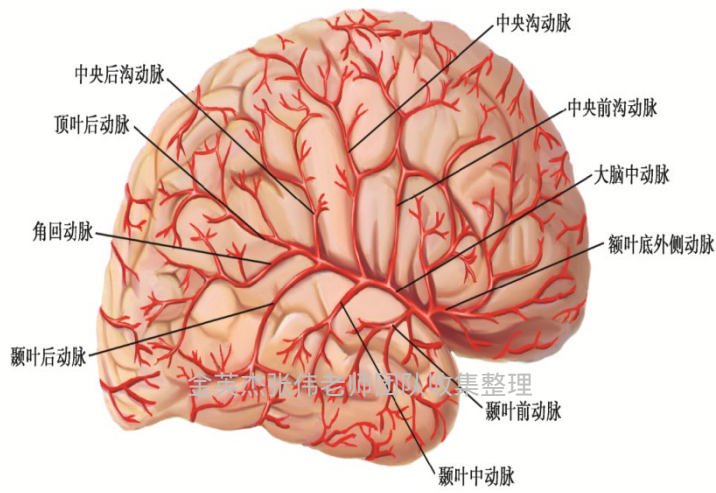
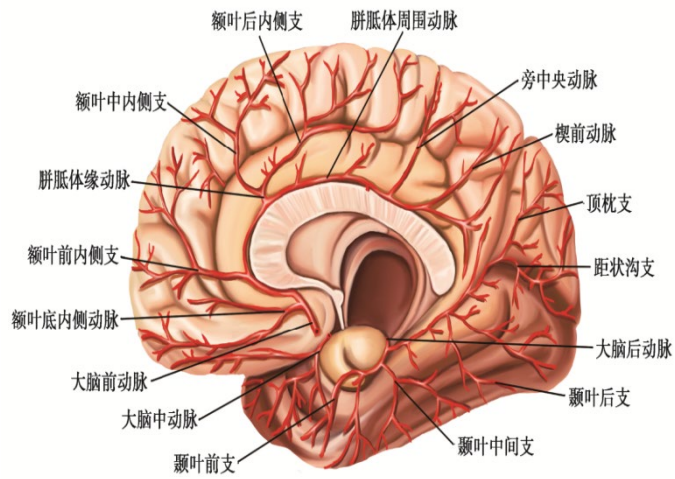




金英杰张伟老师

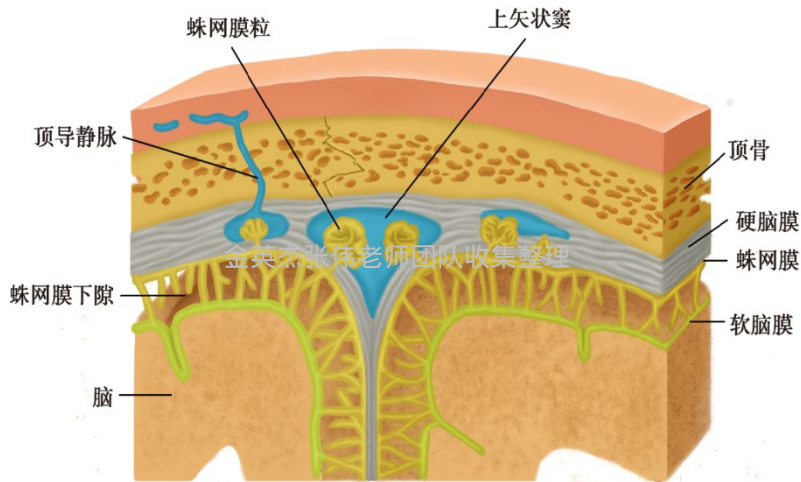
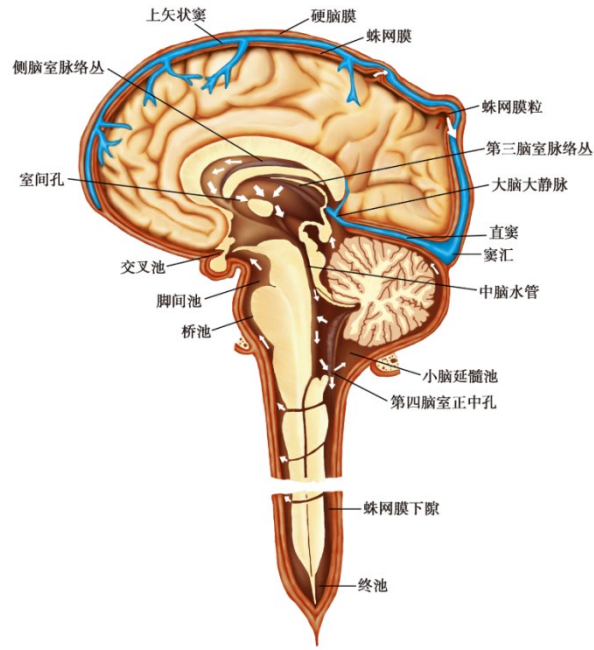
获取更多医考资料请关注





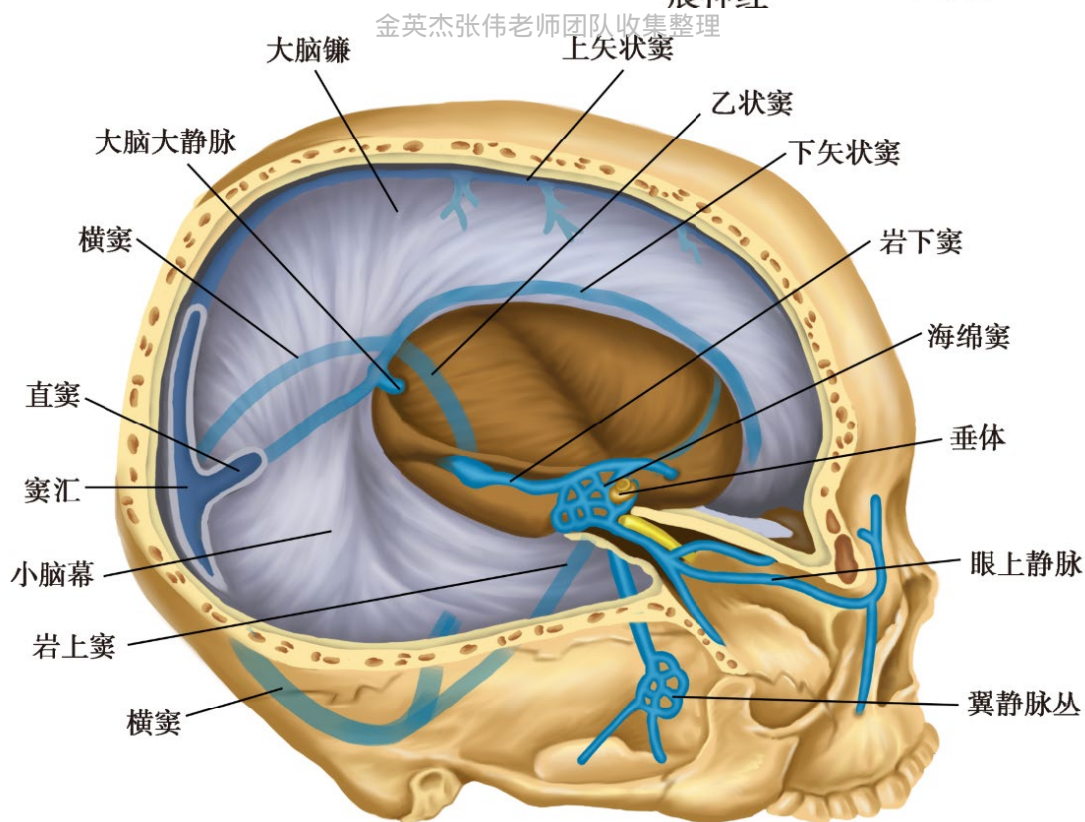
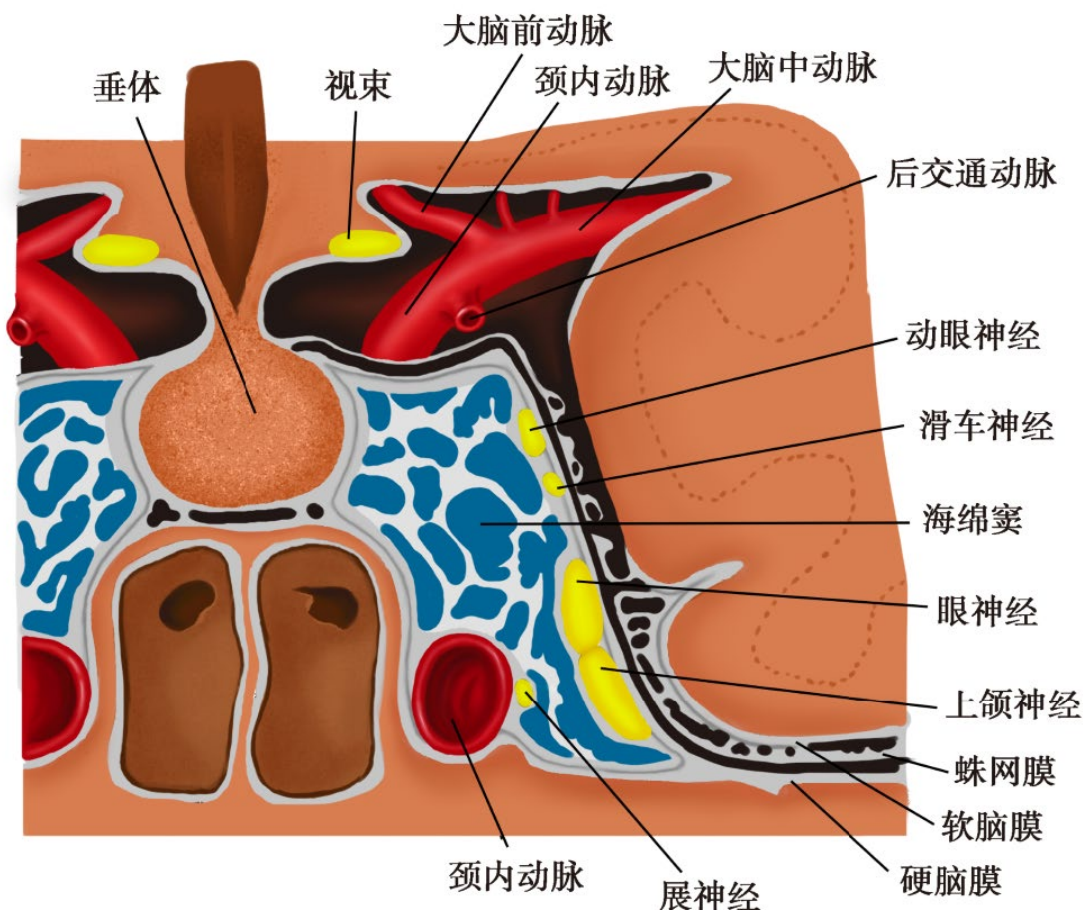
获取更多医考资料请关注





获取更多医考资料请关注



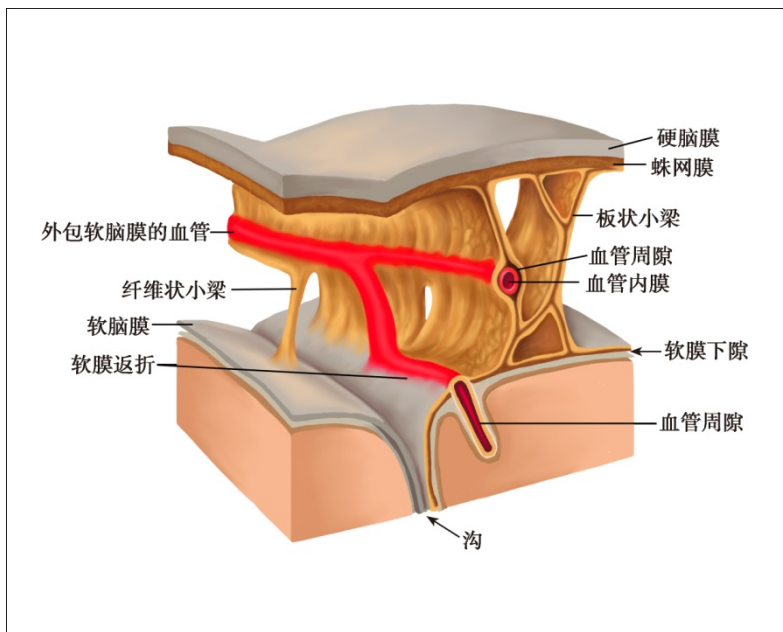
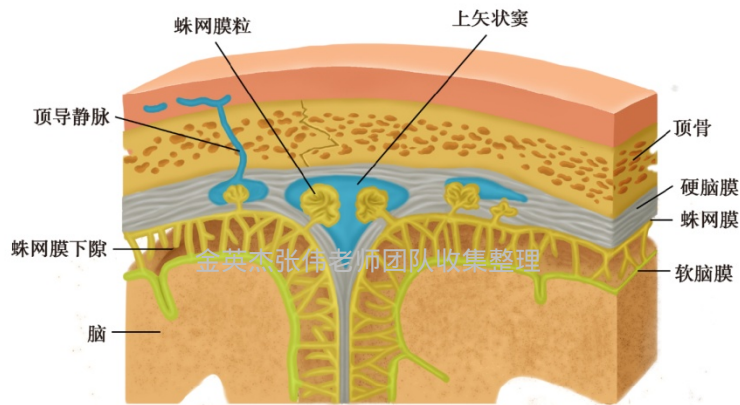
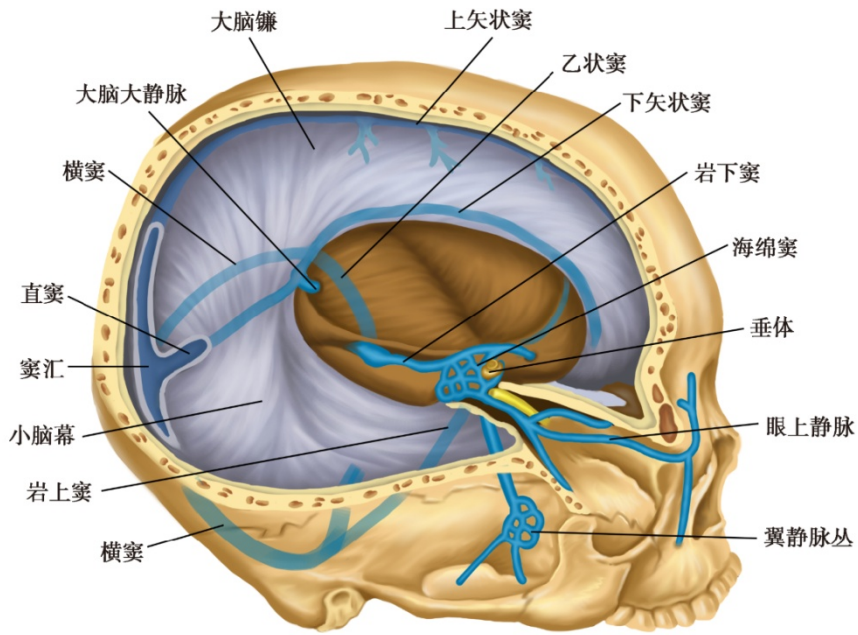


金英杰张伟老师团队收集整理



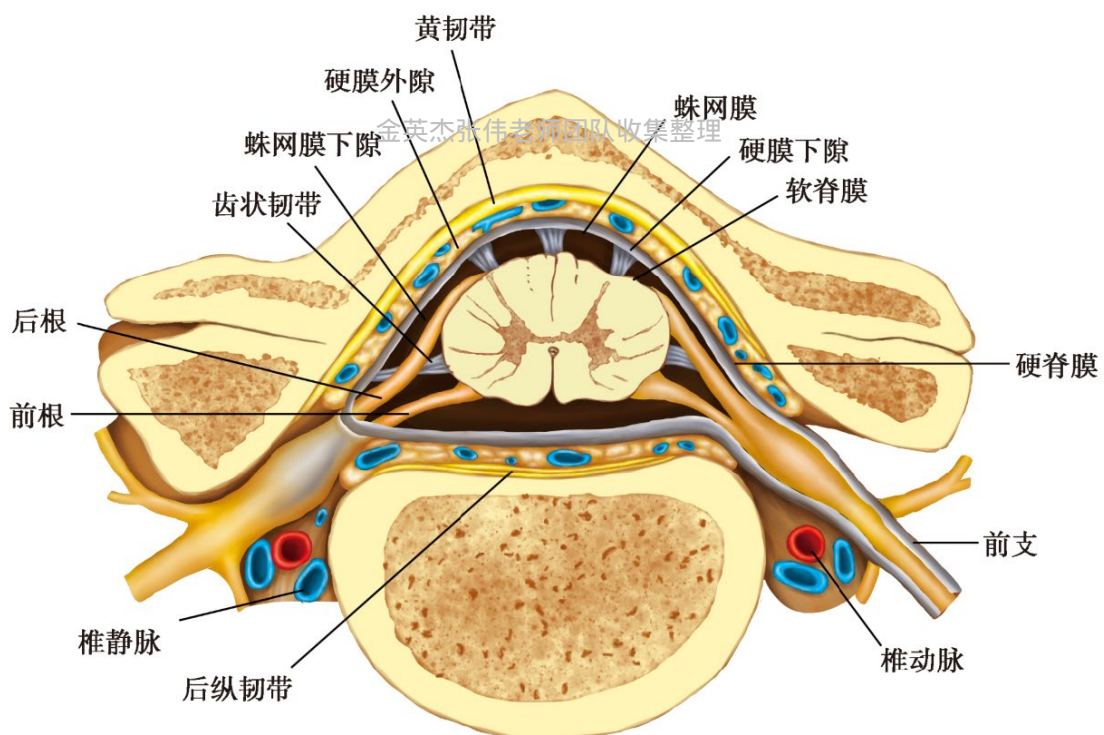
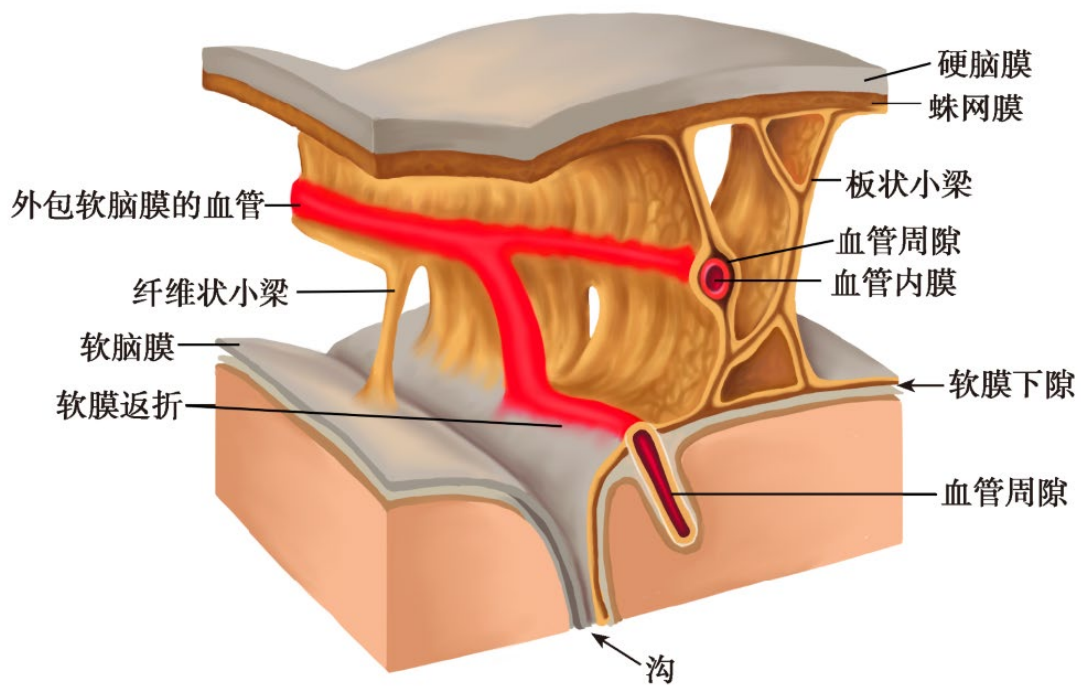
获取更多医考资料请关注





获取更多医考资料请关注

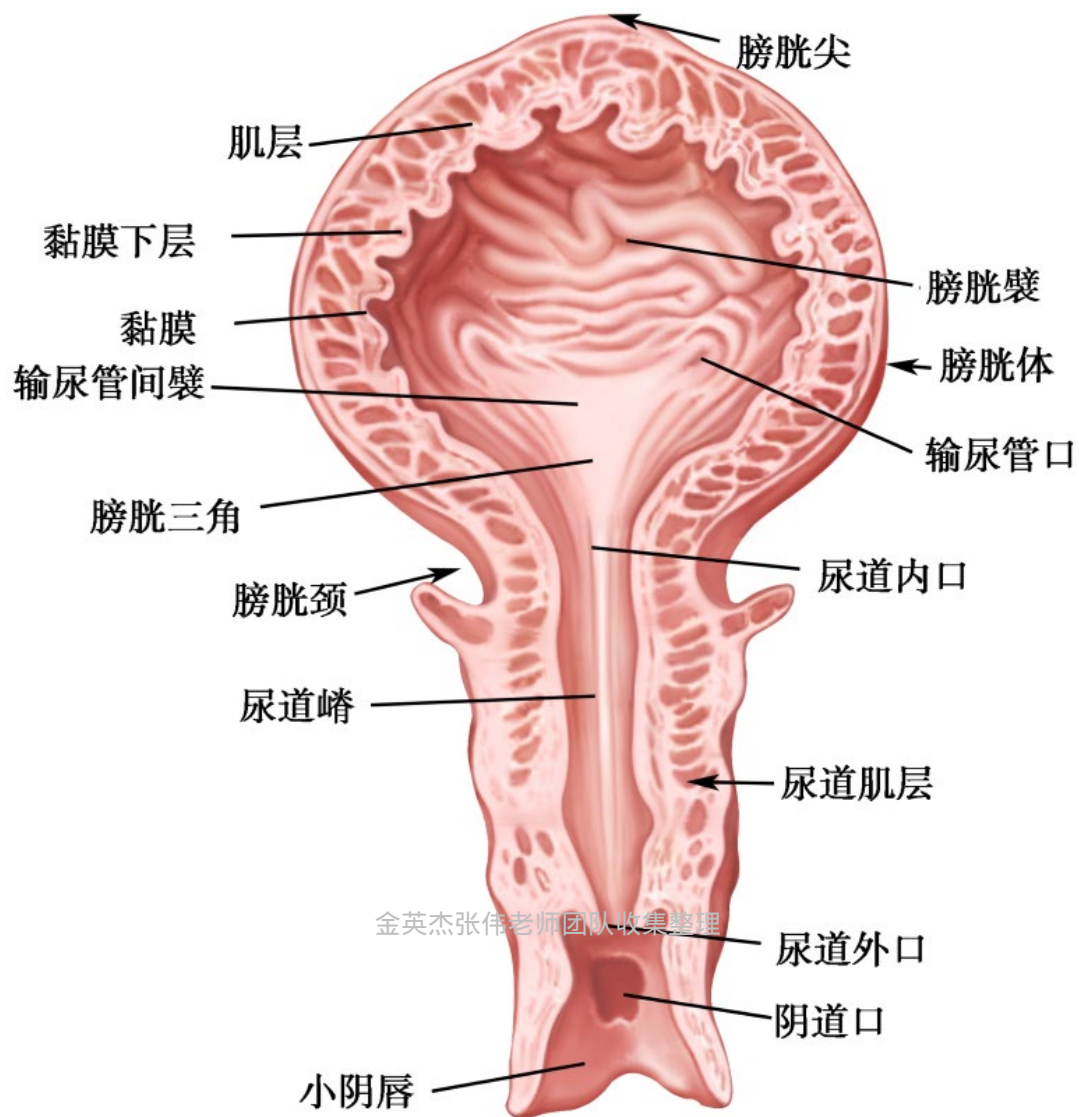




泌尿系统

获取更多医考资料请关注





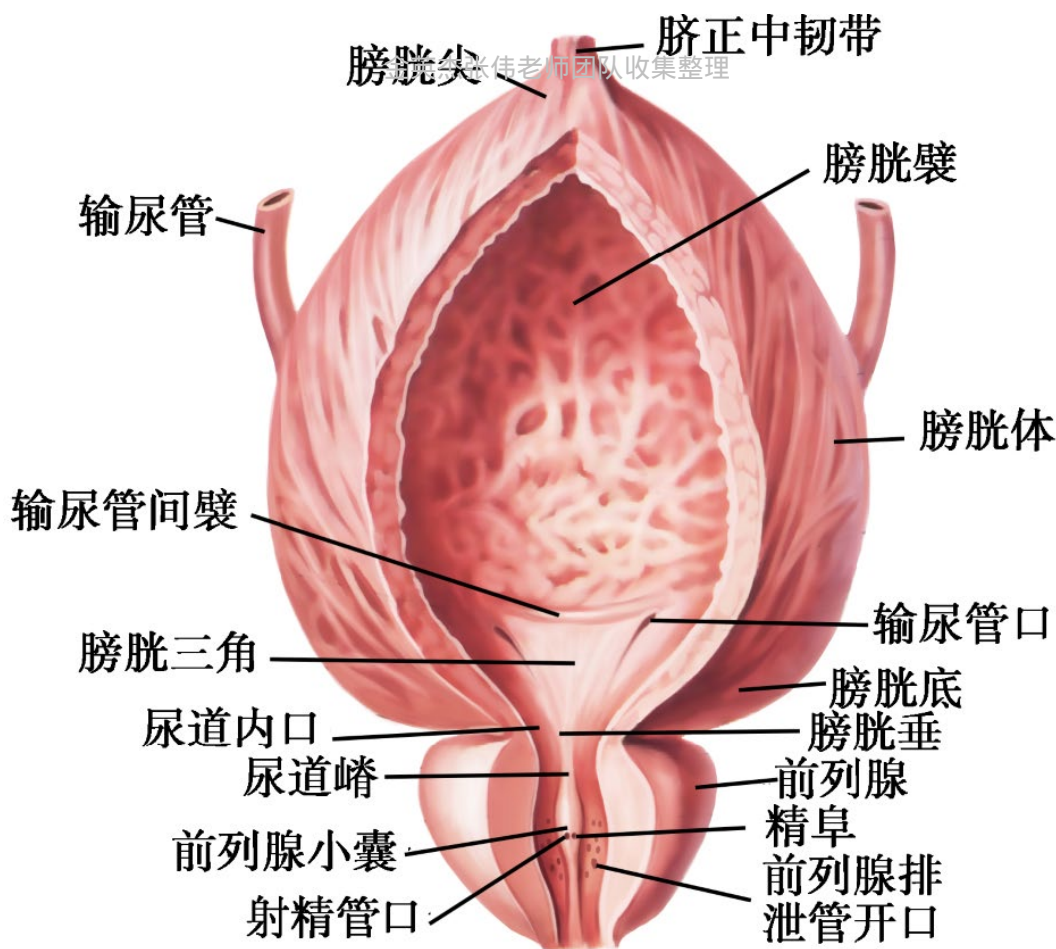
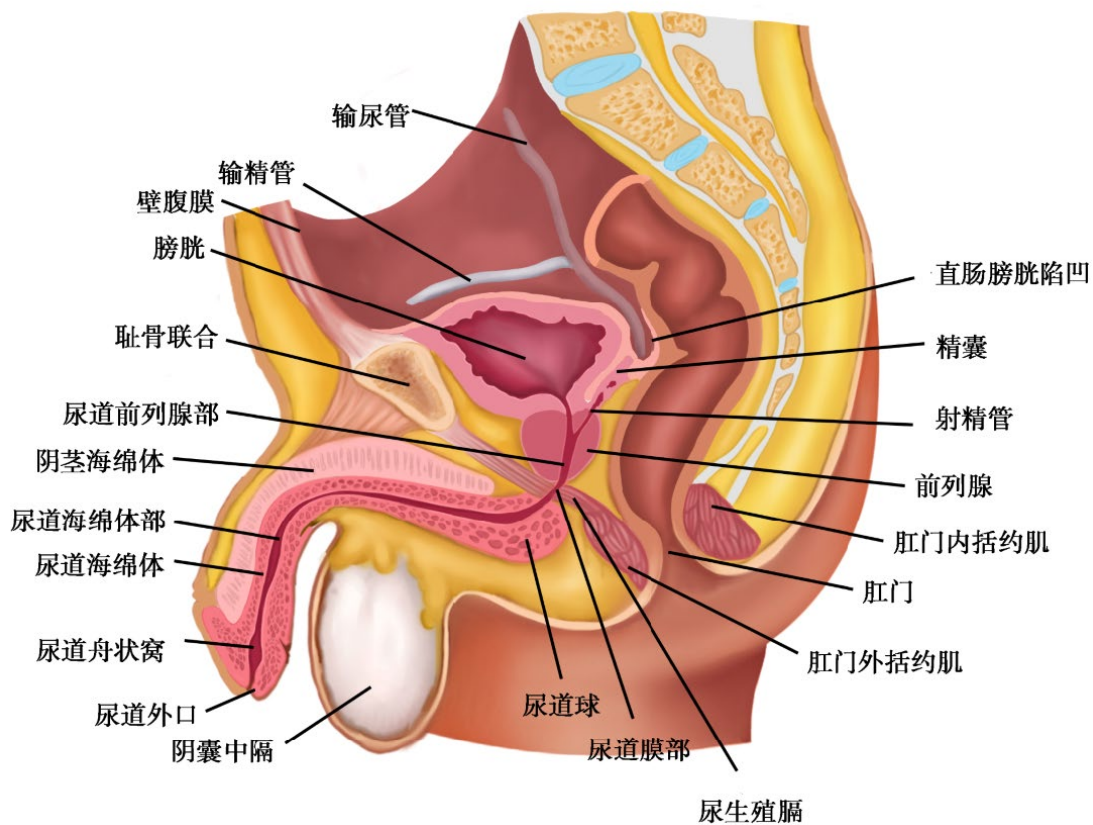
金英杰张伟老师团队收集整理



金英杰张伟老师

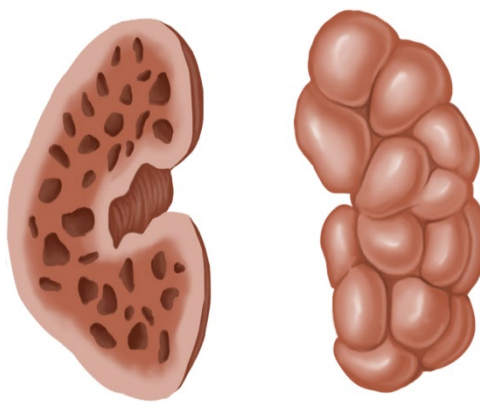
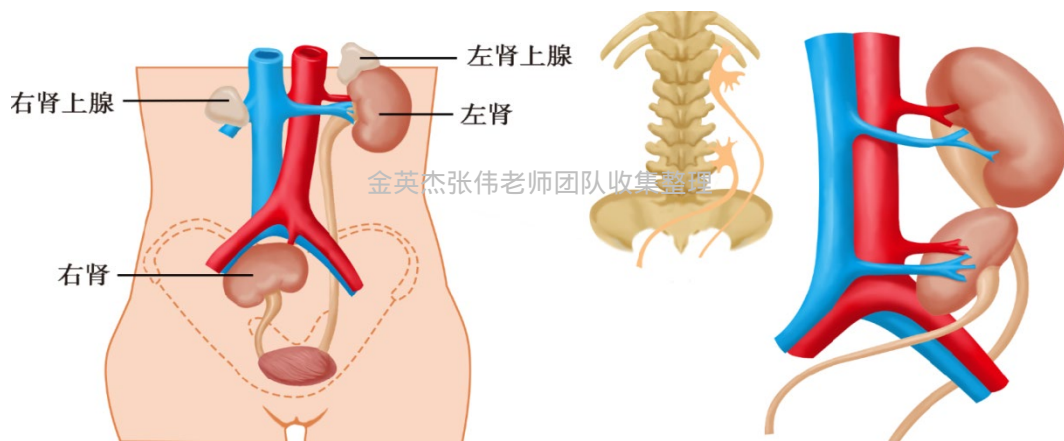
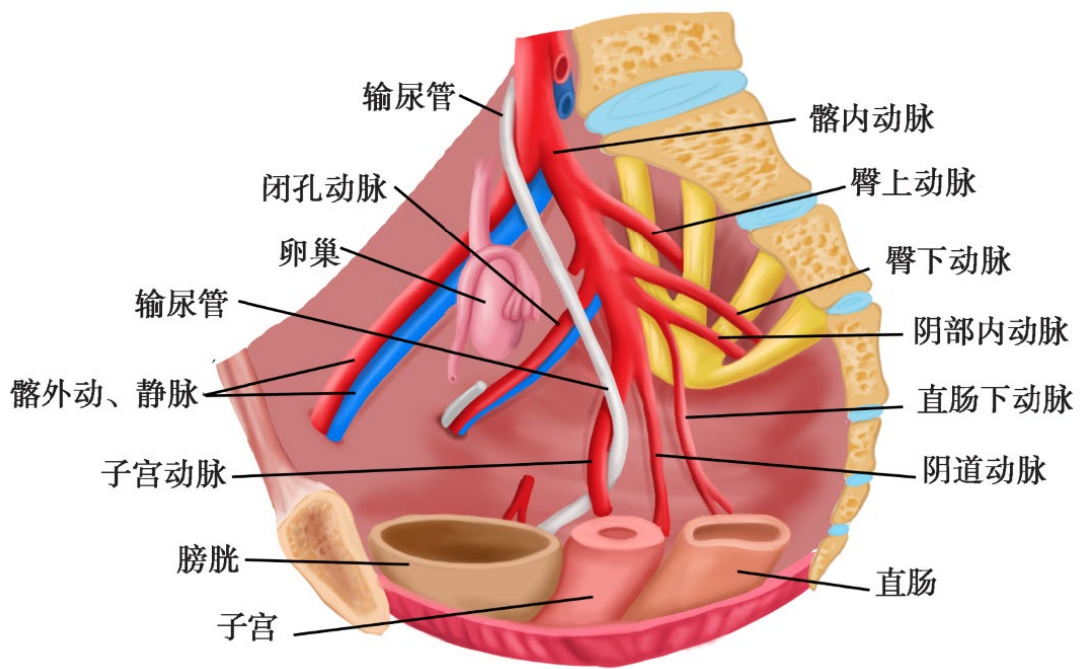
获取更多医考资料请关注





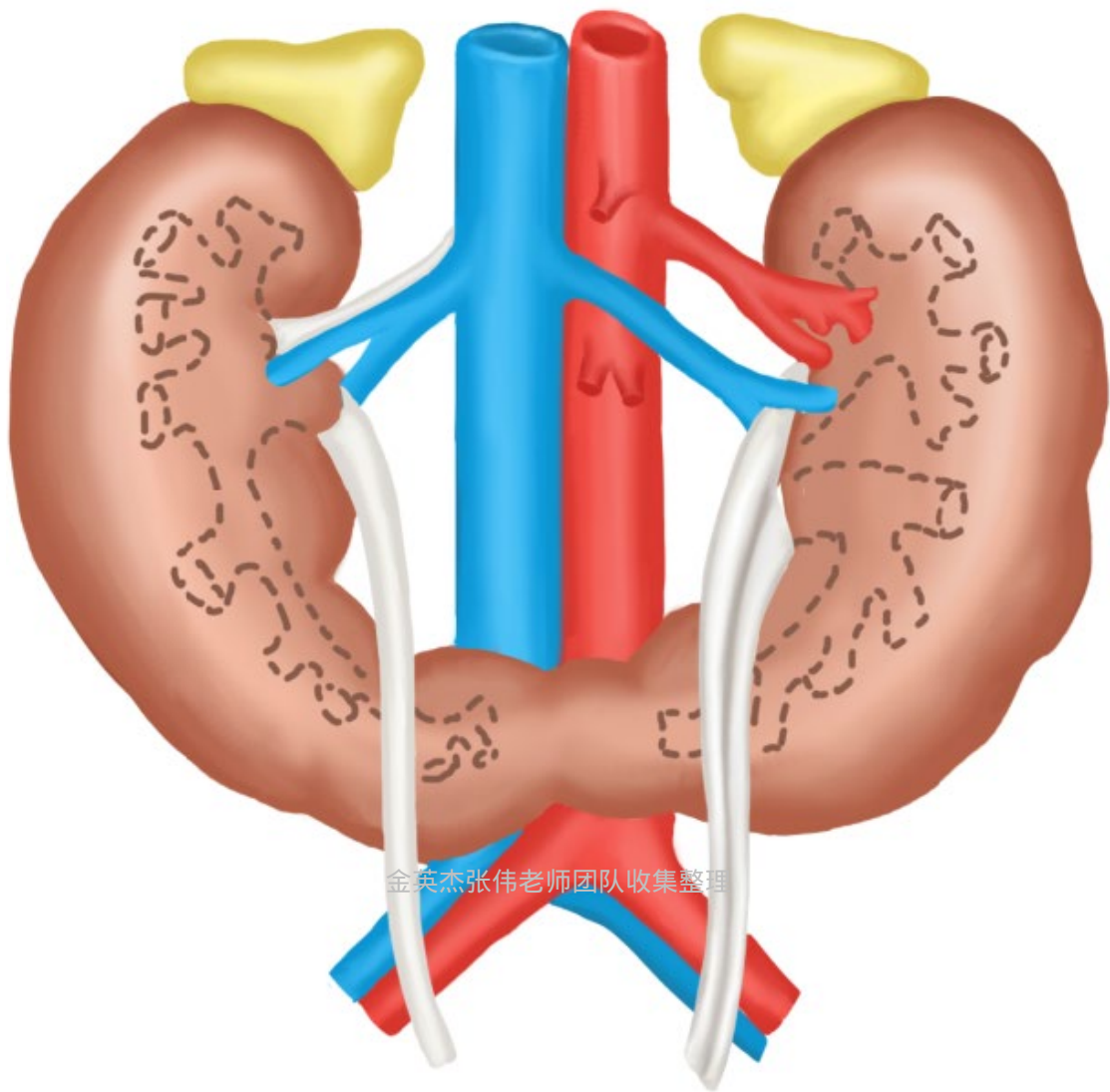
获取更多医考资料请关注



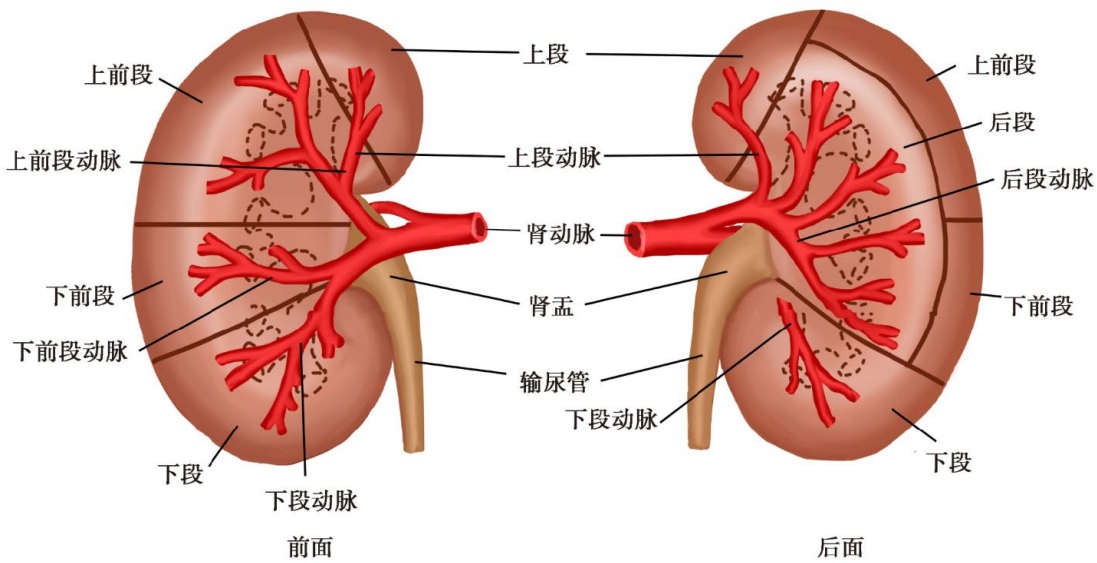


获取更多医考资料请关注



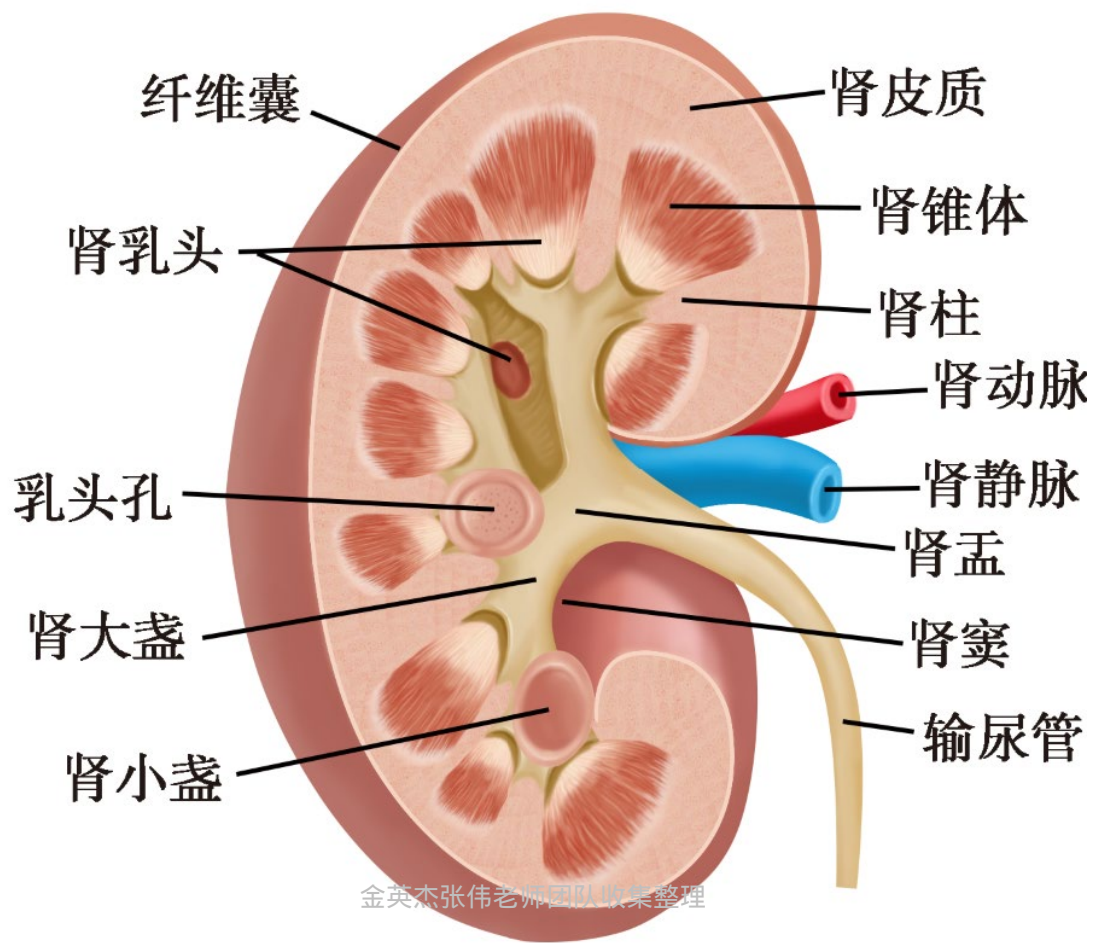


金英杰张伟老师团队收集整理



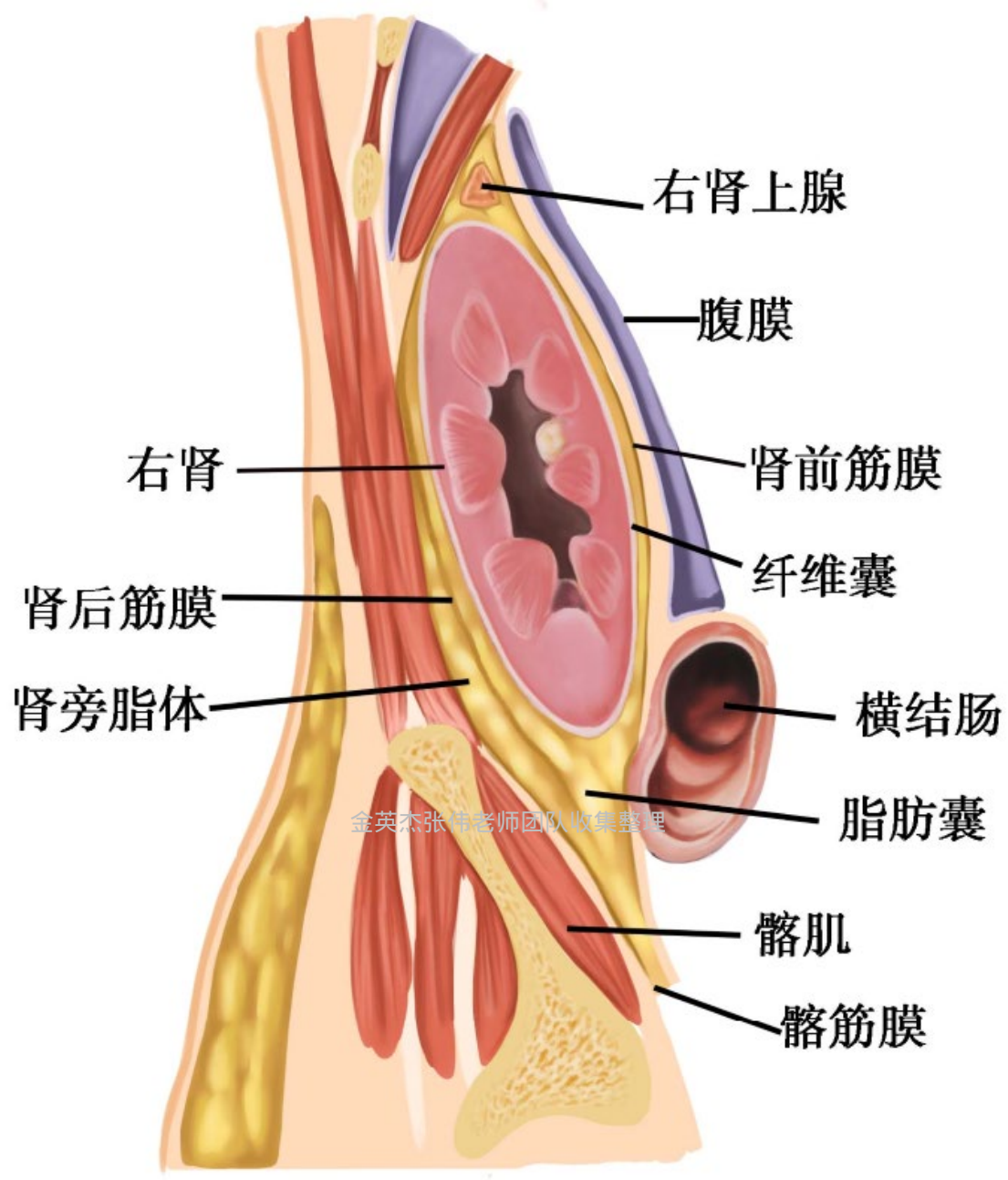
获取更多医考资料请关注





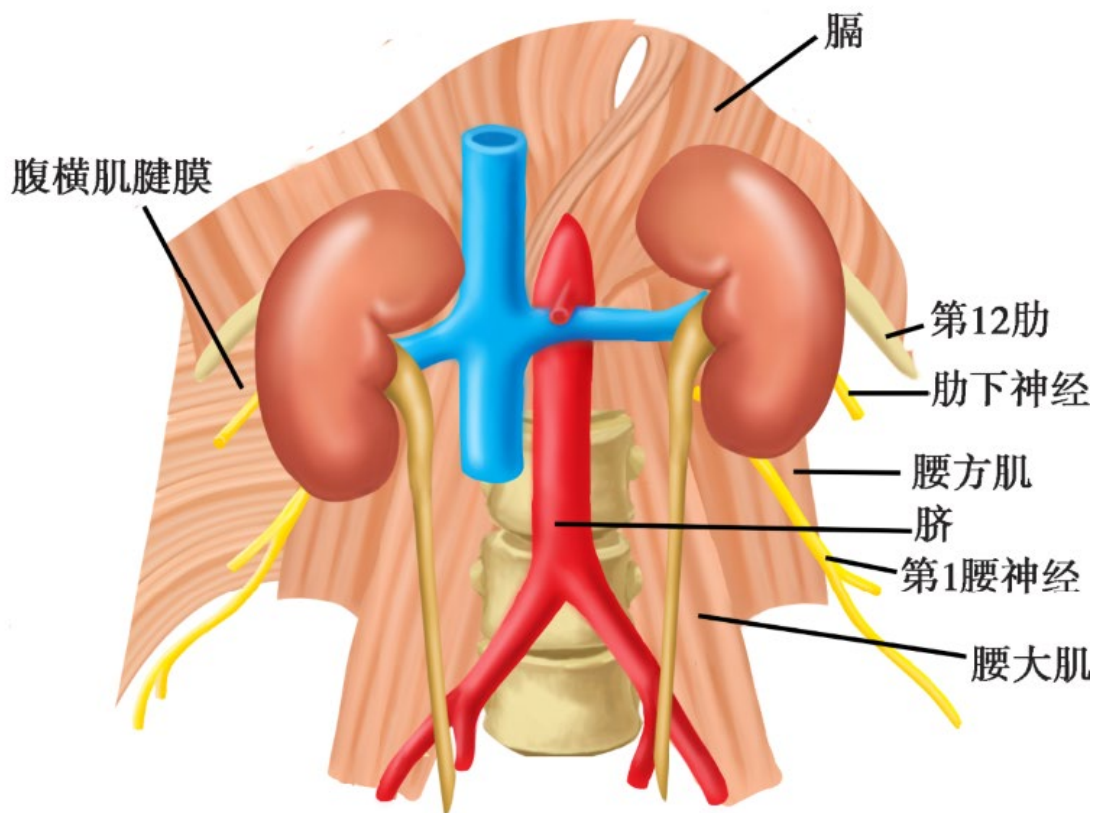
获取更多医考资料请关注





获取更多医考资料请关注



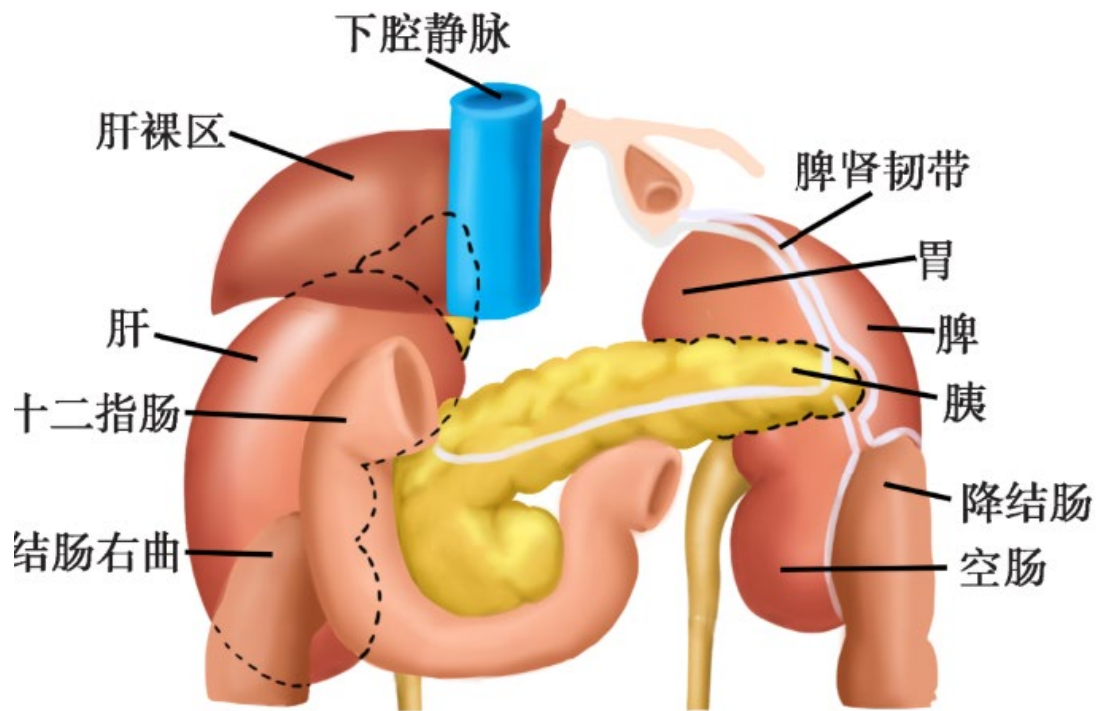


金英杰张仲景老师工作室出品
肾后面的毗邻



获取更多医考资料请关注





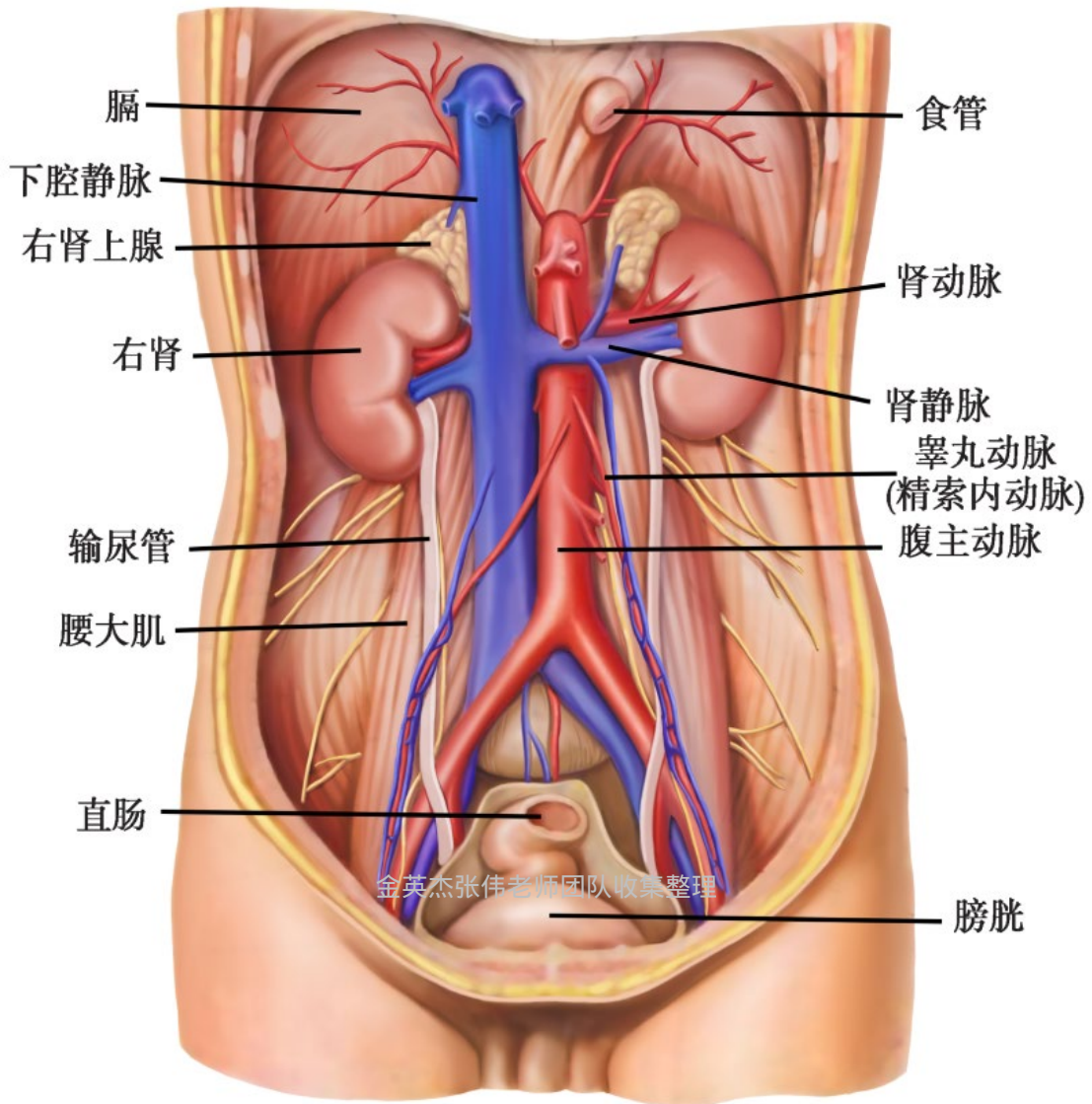
肾前面的毗邻

金英杰张伟老师团队收集整理



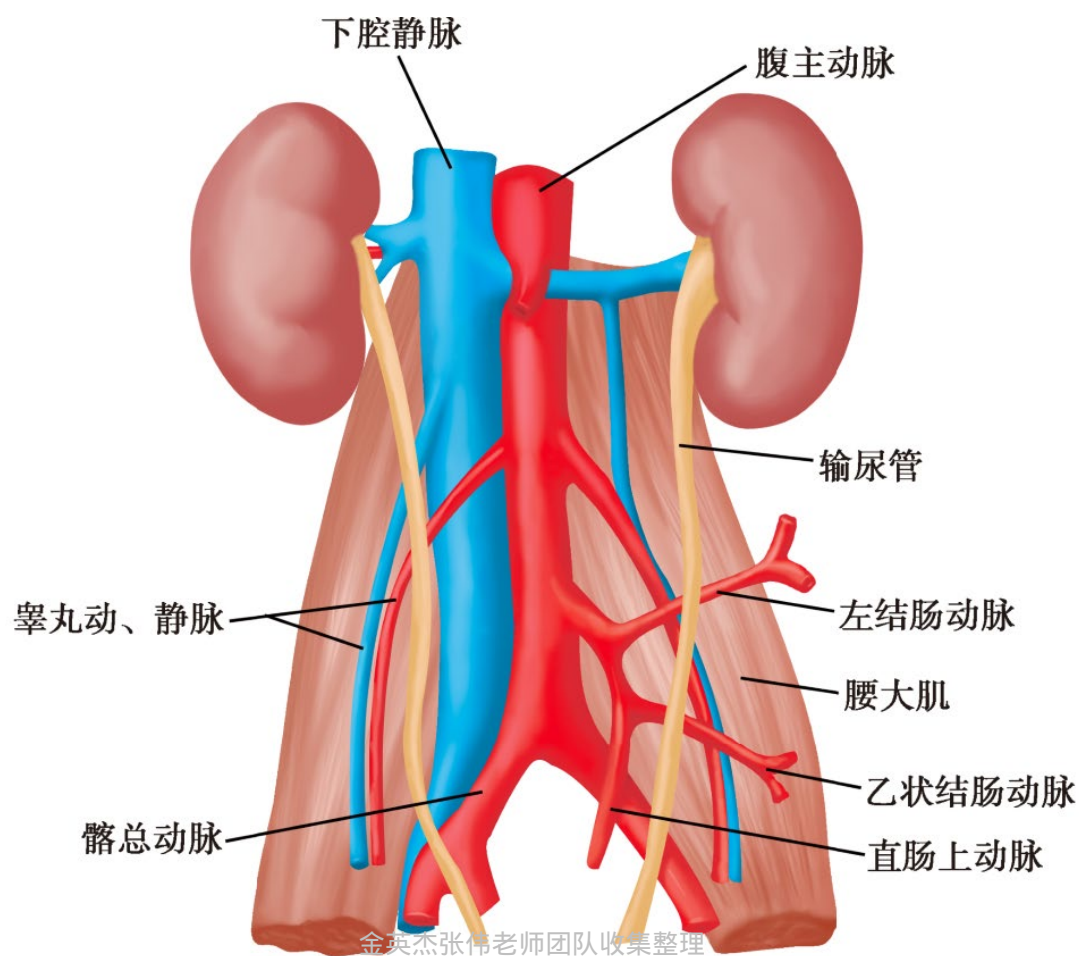
获取更多医考资料请关注





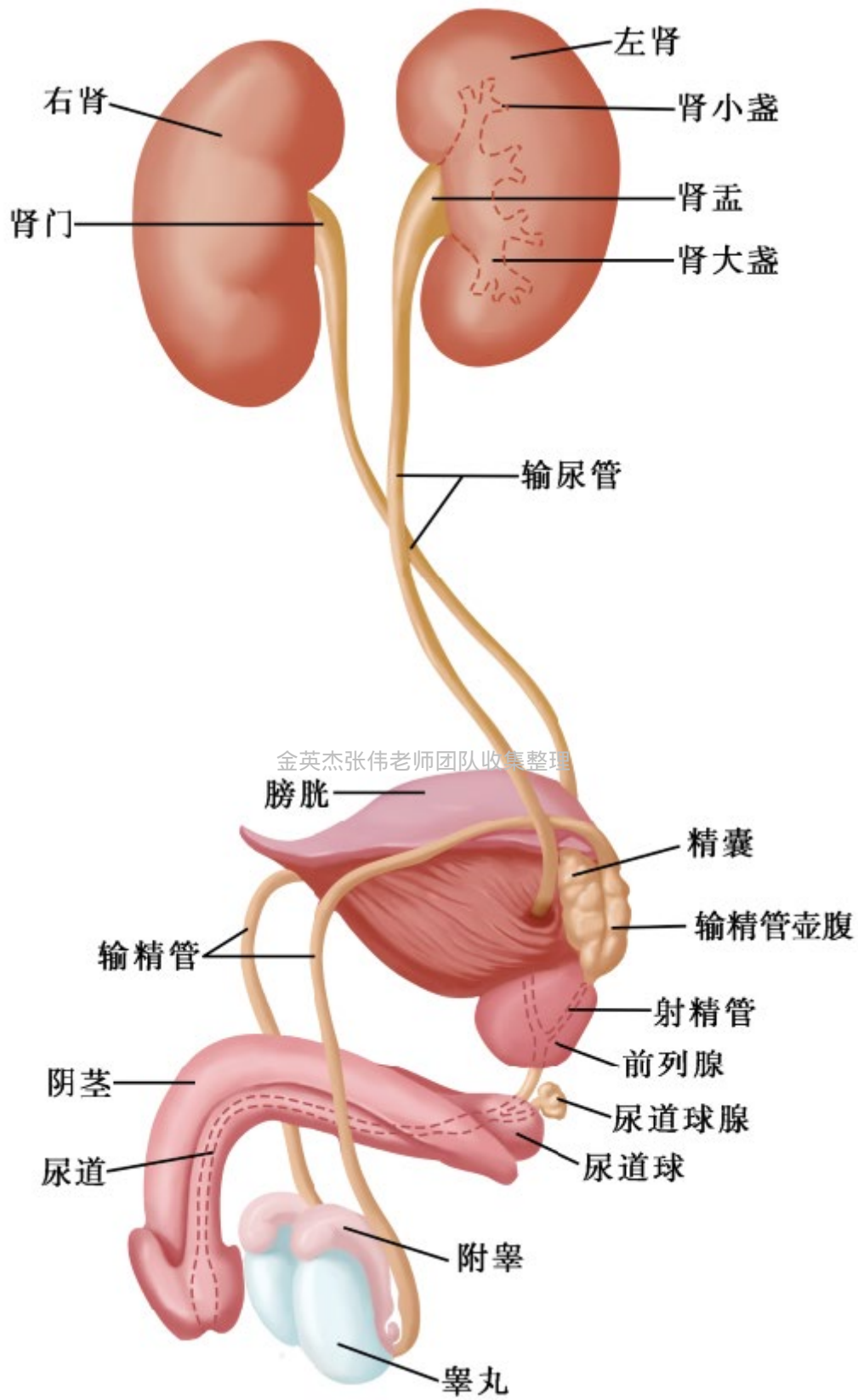
获取更多医考资料请关注





获取更多医考资料请关注

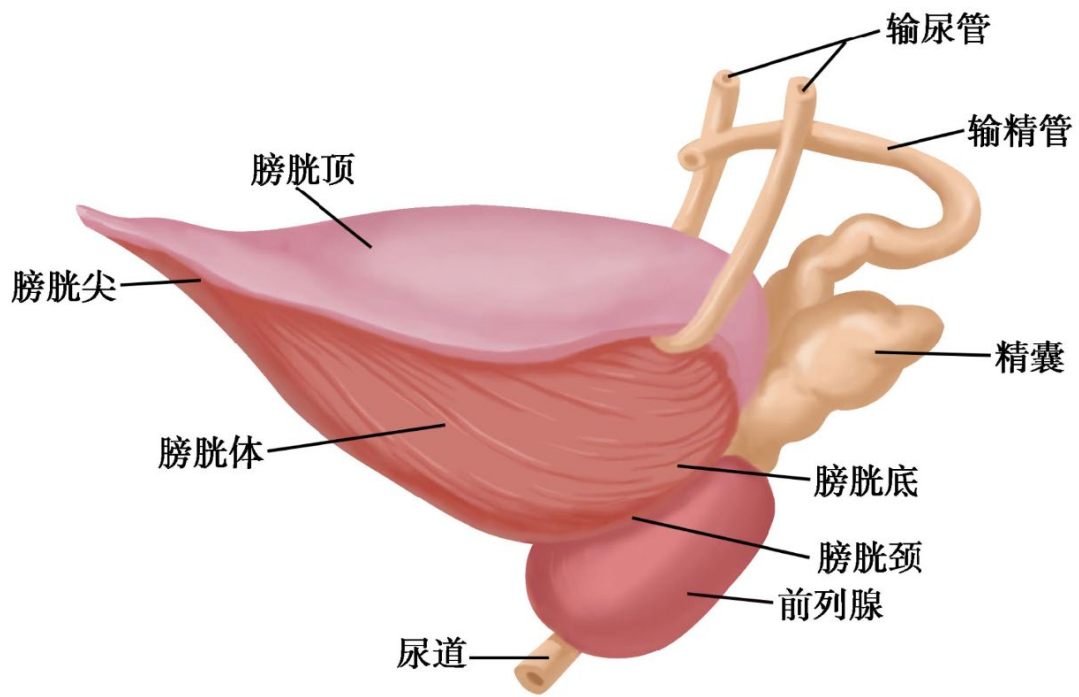




金英杰张伟老师

获取更多医考资料请关注





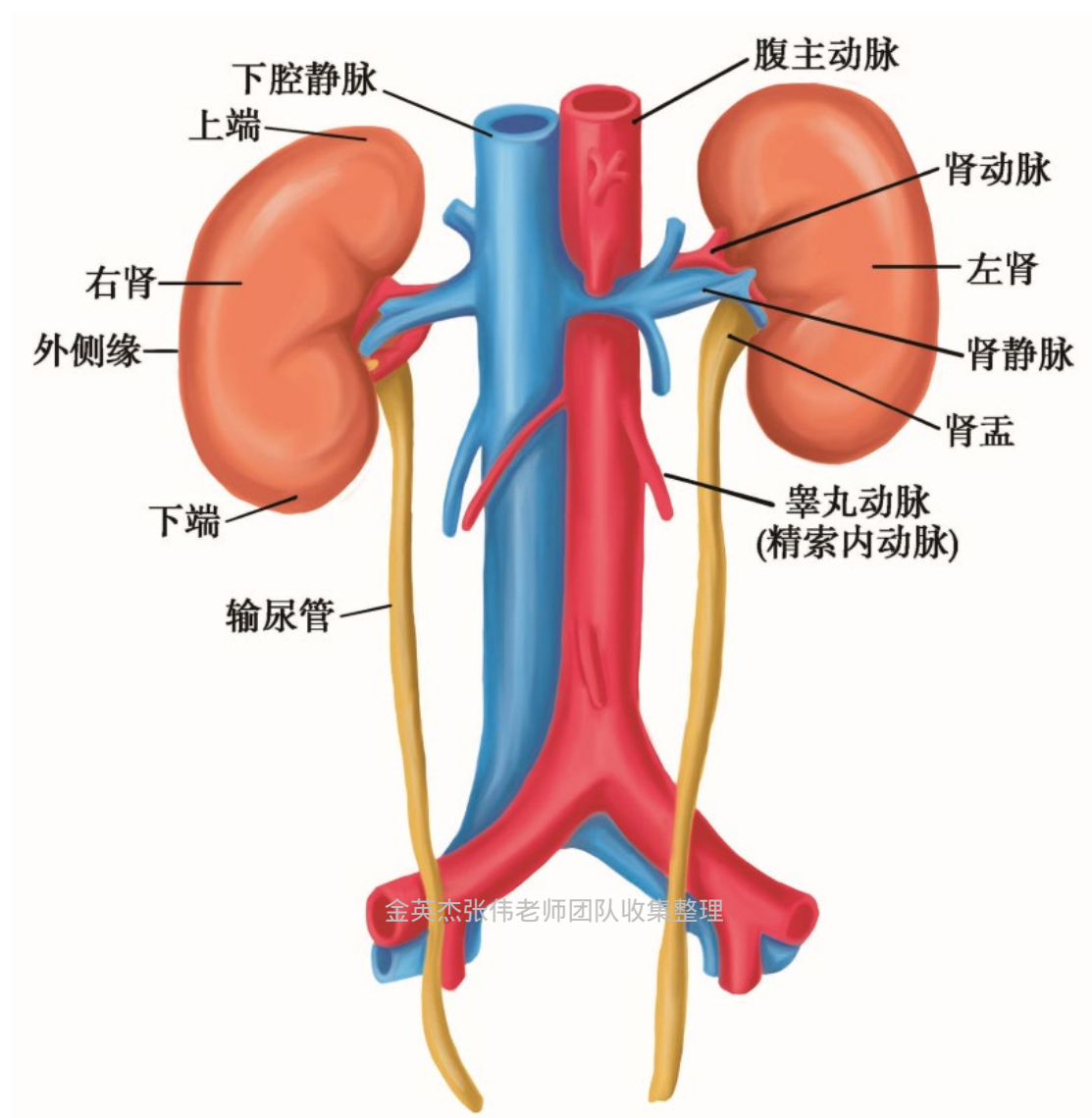
金英杰张伟老师团队收集整理



金英杰张伟老师

获取更多医考资料请关注

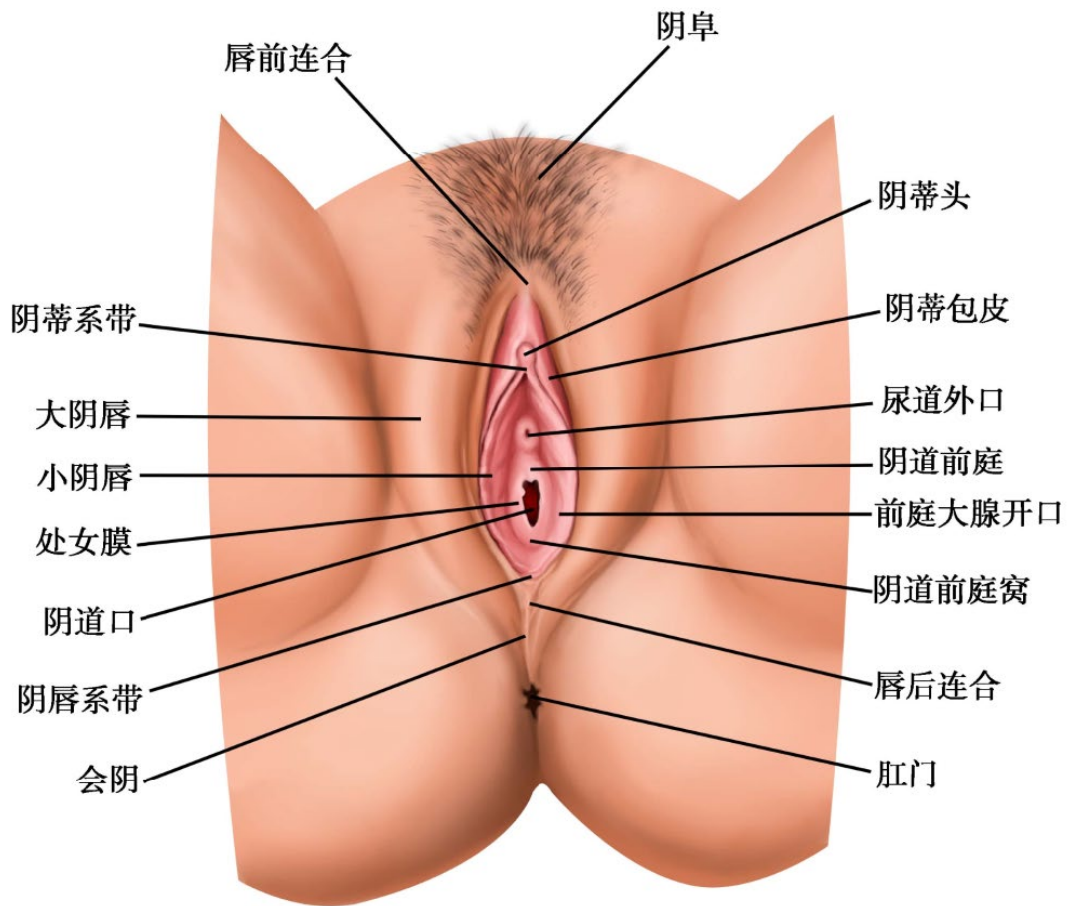




妇科

获取更多医考资料请关注

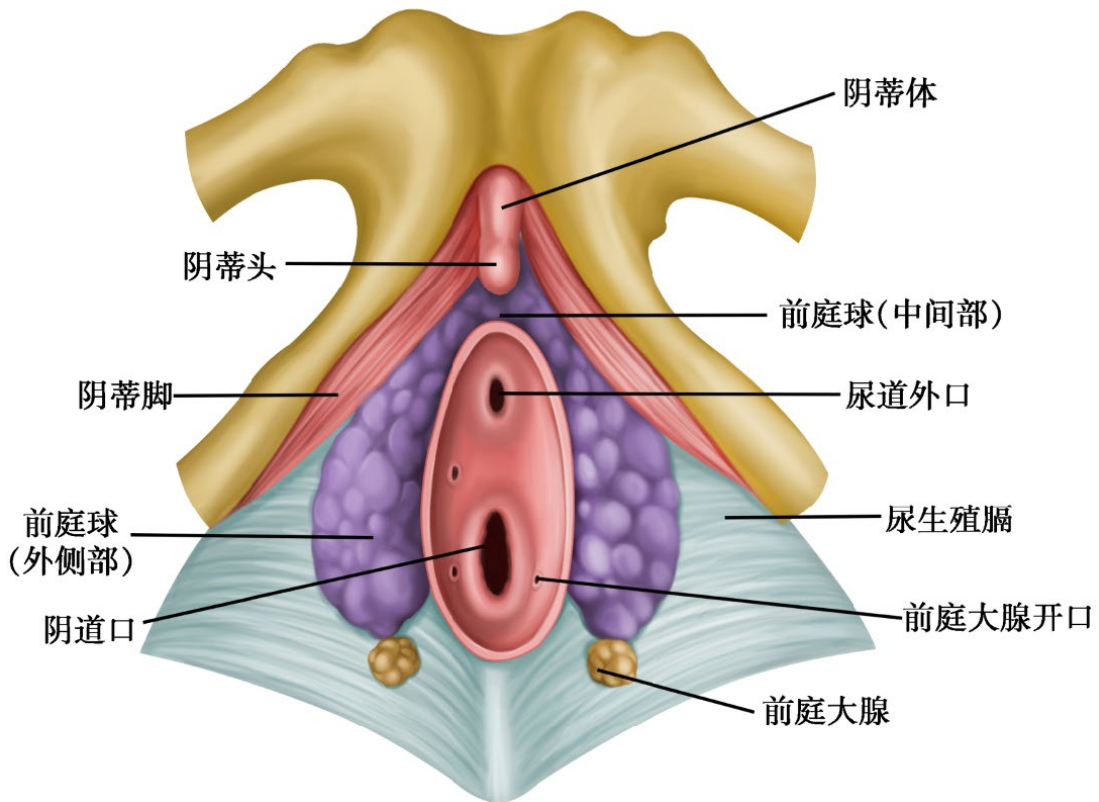




金英杰张伟老师团队收集整理

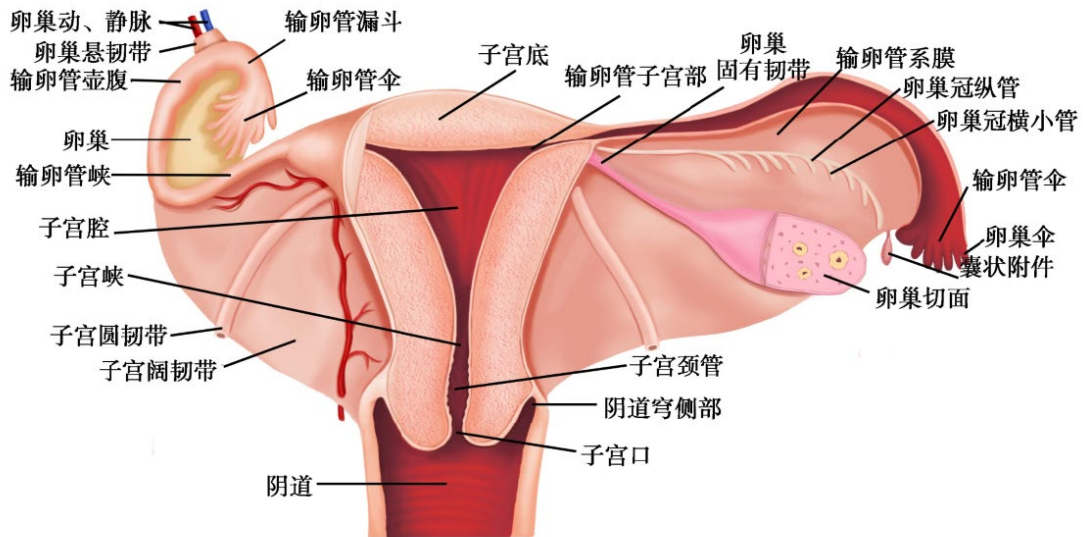


金英杰张伟老师

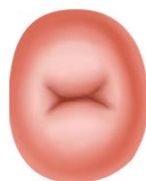

获取更多医考资料请关注

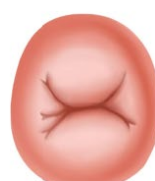



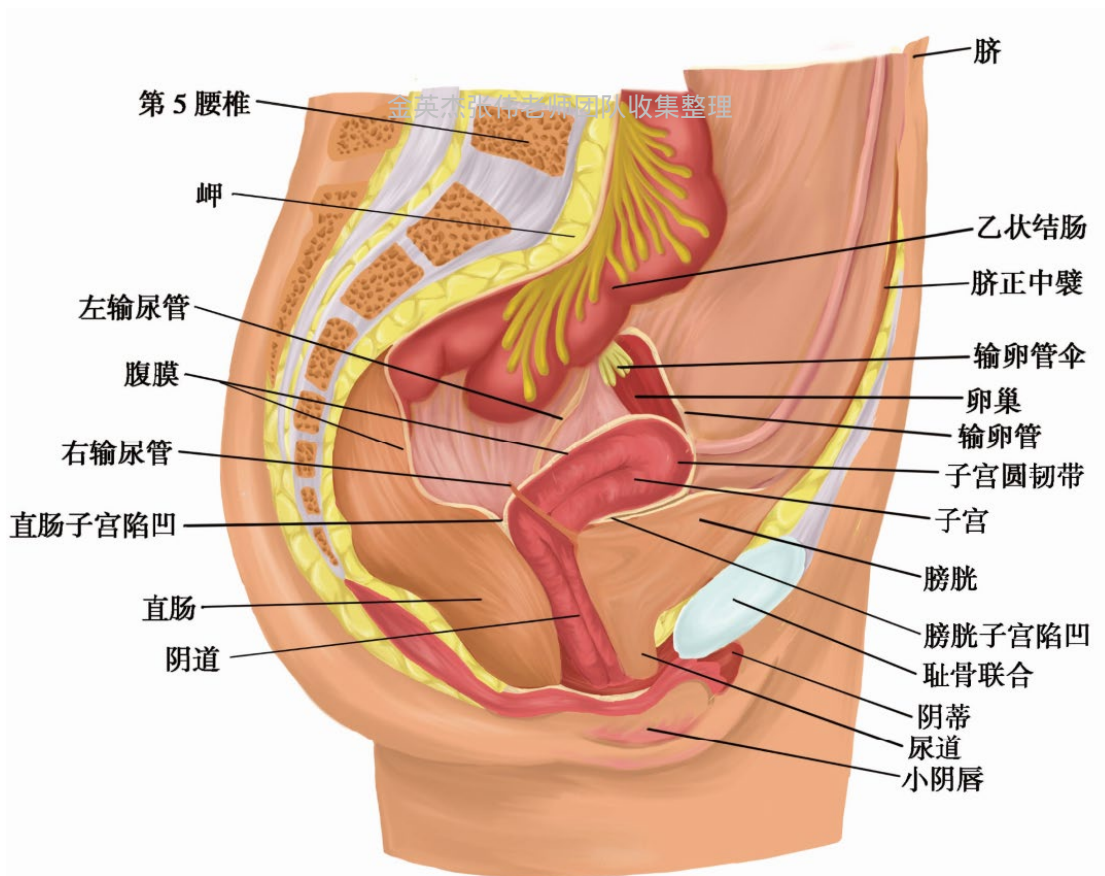
未产妇女子宫口



未产妇女子宫口



经产妇女子宫口

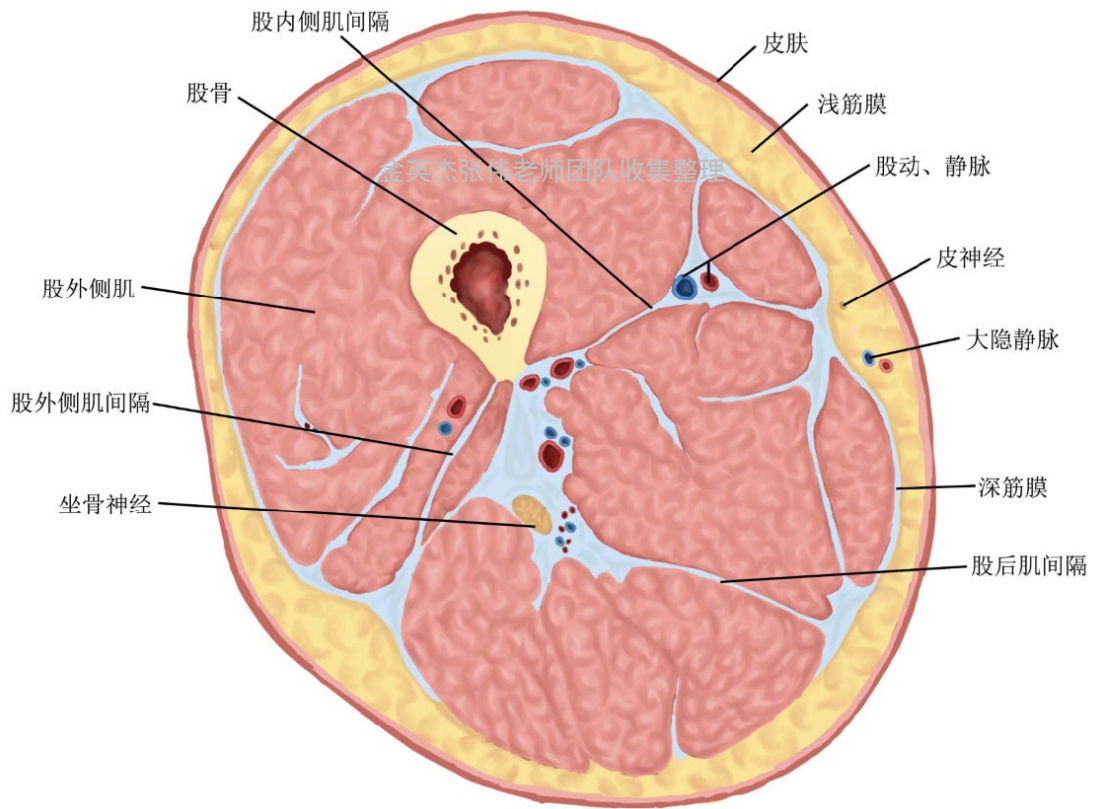
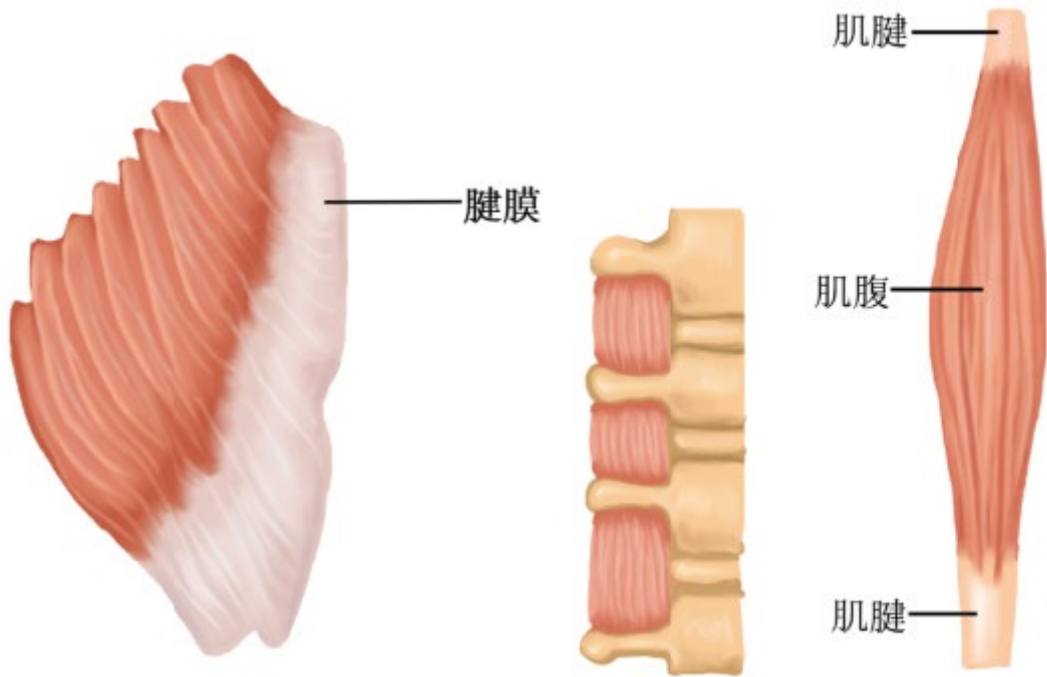


肌学

获取更多医考资料请关注



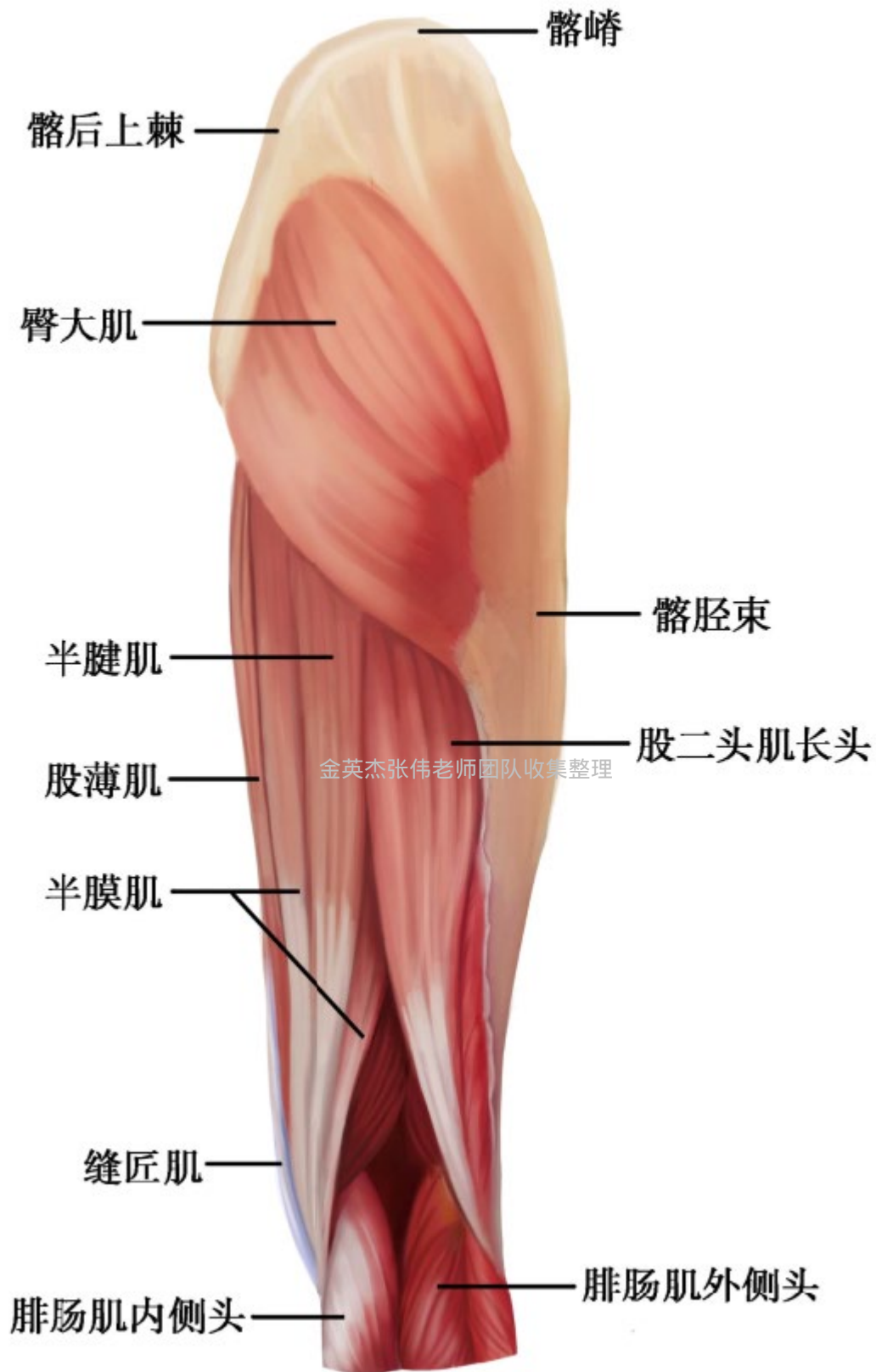
金英杰张伟老师



金英杰张伟老师

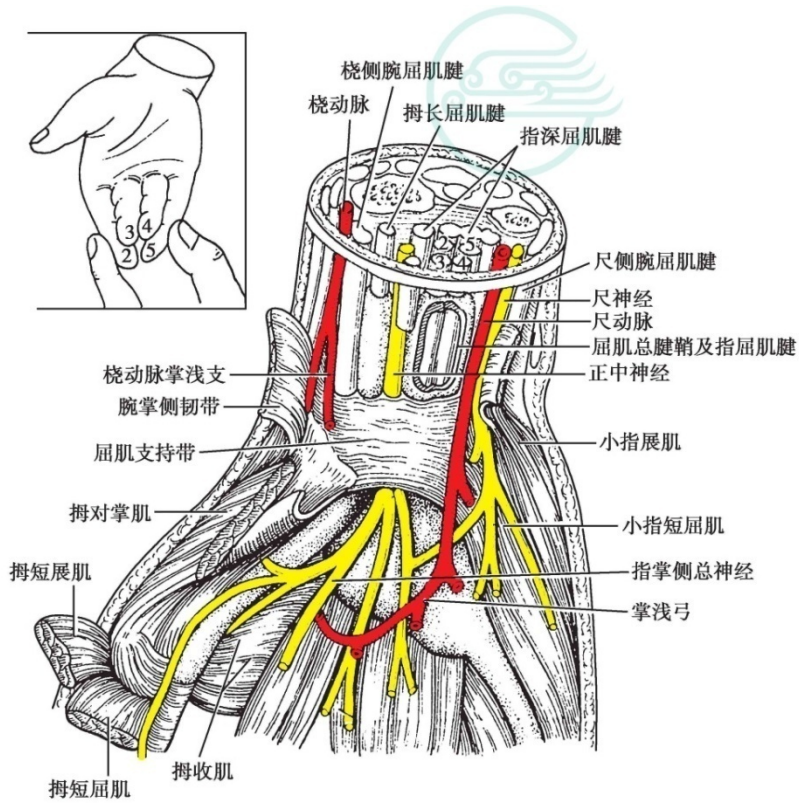
获取更多医考资料请关注





获取更多医考资料请关注

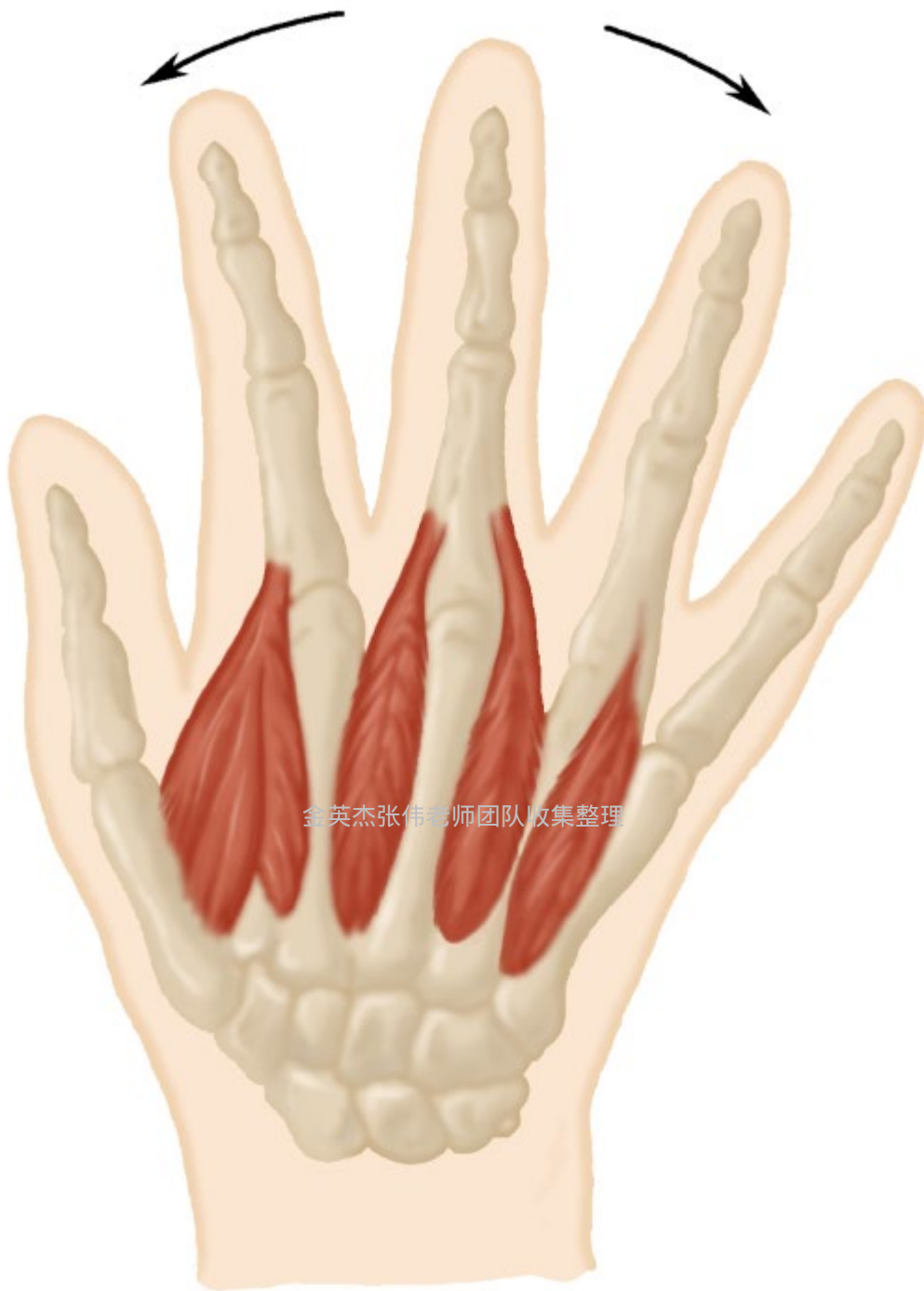




金英杰张伟老师团队收集整理



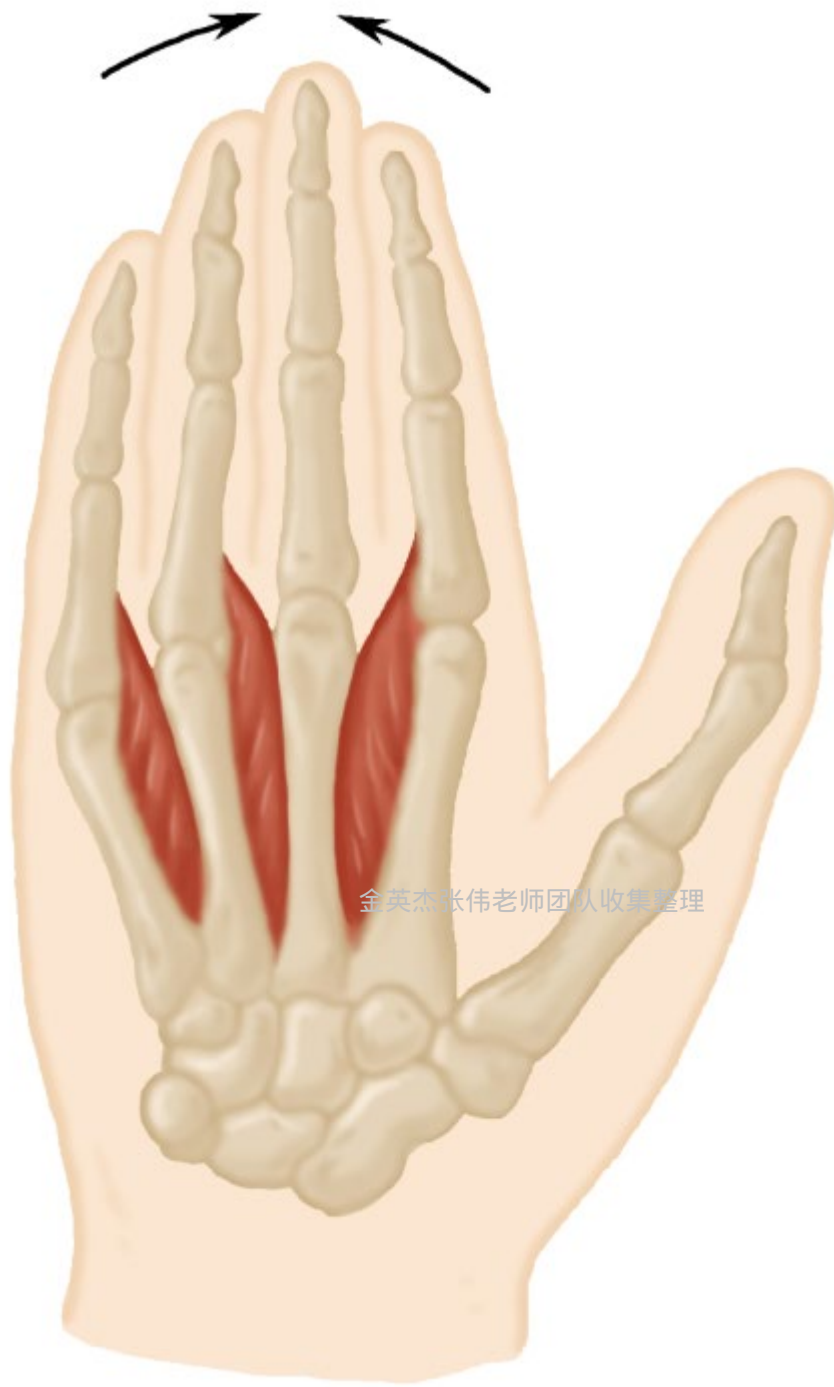
获取更多医考资料请关注



金英杰张伟老师

获取更多医考资料请关注





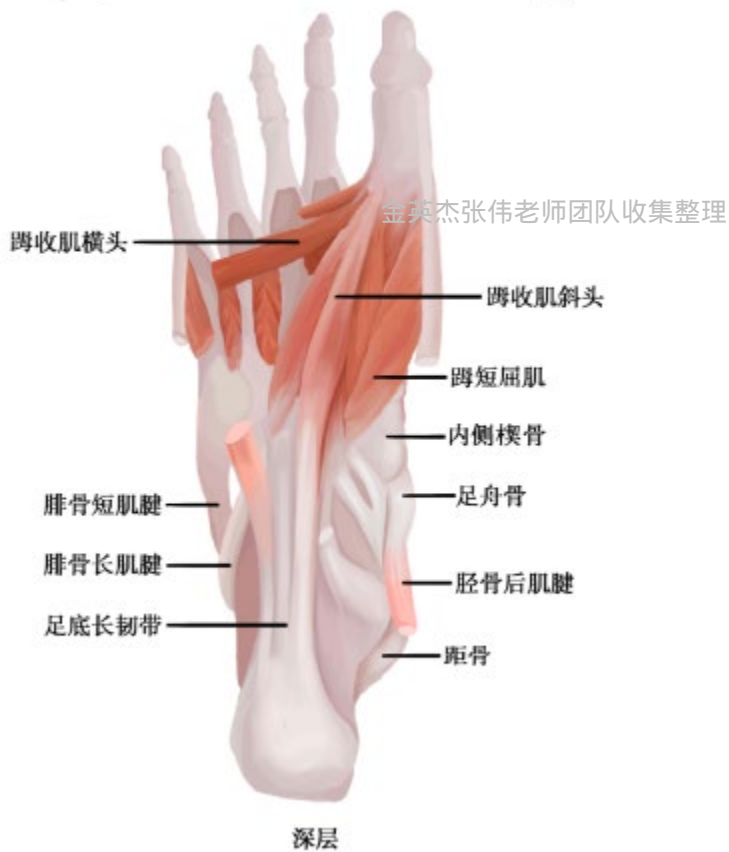
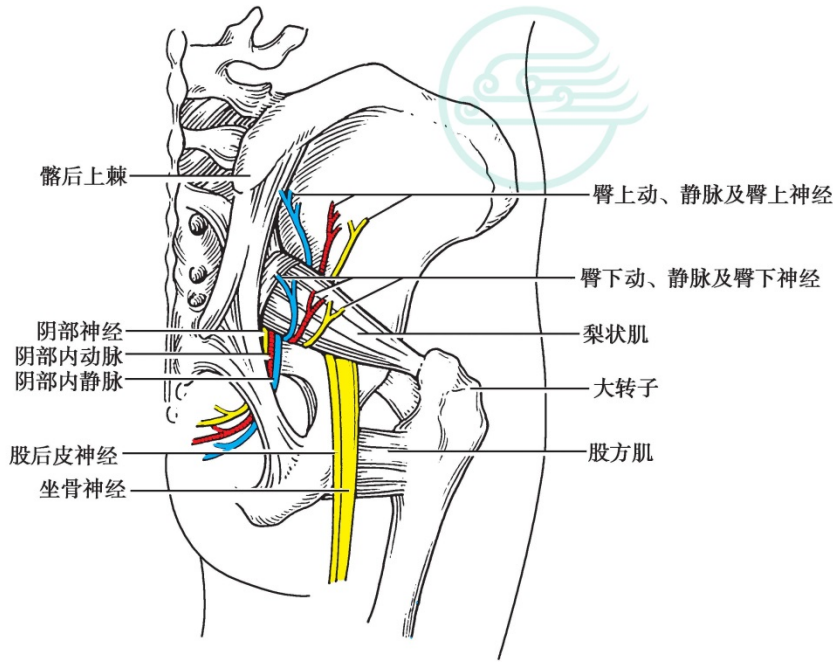
金英杰张伟老师团队收集整理



金英杰张伟老师

获取更多医考资料请关注

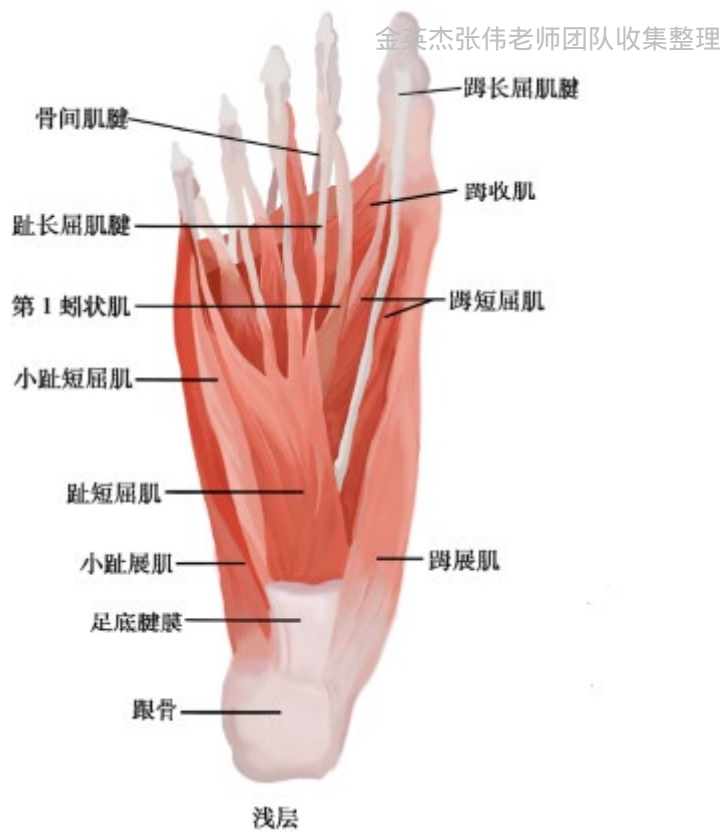
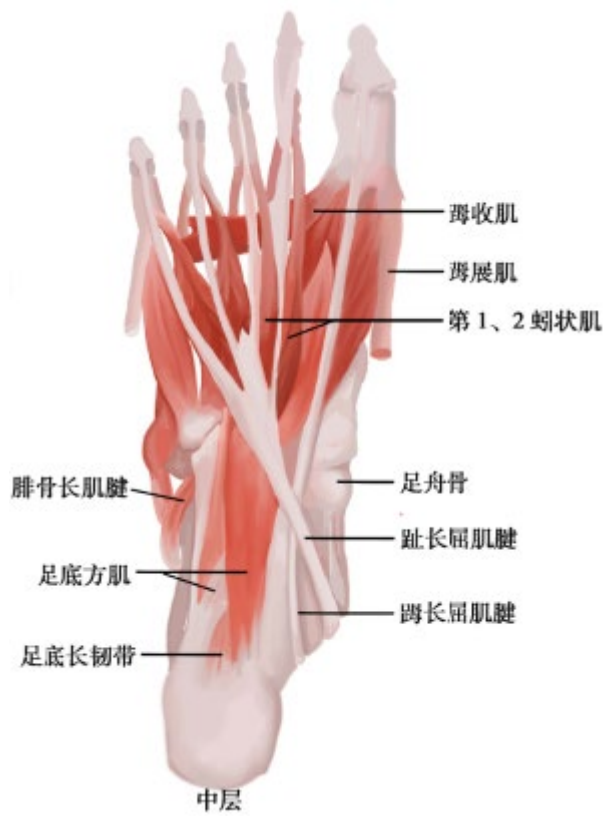



金英杰张伟老师

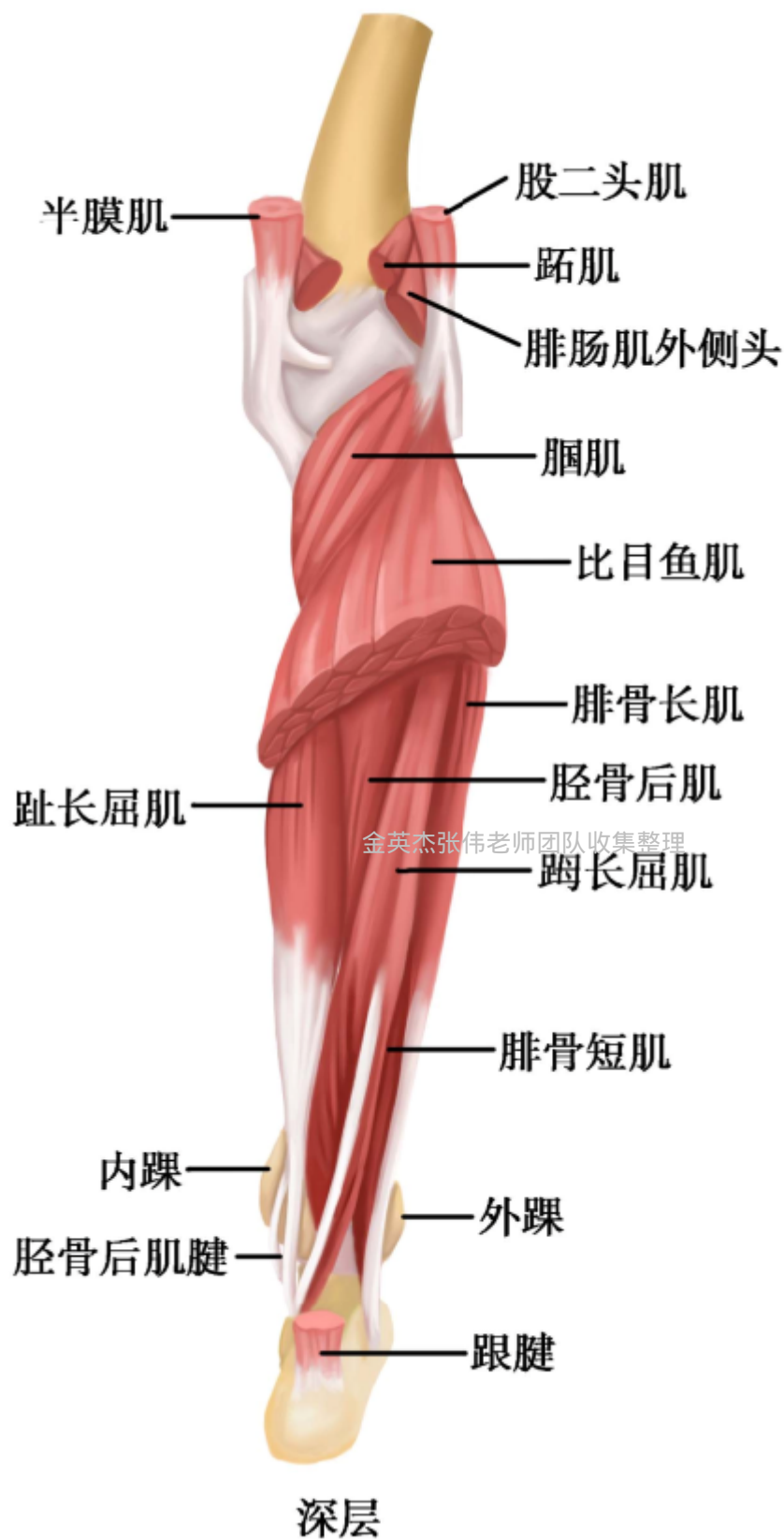
获取更多医考资料请关注





获取更多医考资料请关注

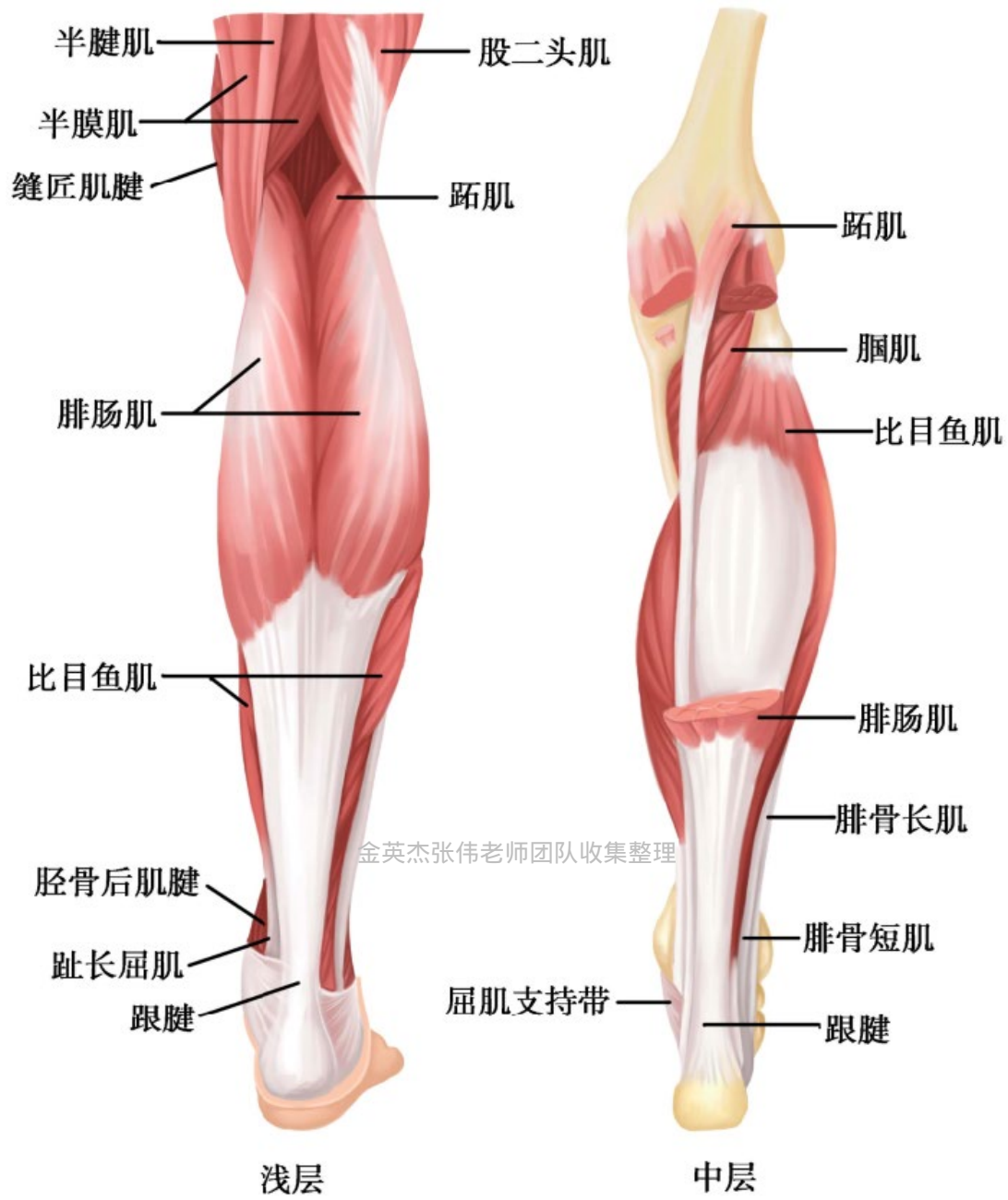




金英杰张伟老师

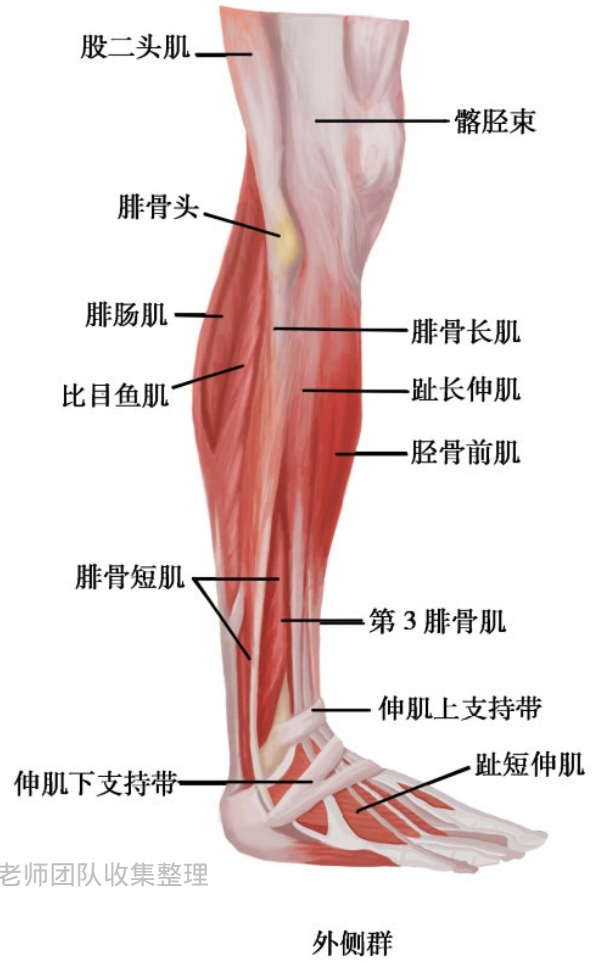
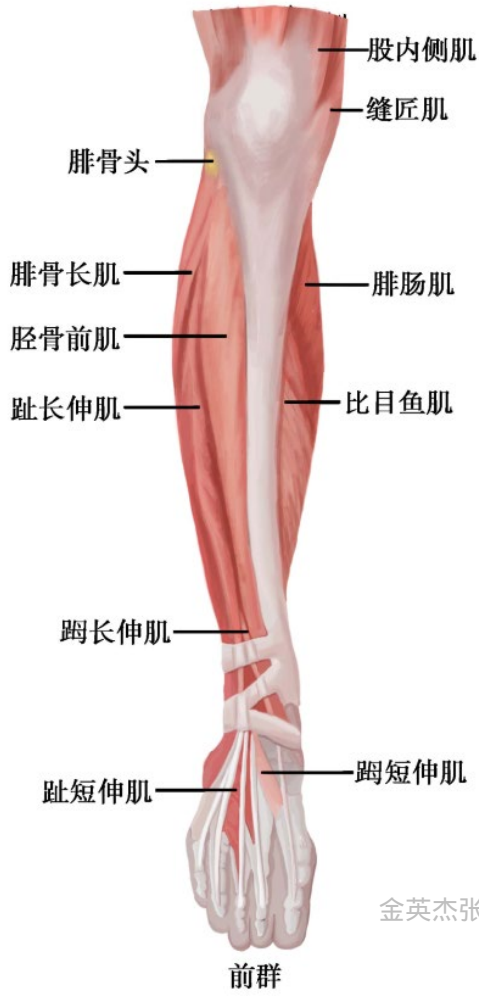
获取更多医考资料请关注





获取更多医考资料请关注



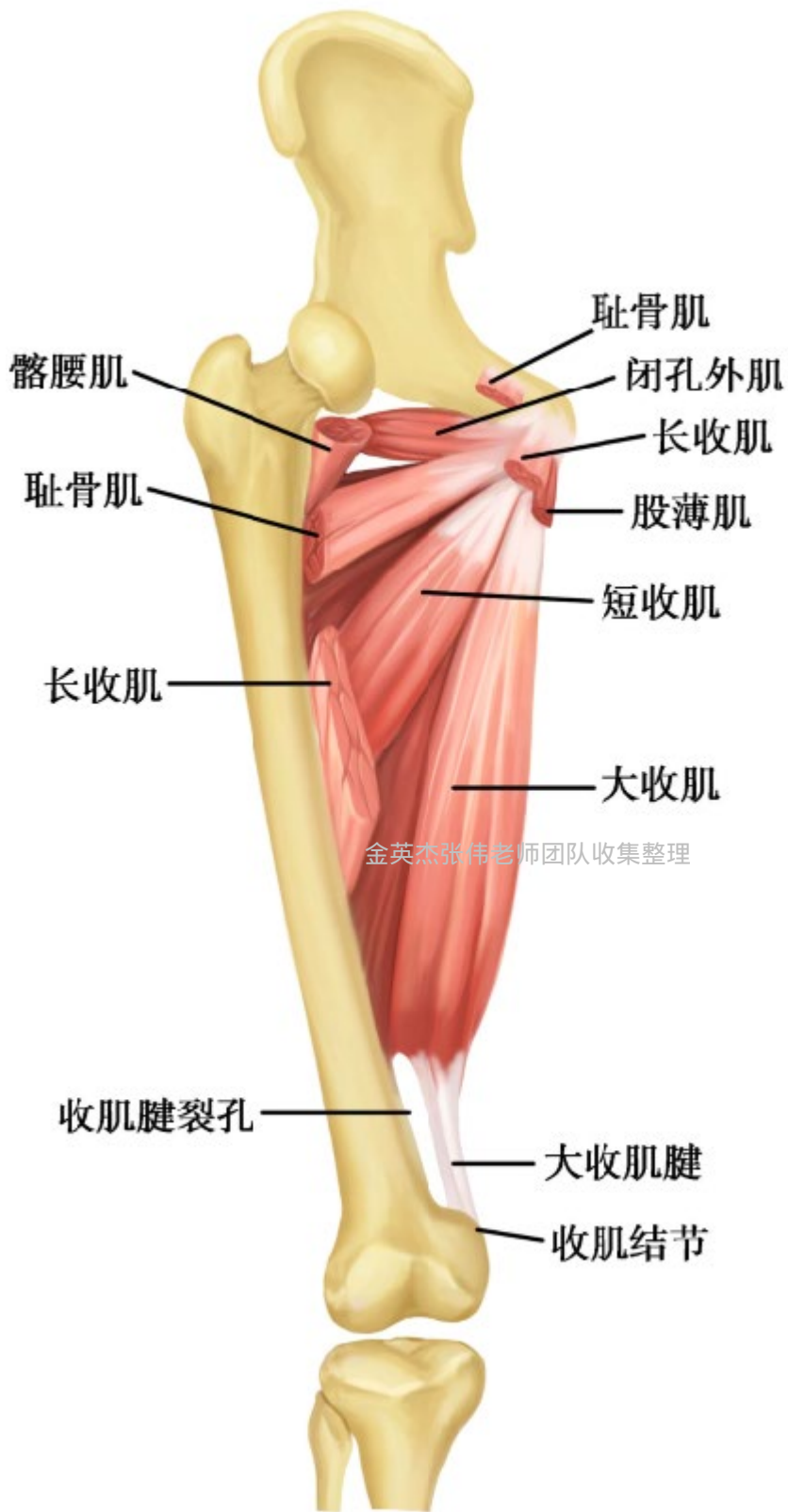


金英杰张伟老师团队收集整理



获取更多医考资料请关注

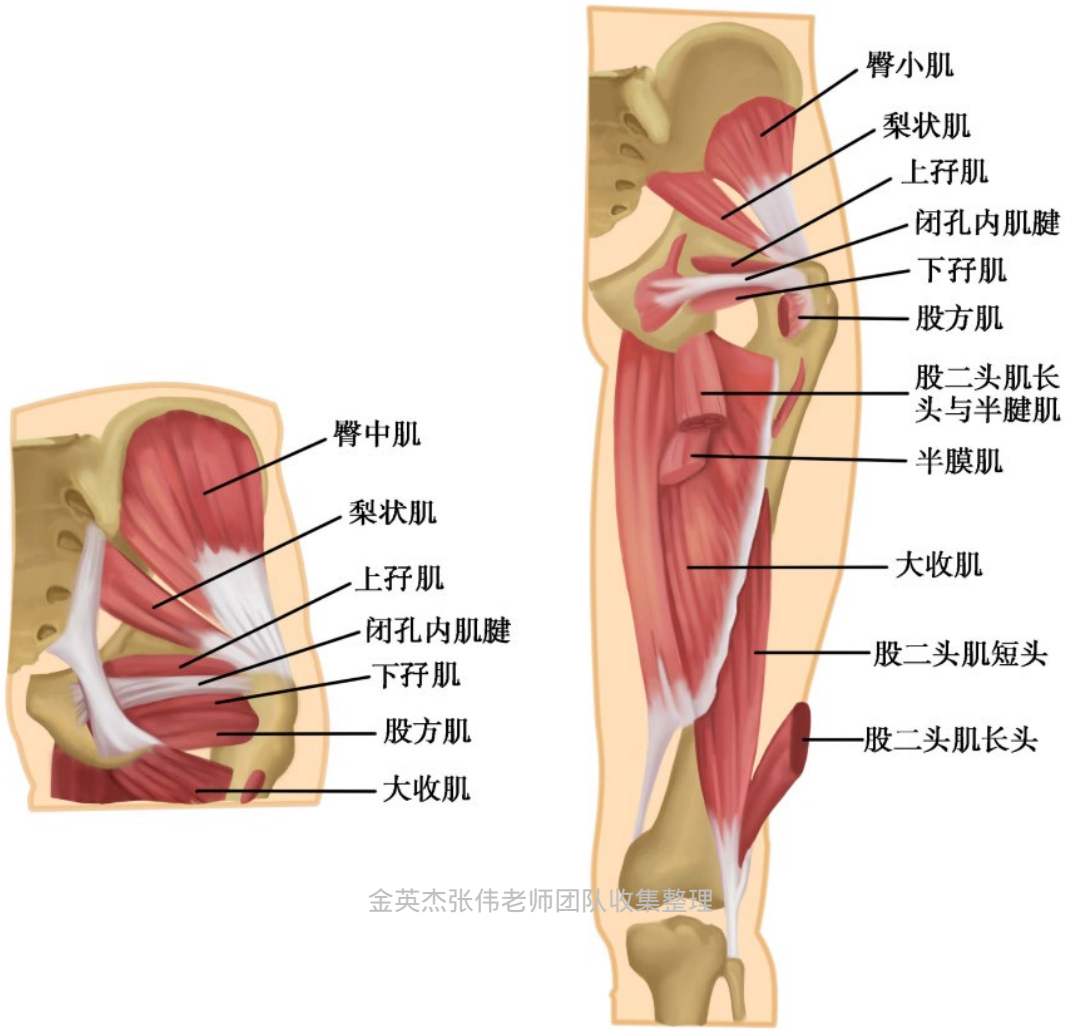




金英杰张伟老师团队收集整理



获取更多医考资料请关注

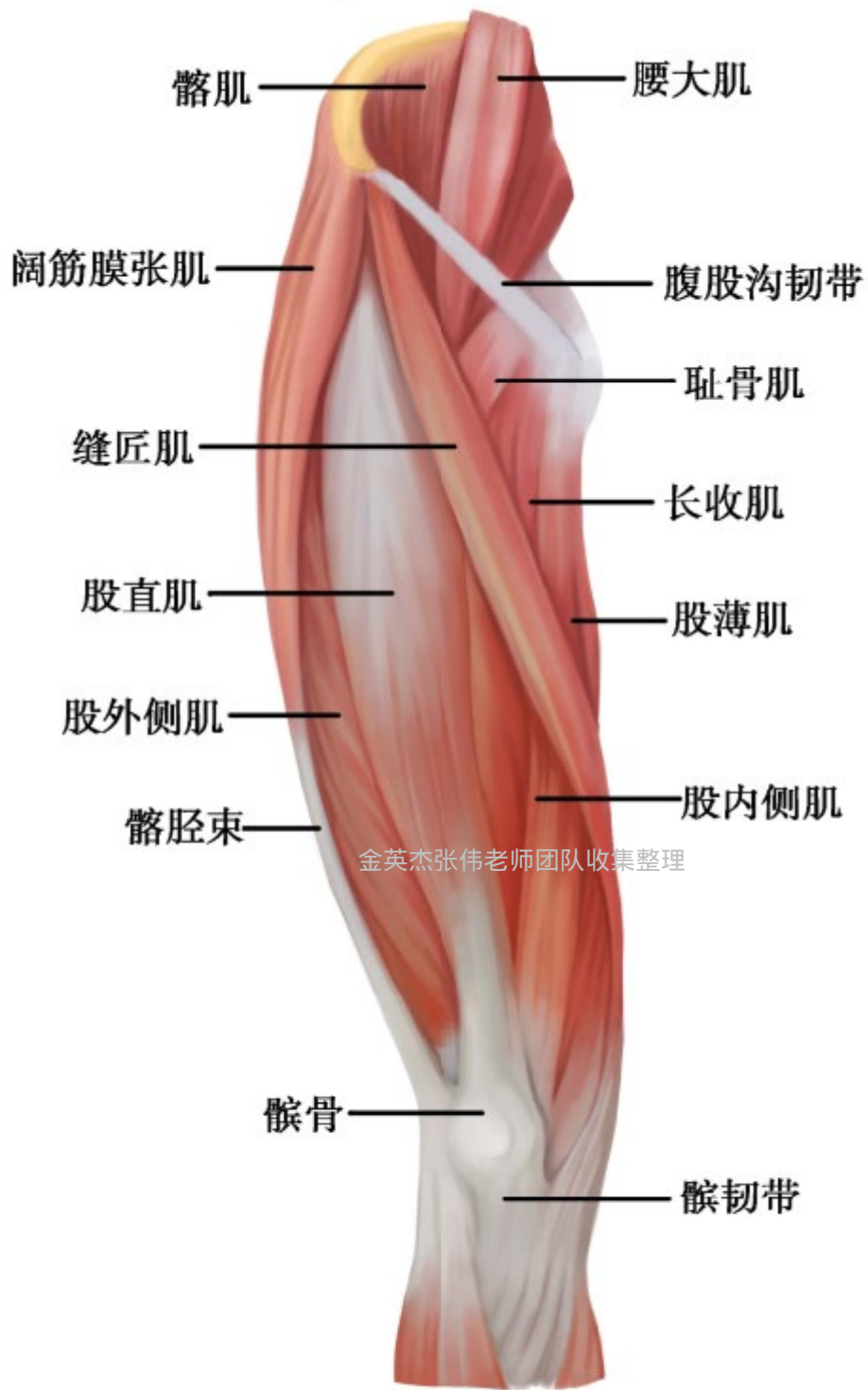


金英杰张伟老师团队收集整理



获取更多医考资料请关注

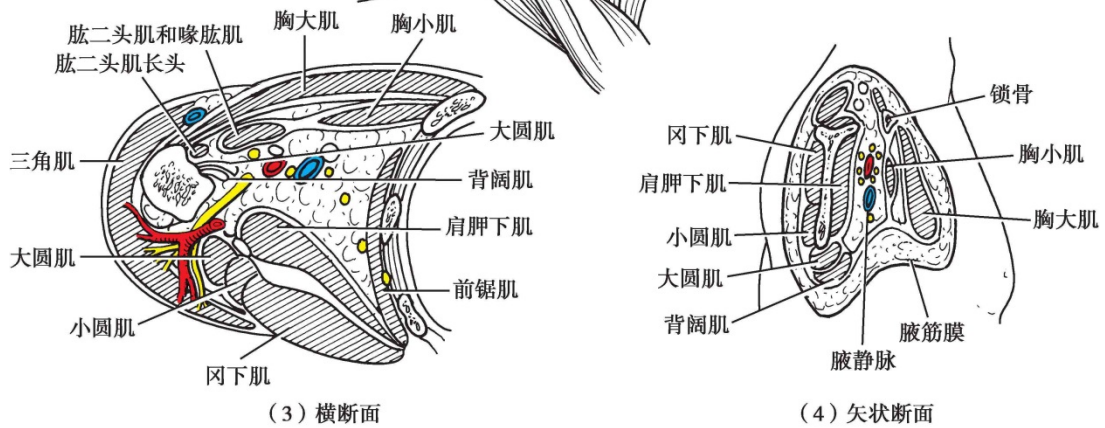
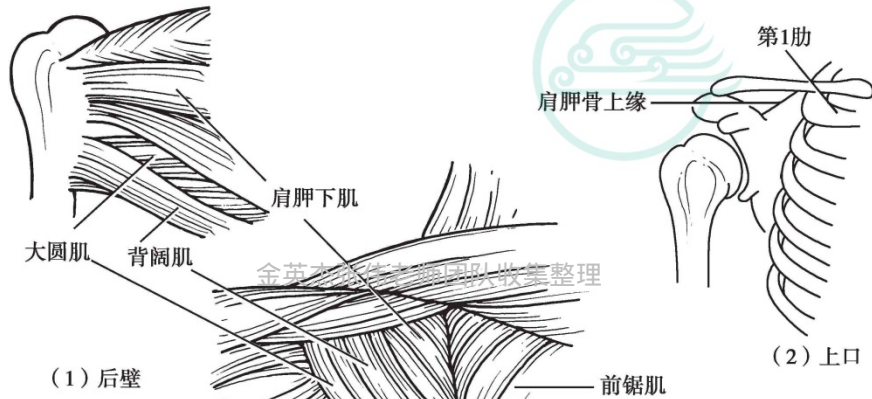
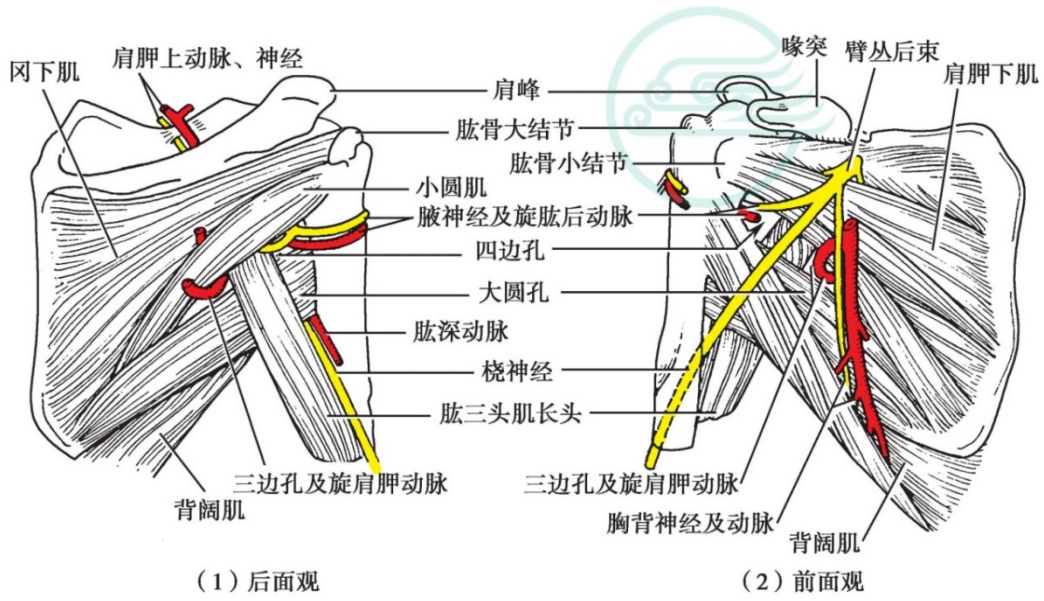


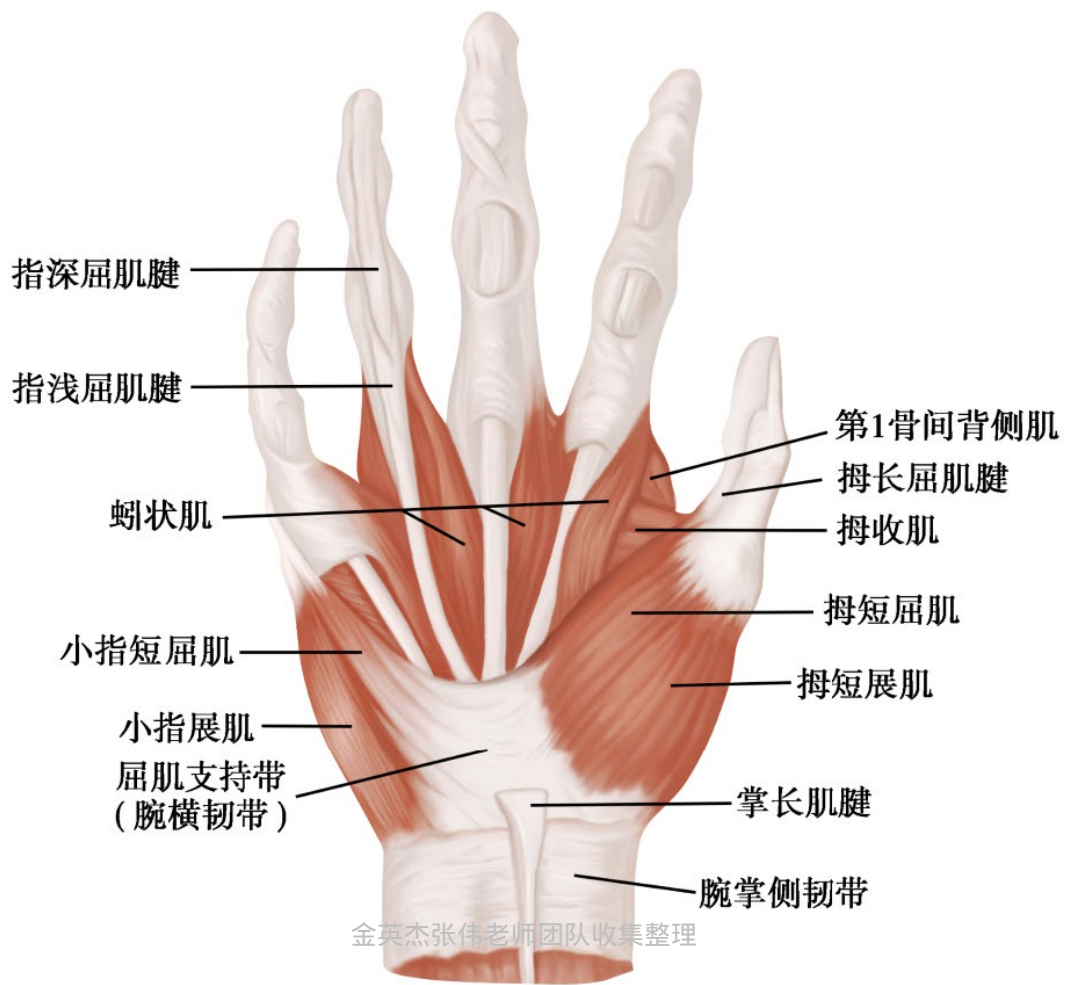


金英杰张伟老师团队收集整理



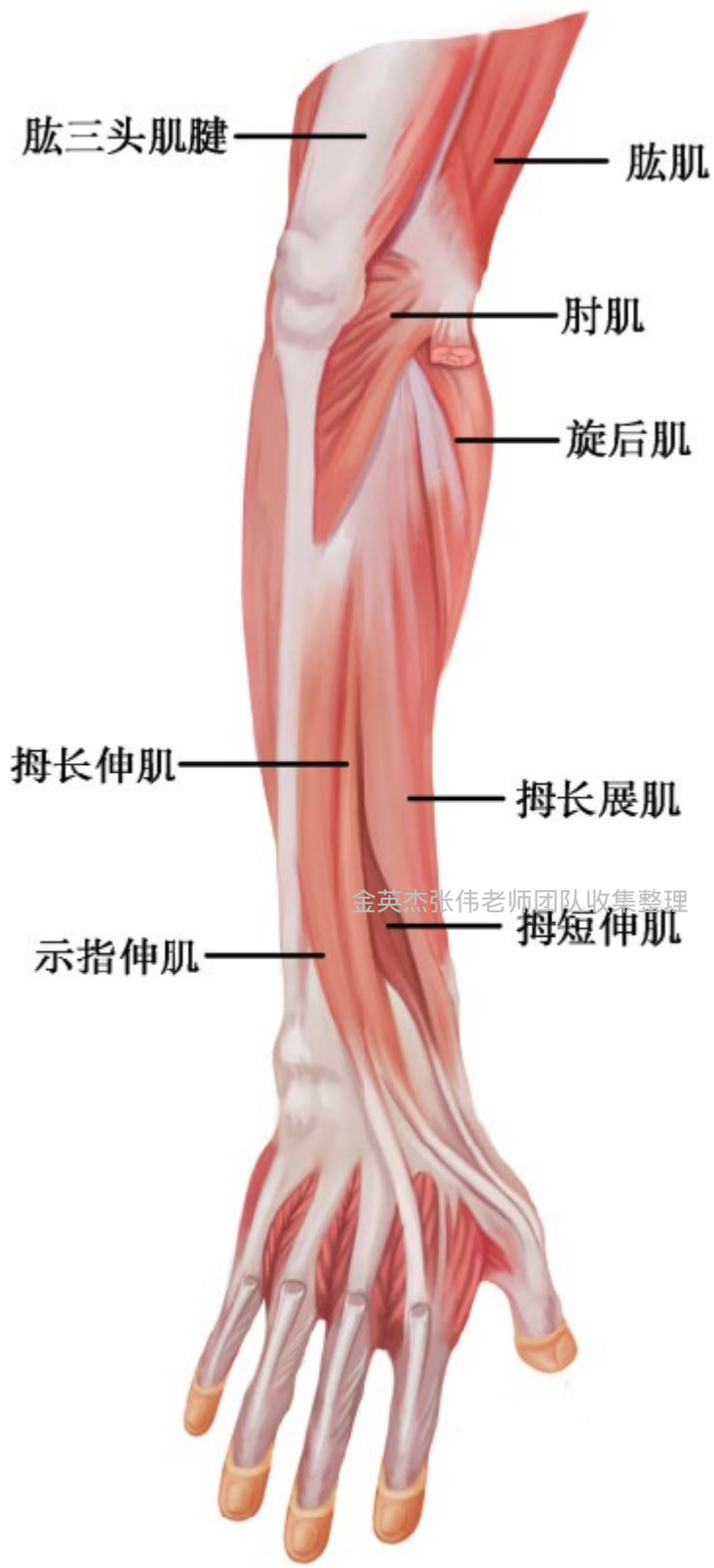
获取更多医考资料请关注





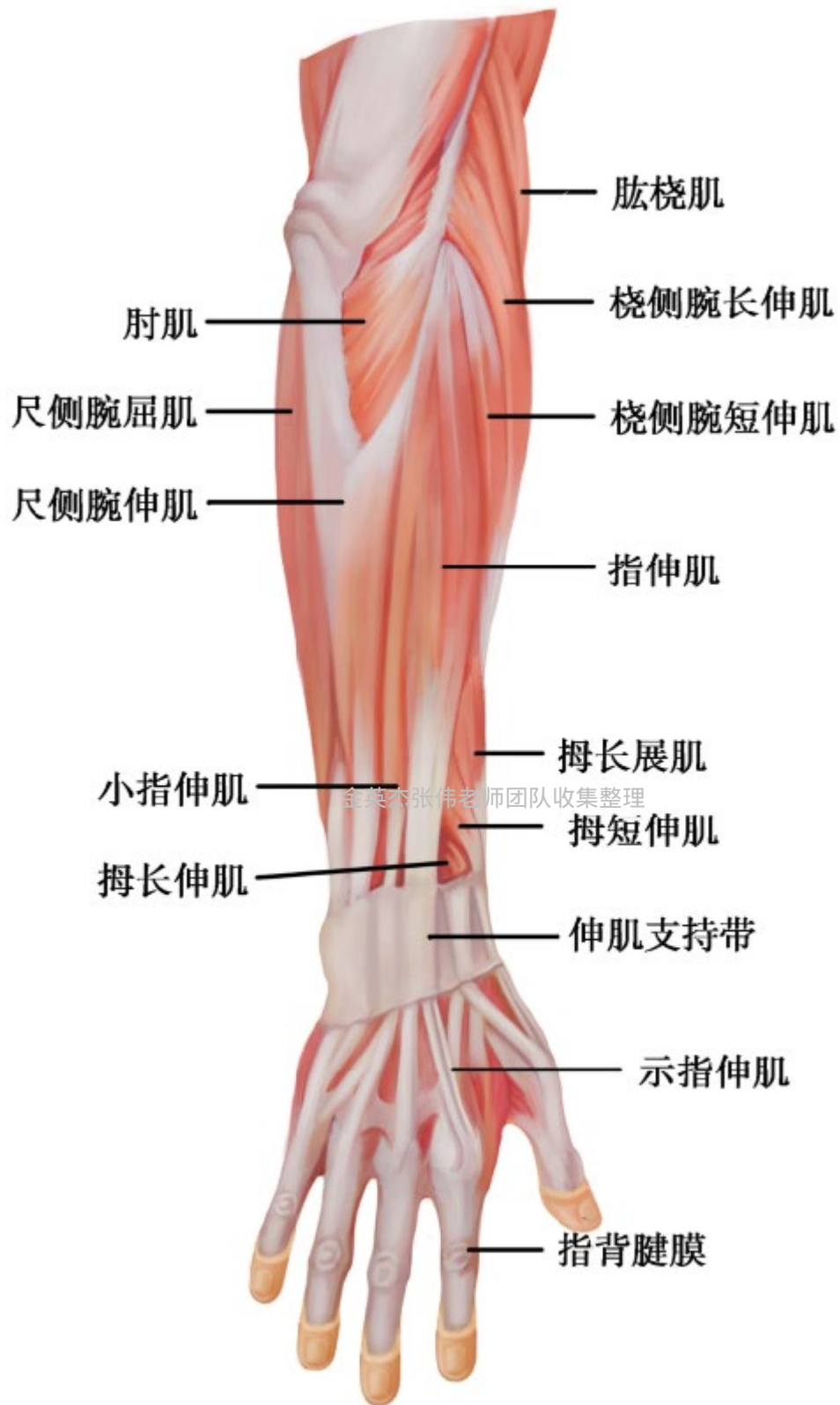
获取更多医考资料请关注





获取更多医考资料请关注





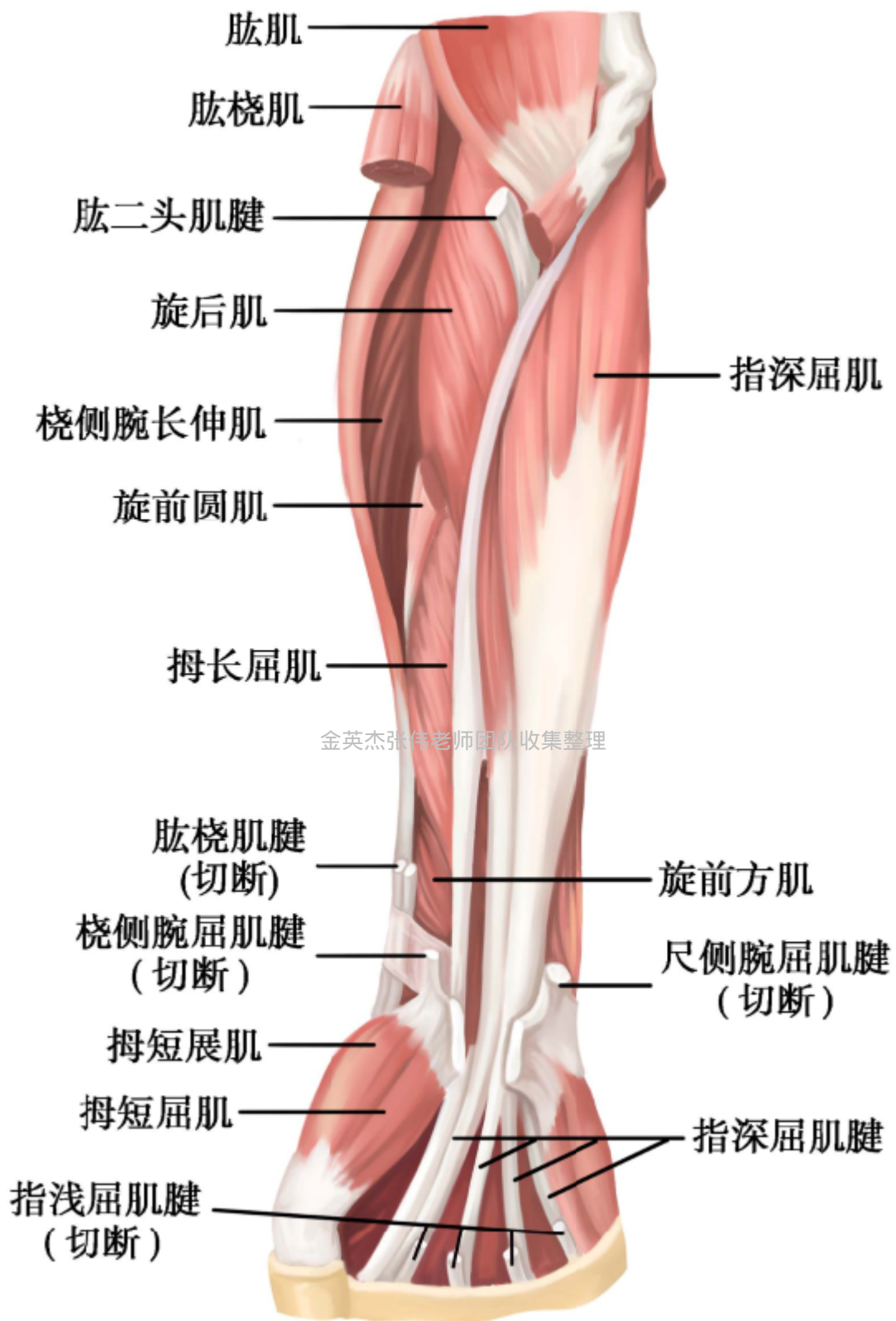
金英杰张伟老师团队收集整理



金英杰张伟老师

获取更多医考资料请关注

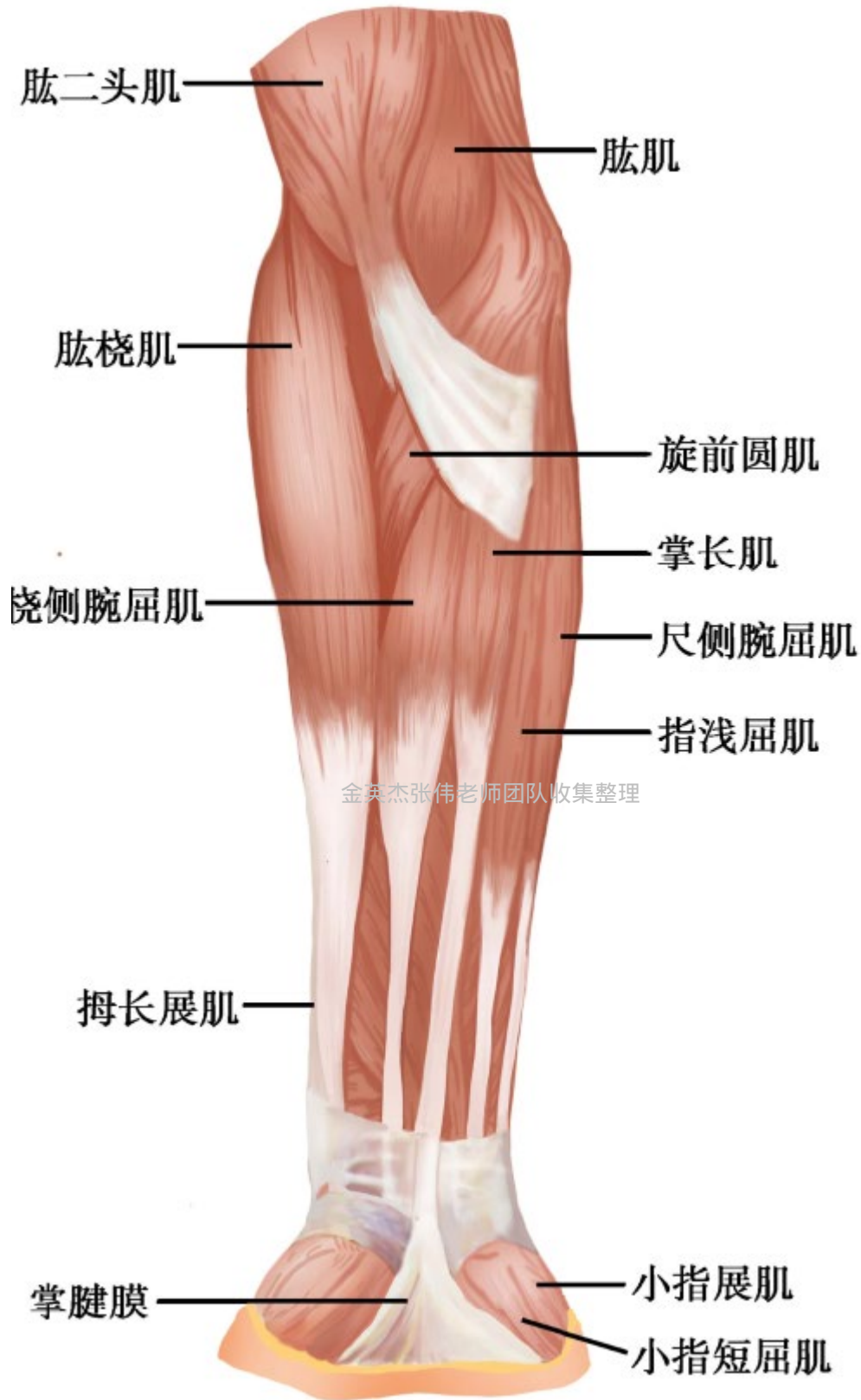




金英杰张伟老师

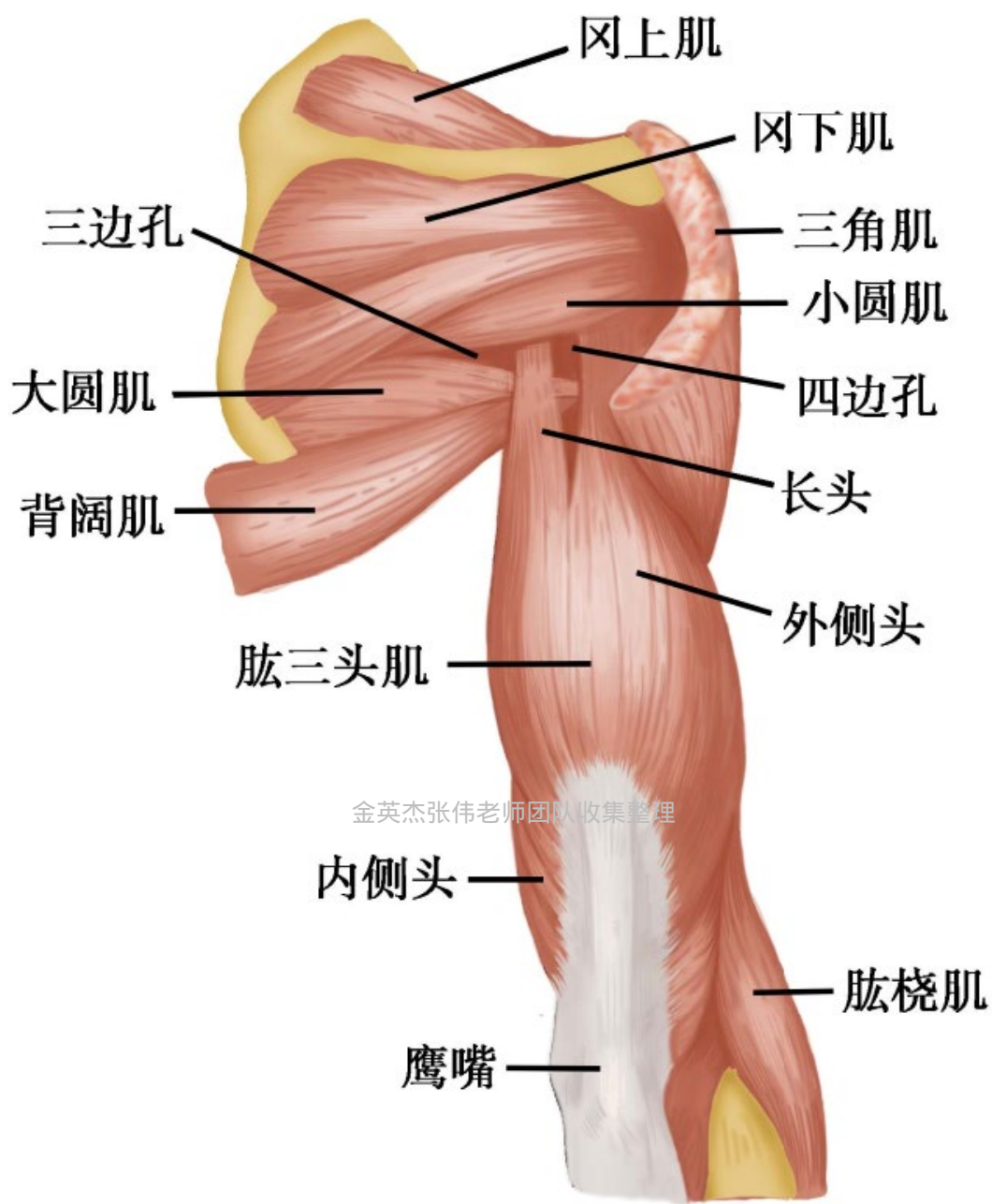
获取更多医考资料请关注





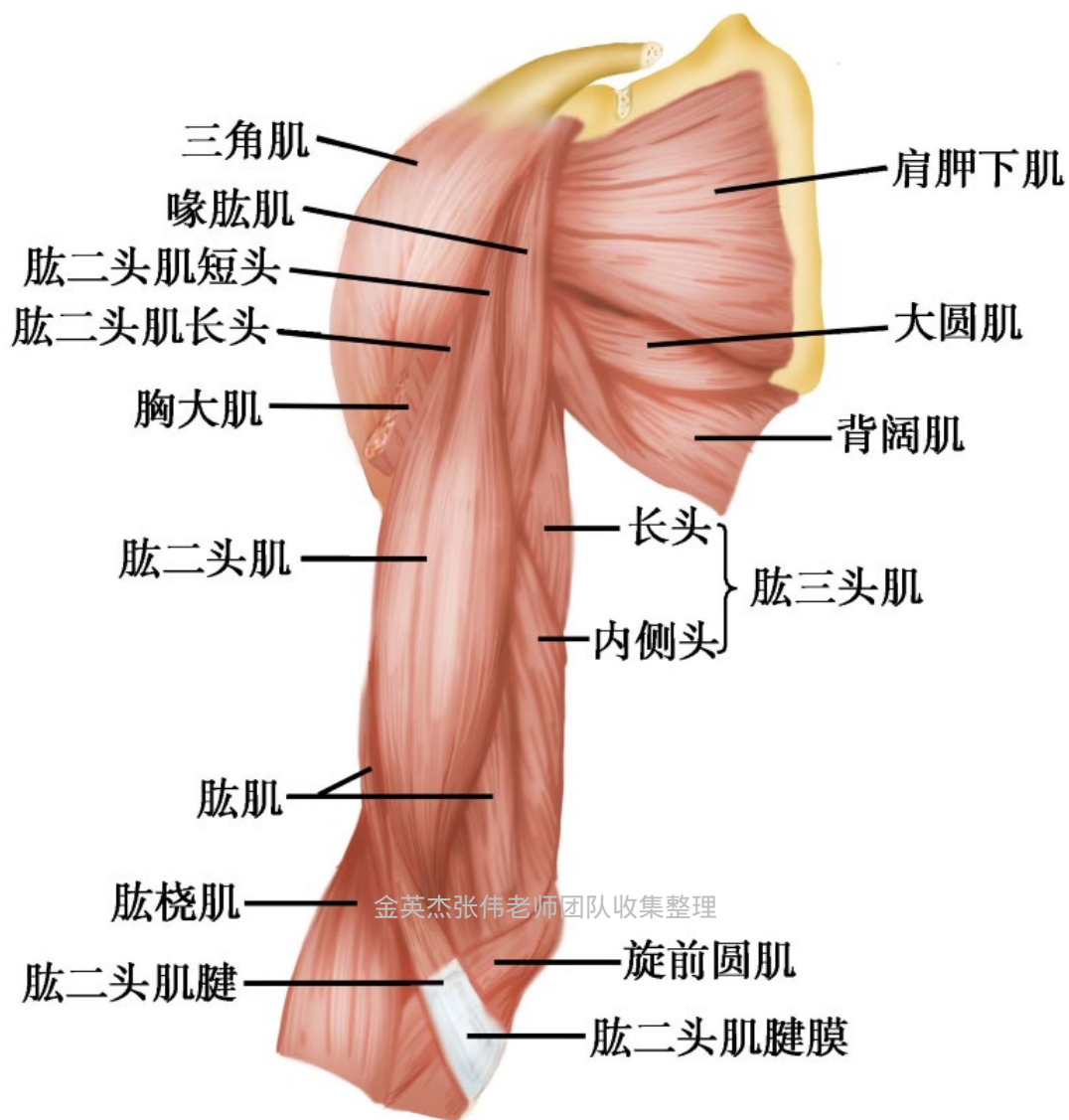
获取更多医考资料请关注





获取更多医考资料请关注

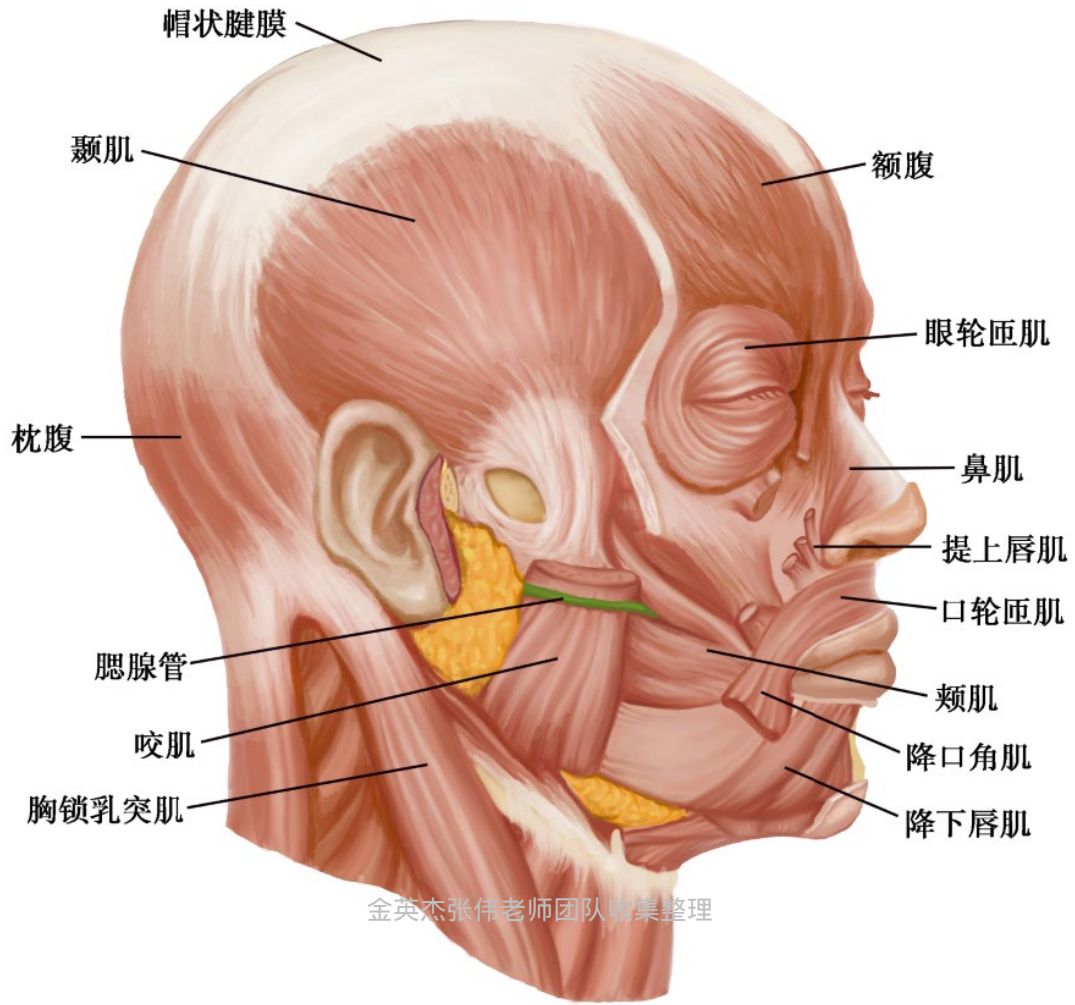




金英杰张伟老师

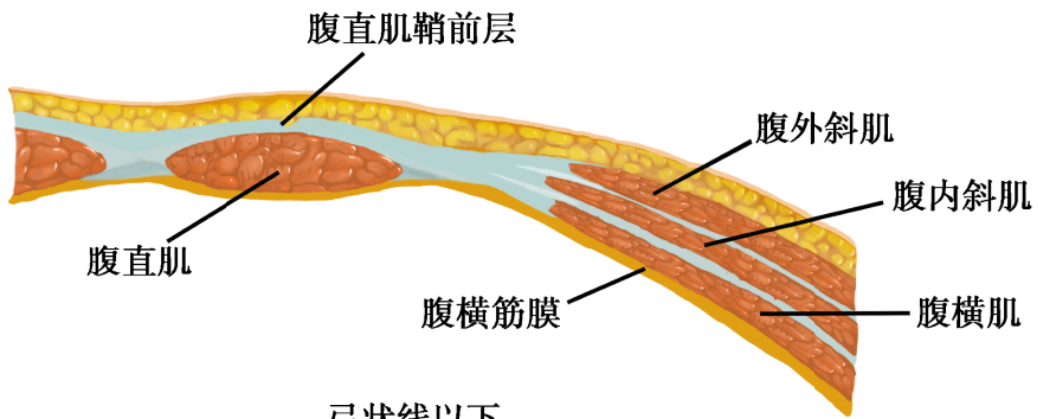
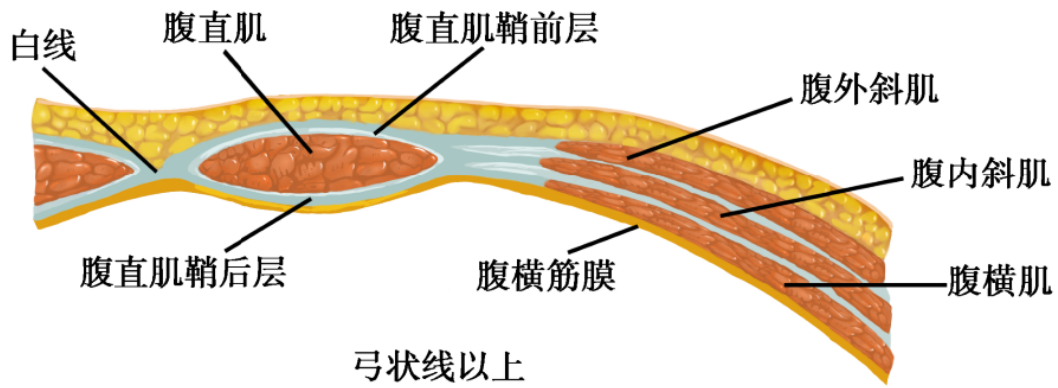
获取更多医考资料请关注



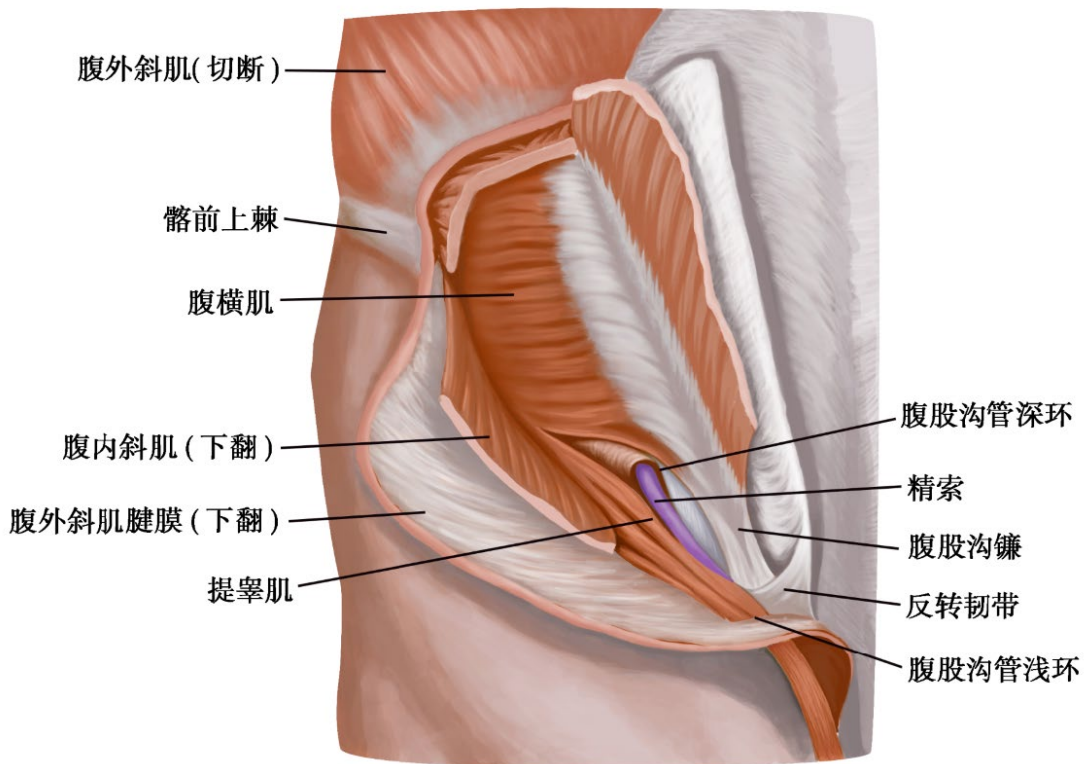


获取更多医考资料请关注



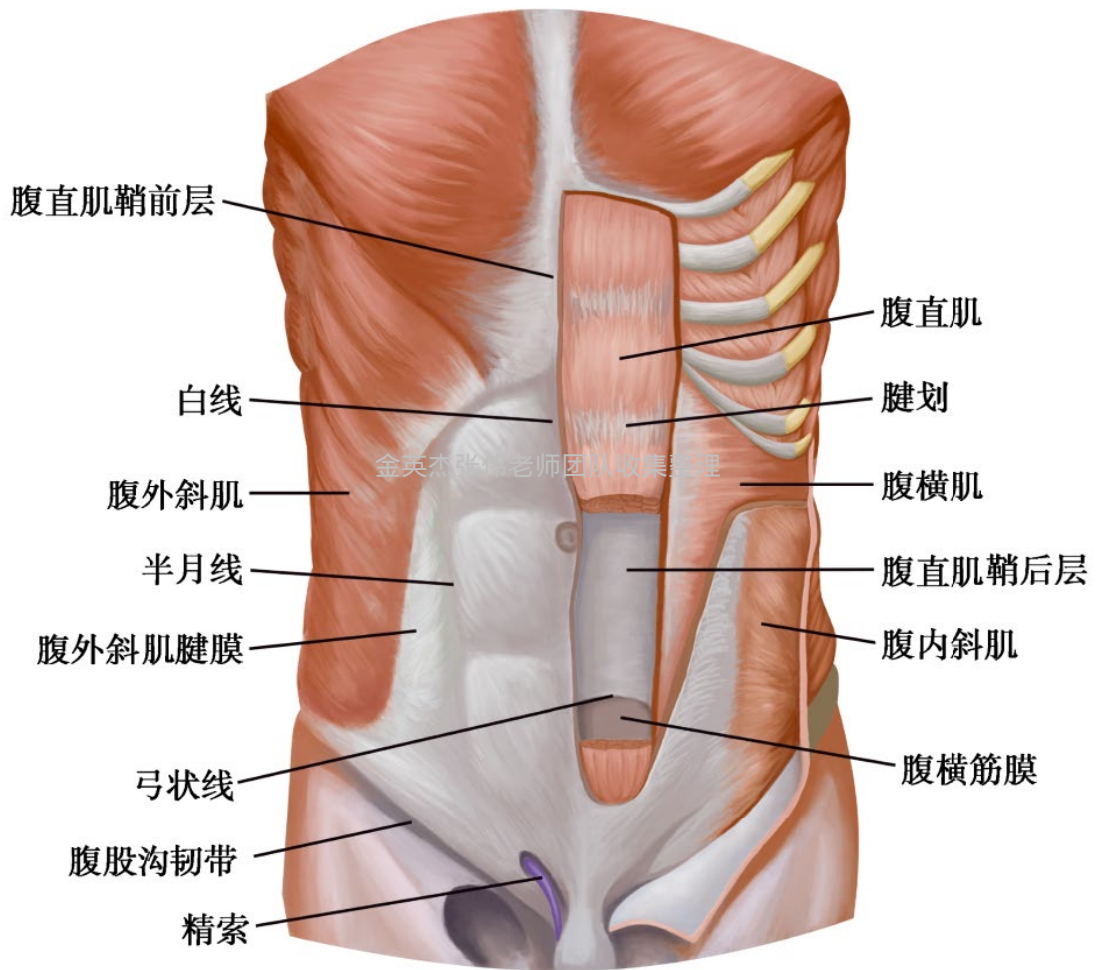
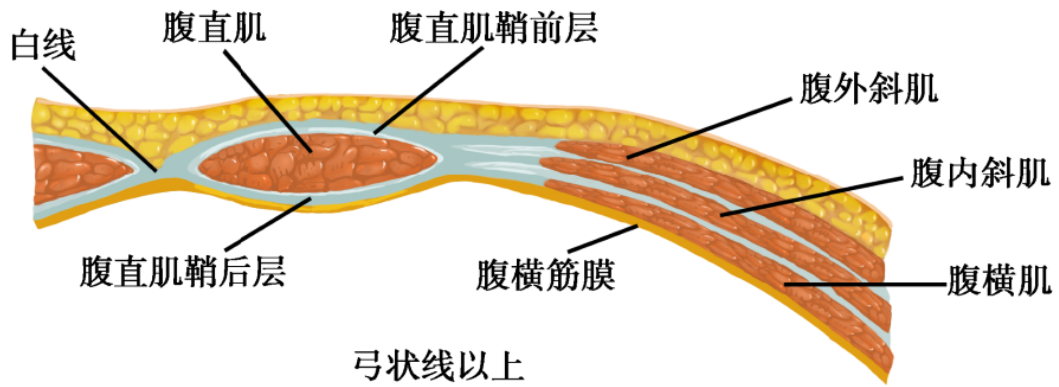


金英杰张伟老师团队收集整理



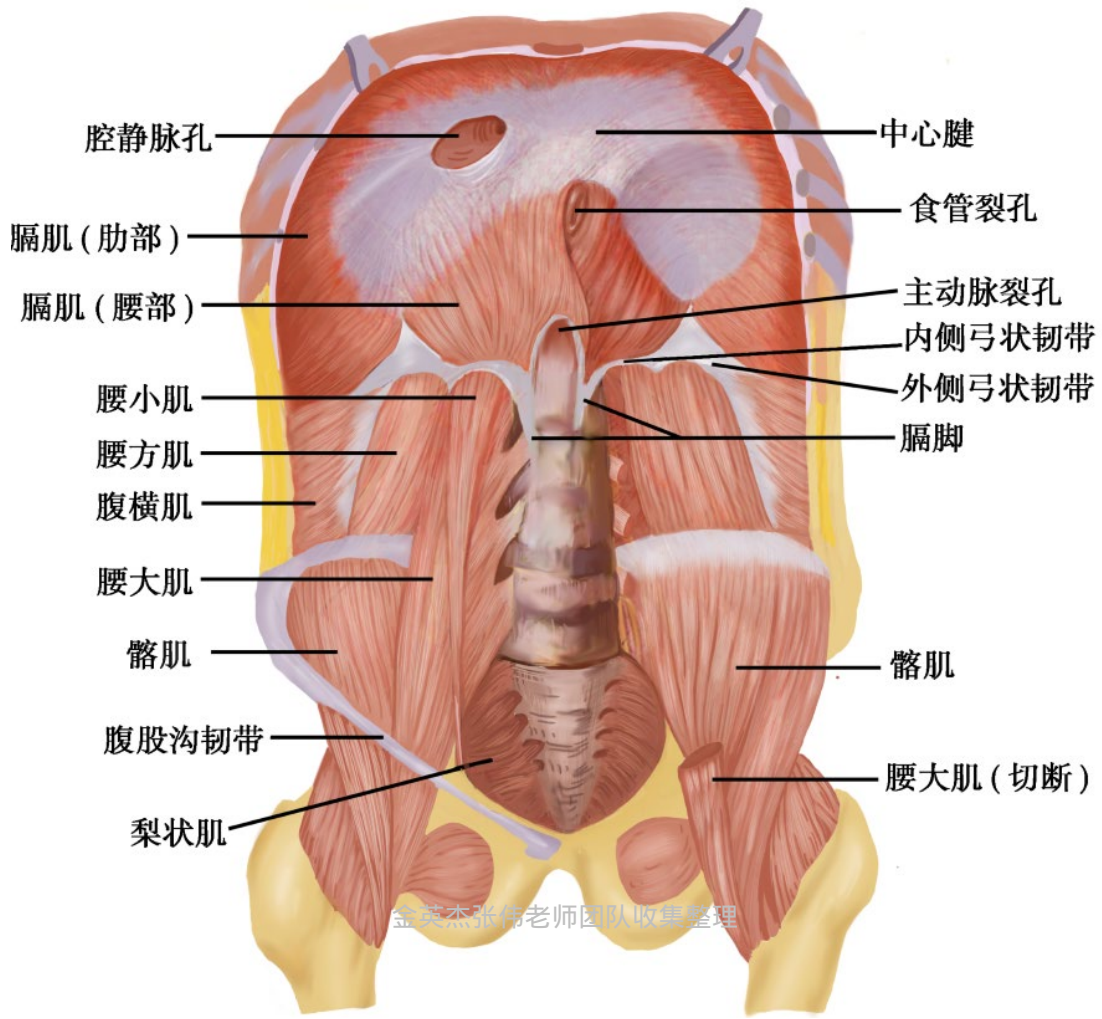
获取更多医考资料请关注





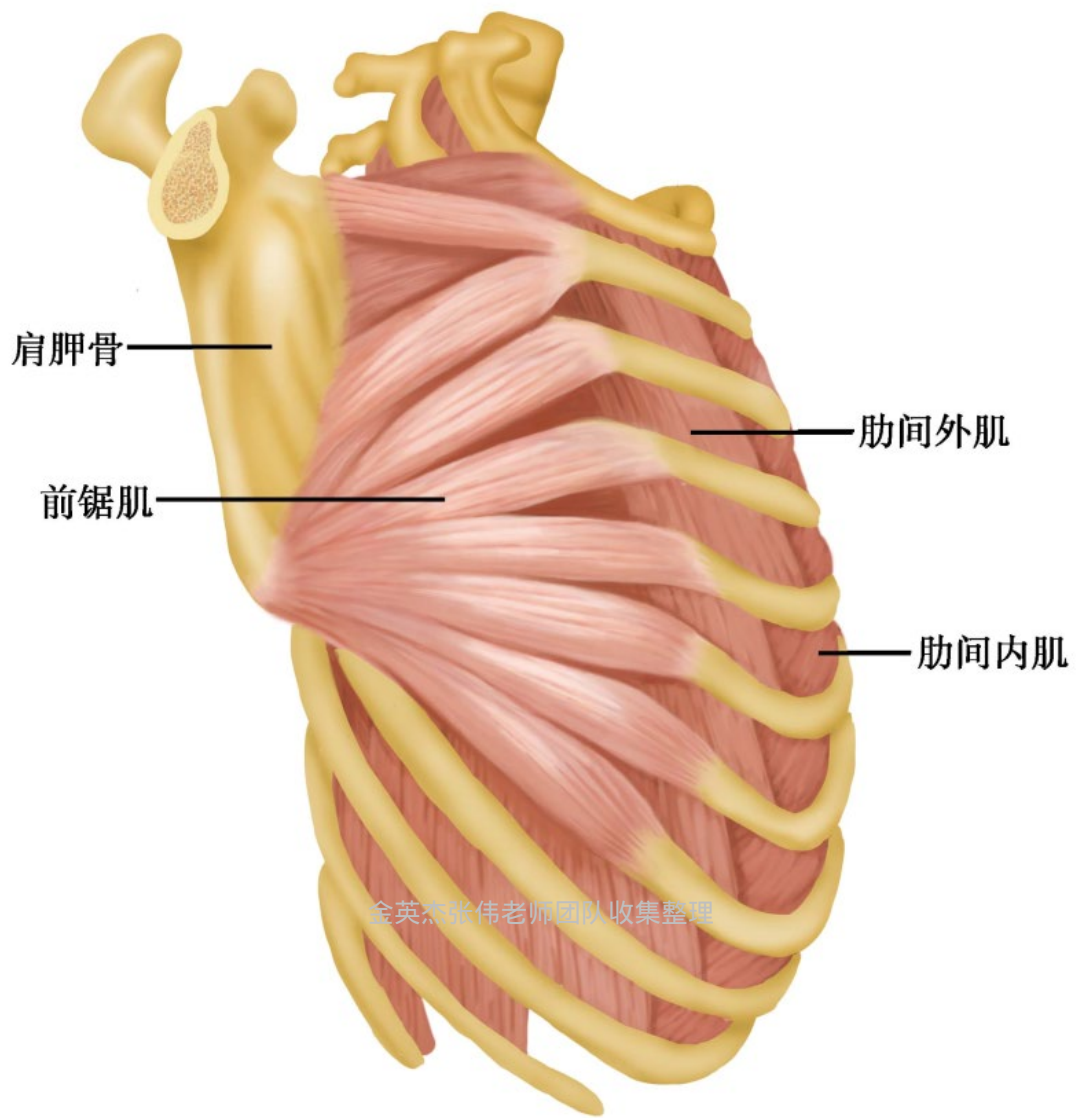
获取更多医考资料请关注





获取更多医考资料请关注



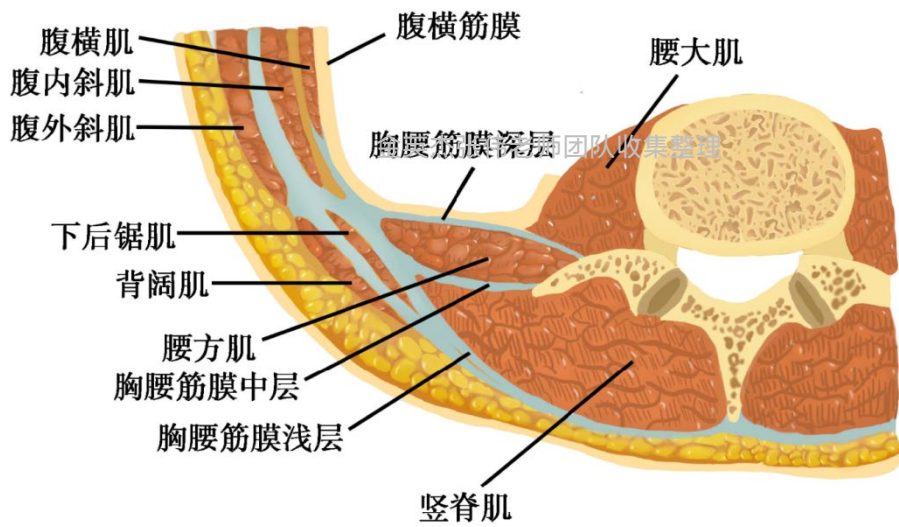
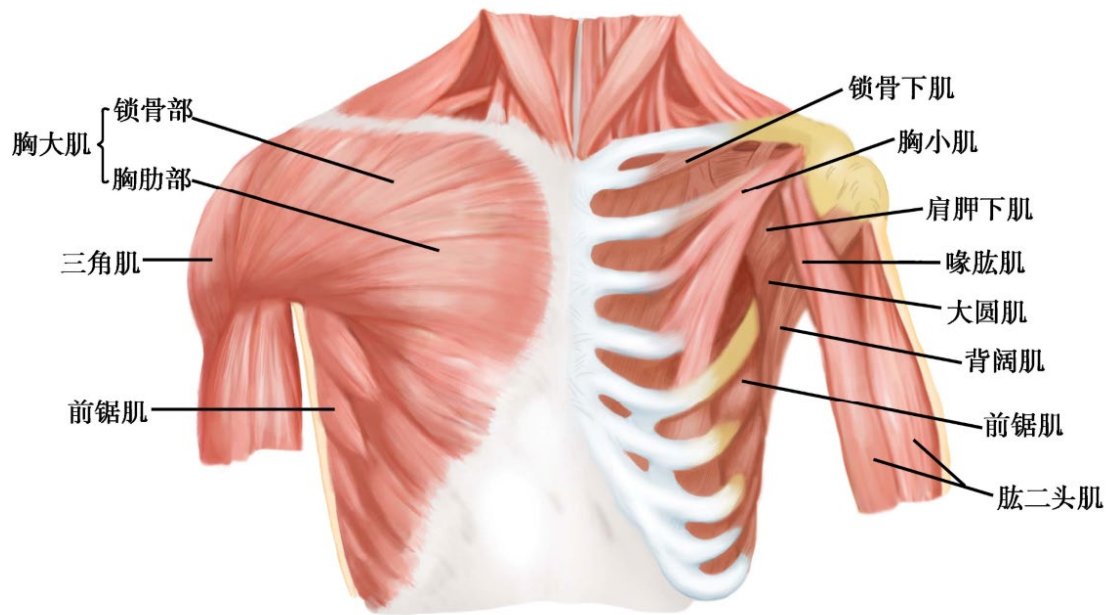


金英杰张伟老师团队收集整理



获取更多医考资料请关注

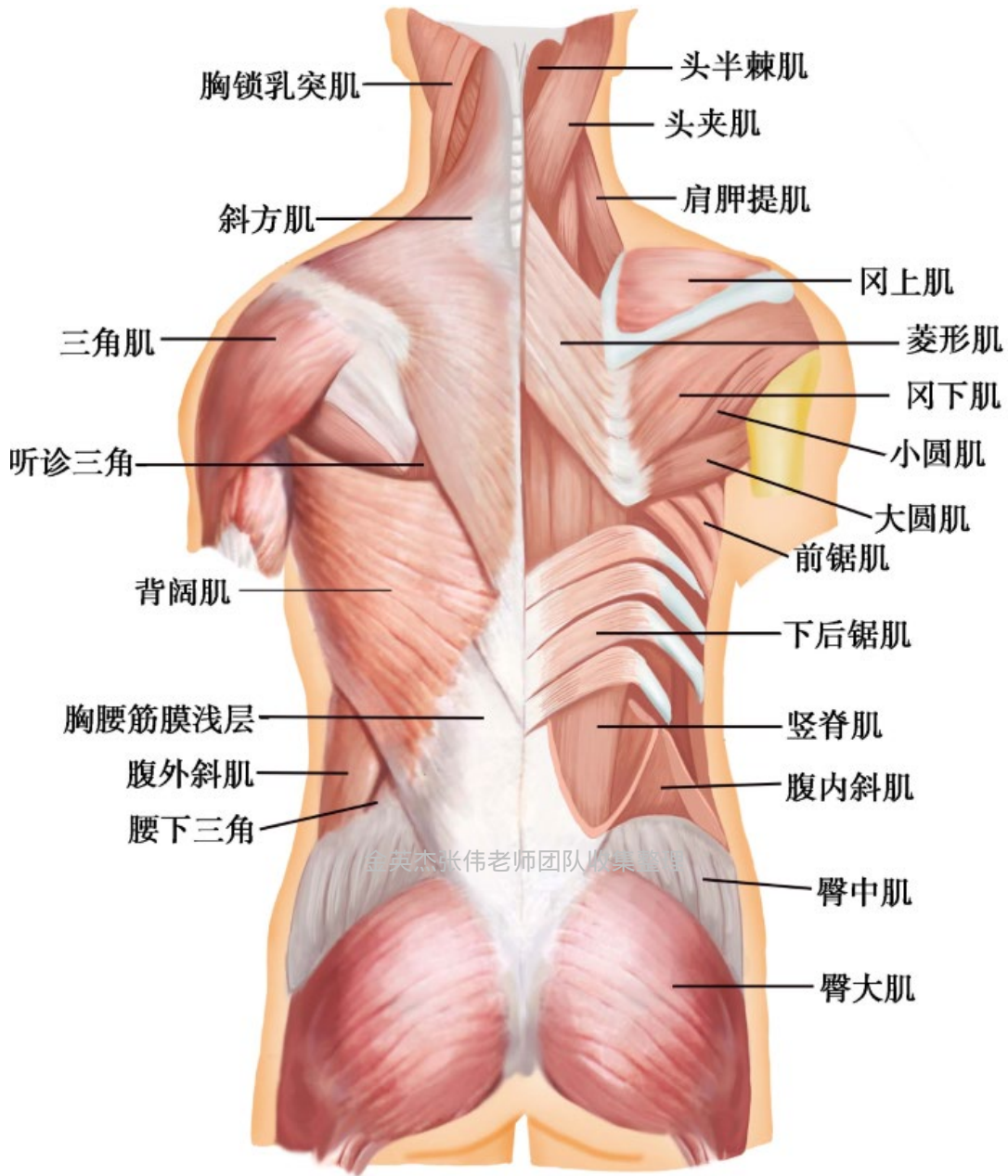




金英杰张伟老师

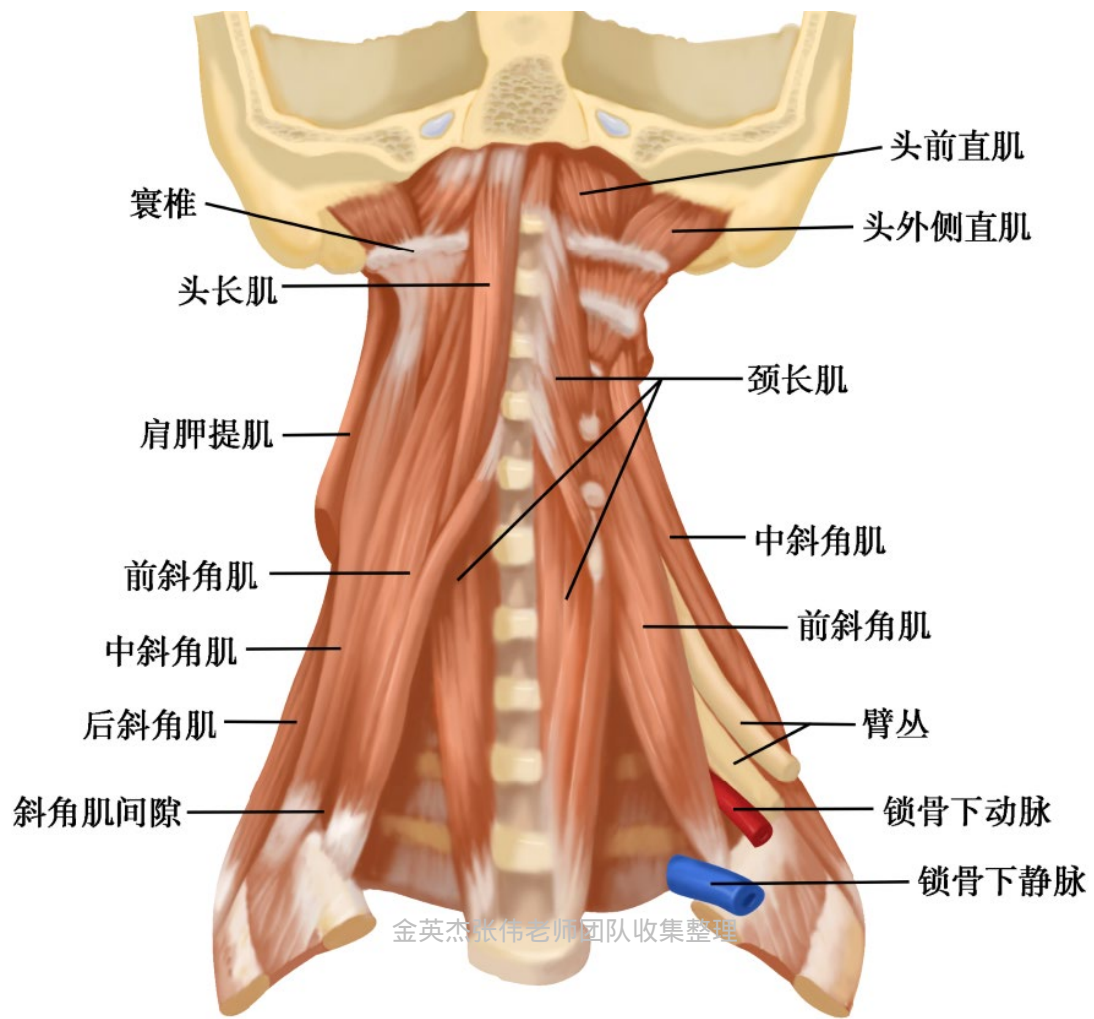
获取更多医考资料请关注





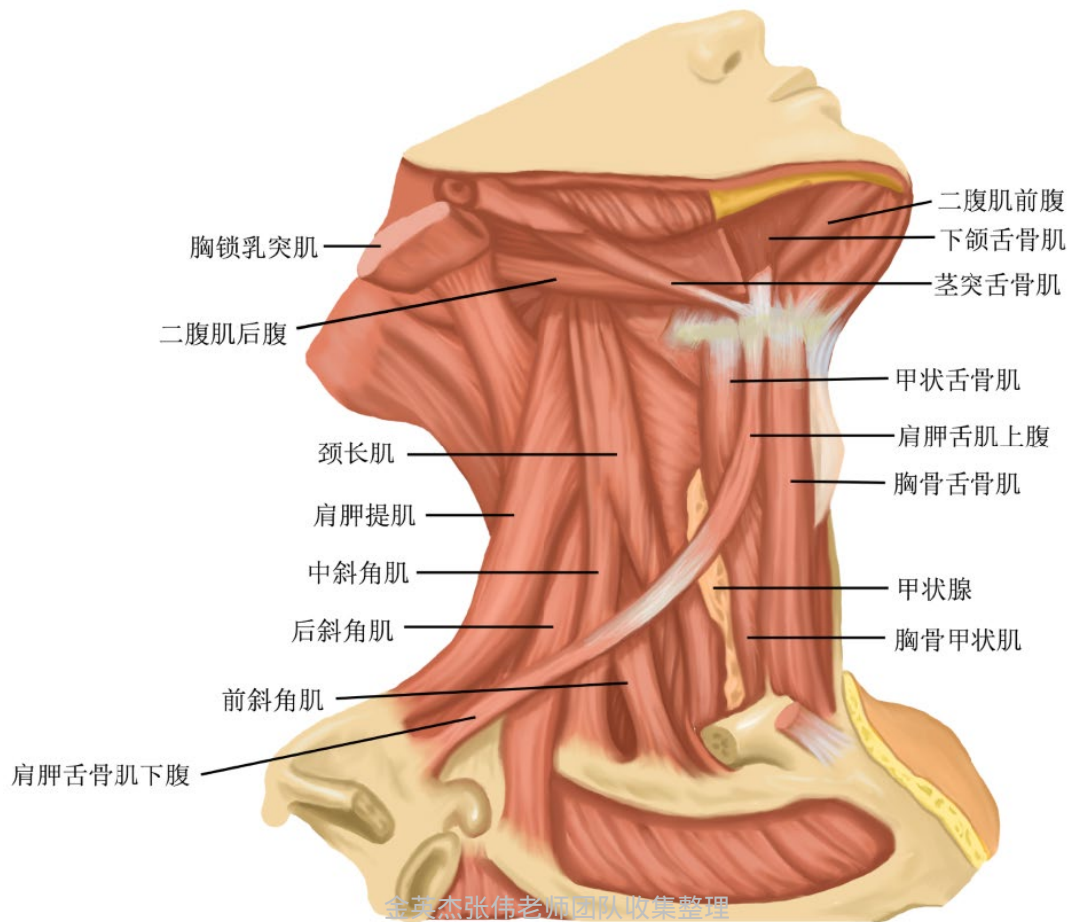
获取更多医考资料请关注



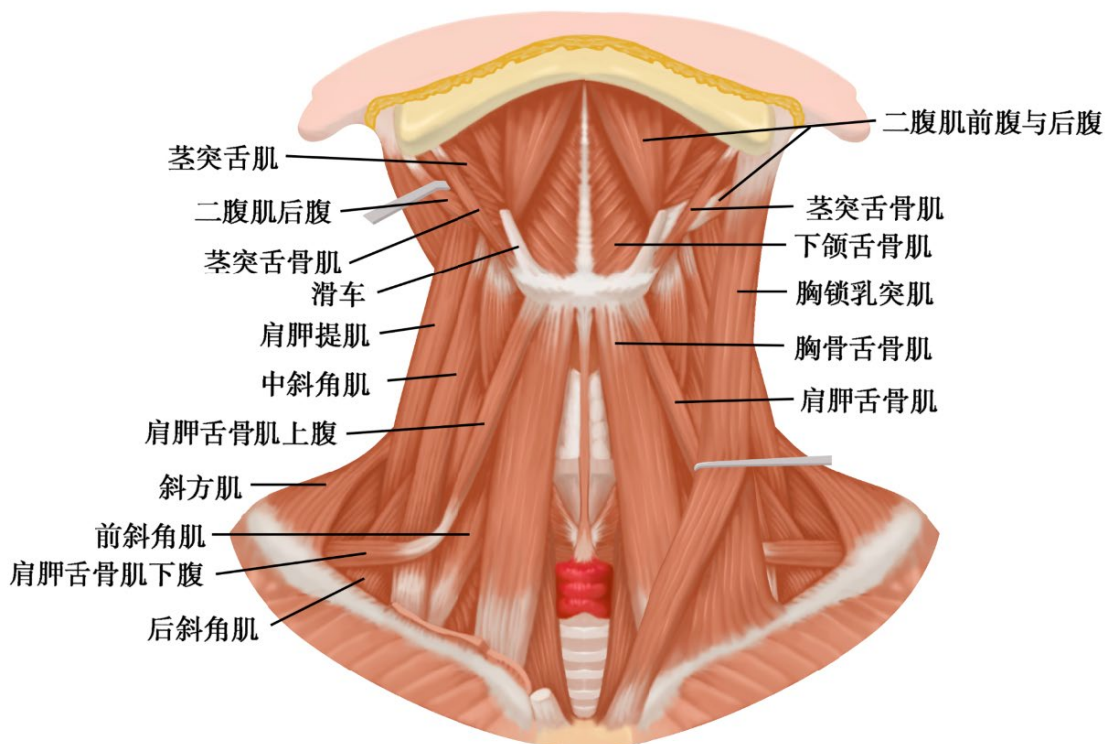


获取更多医考资料请关注



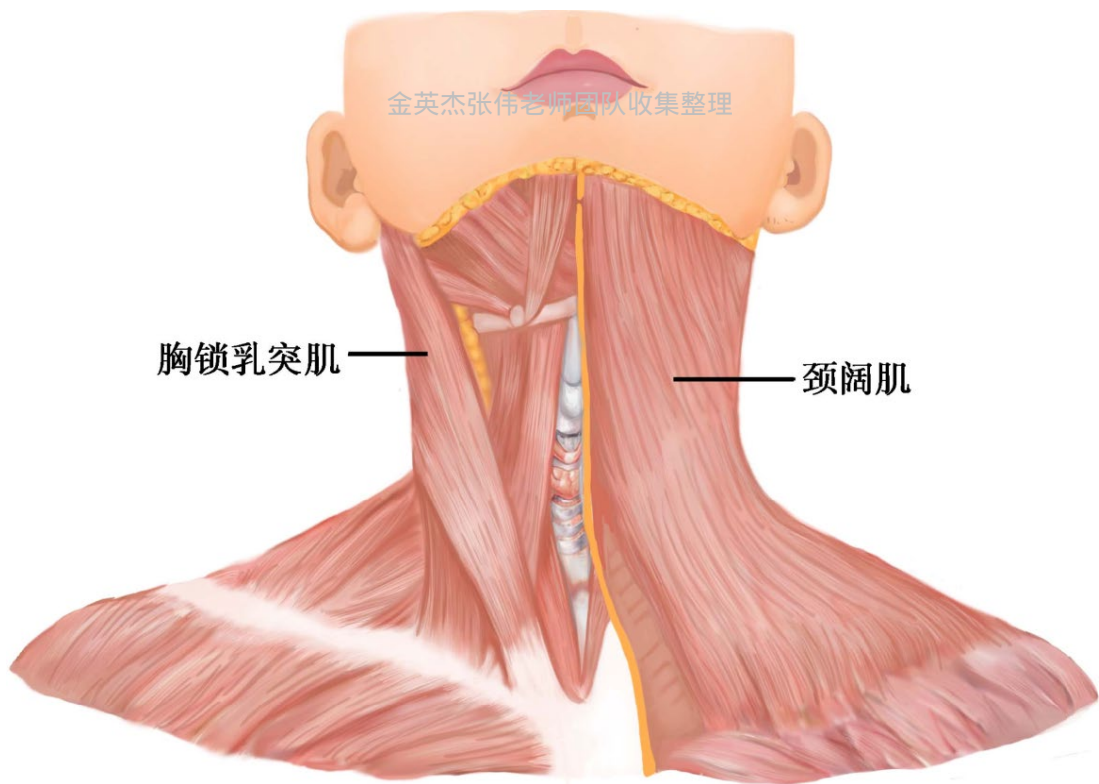
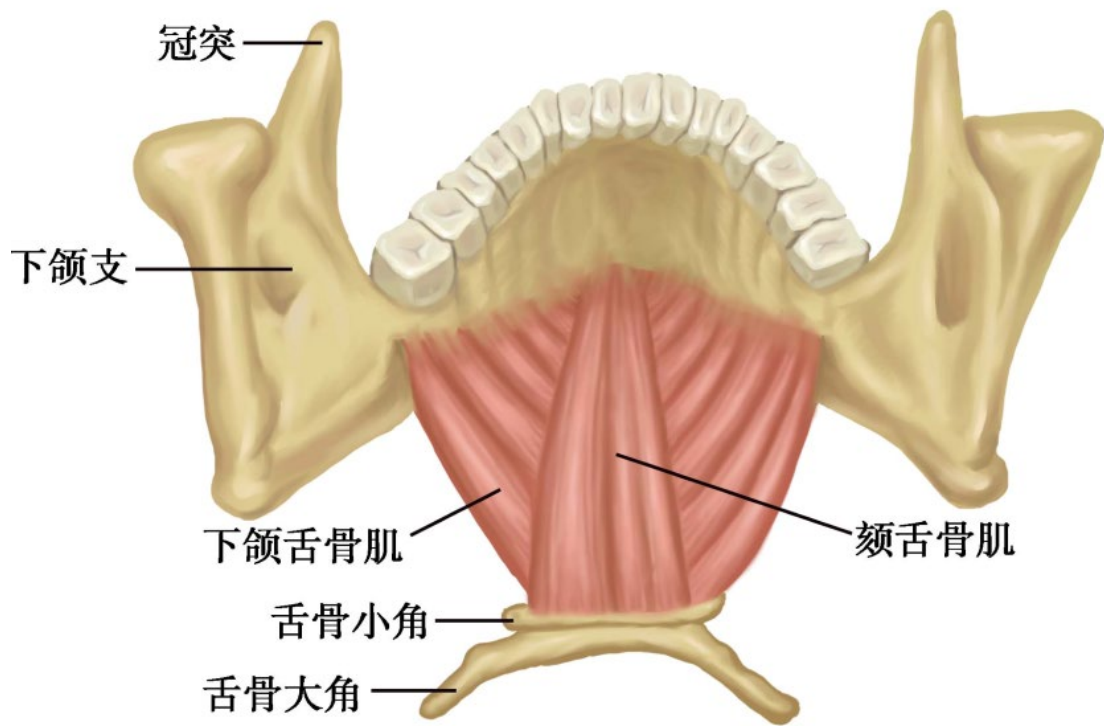


金英杰张伟老师



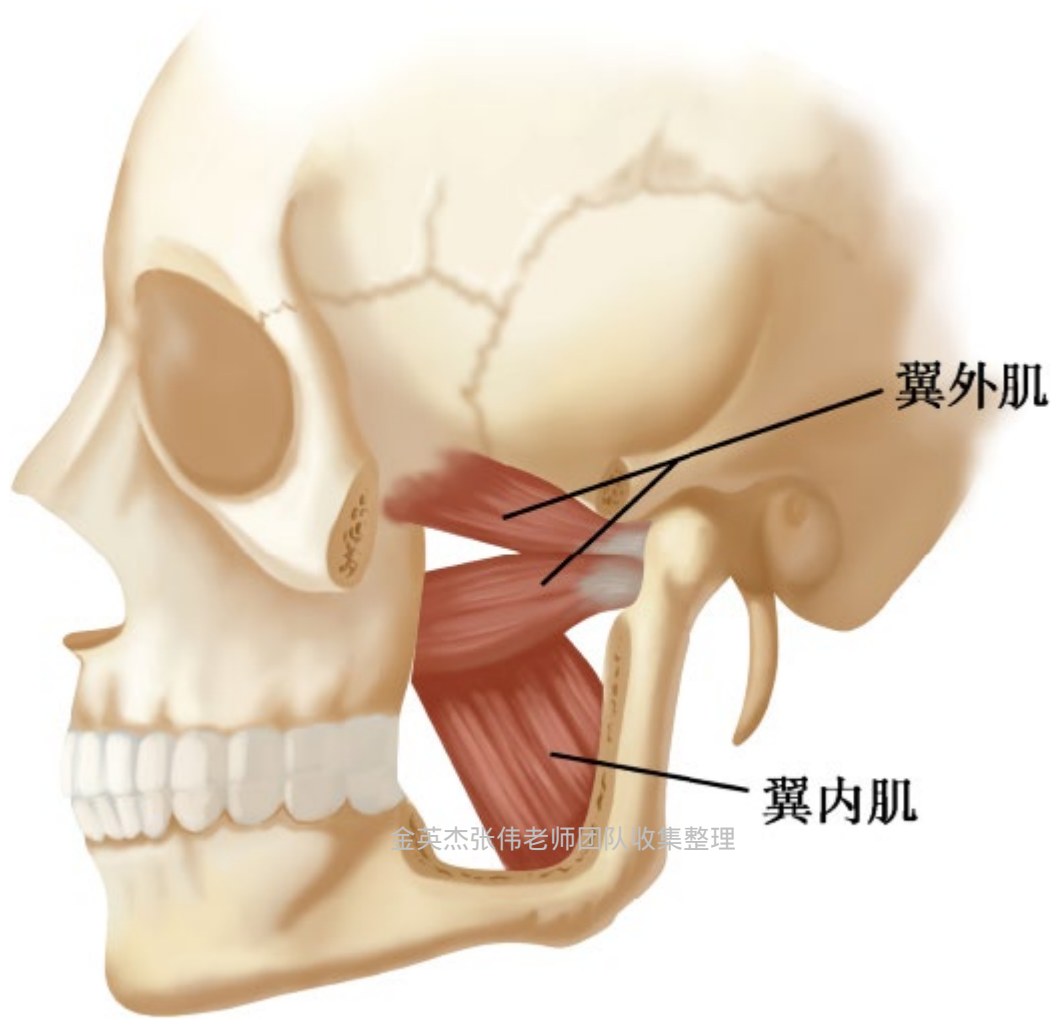
获取更多医考资料请关注





获取更多医考资料请关注





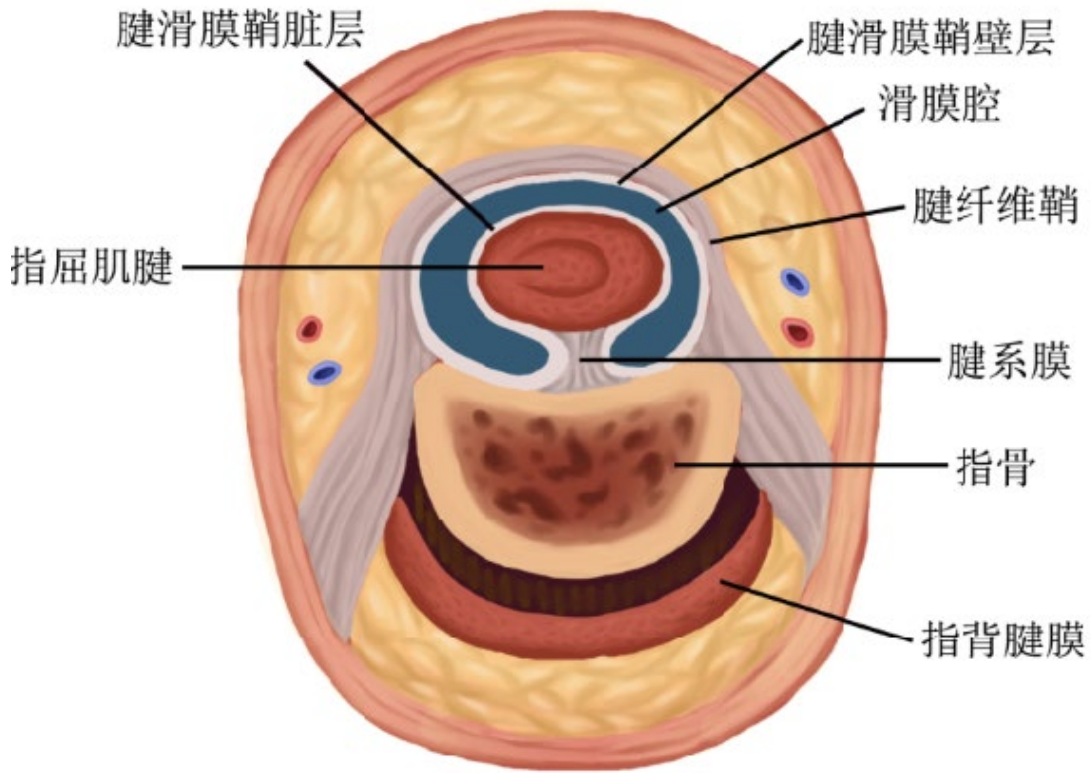
金英杰张伟老师团队收集整理



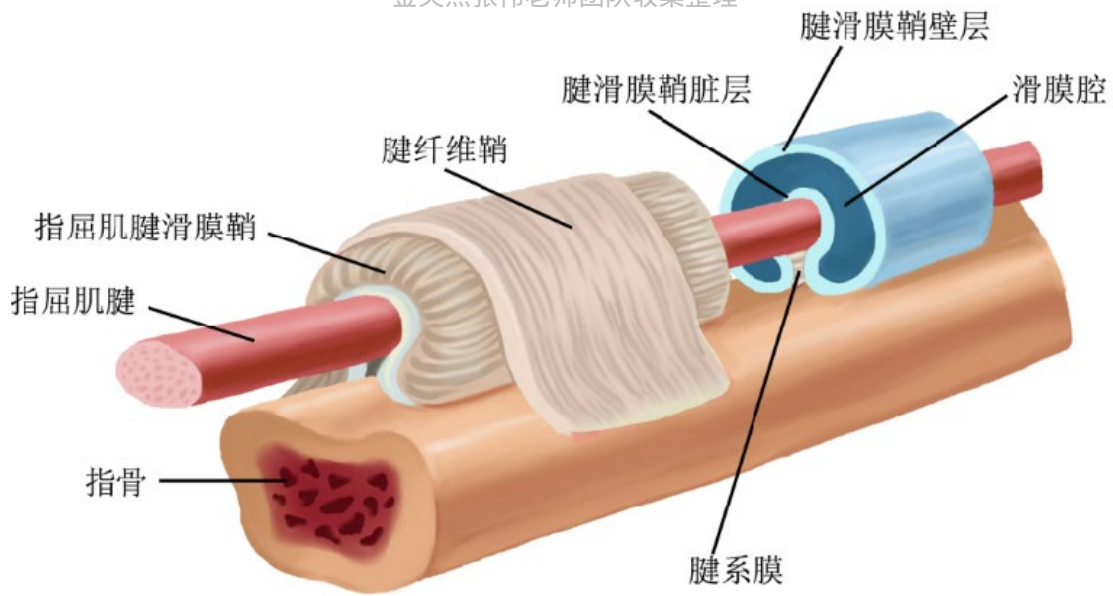
金英杰张伟老师

获取更多医考资料请关注





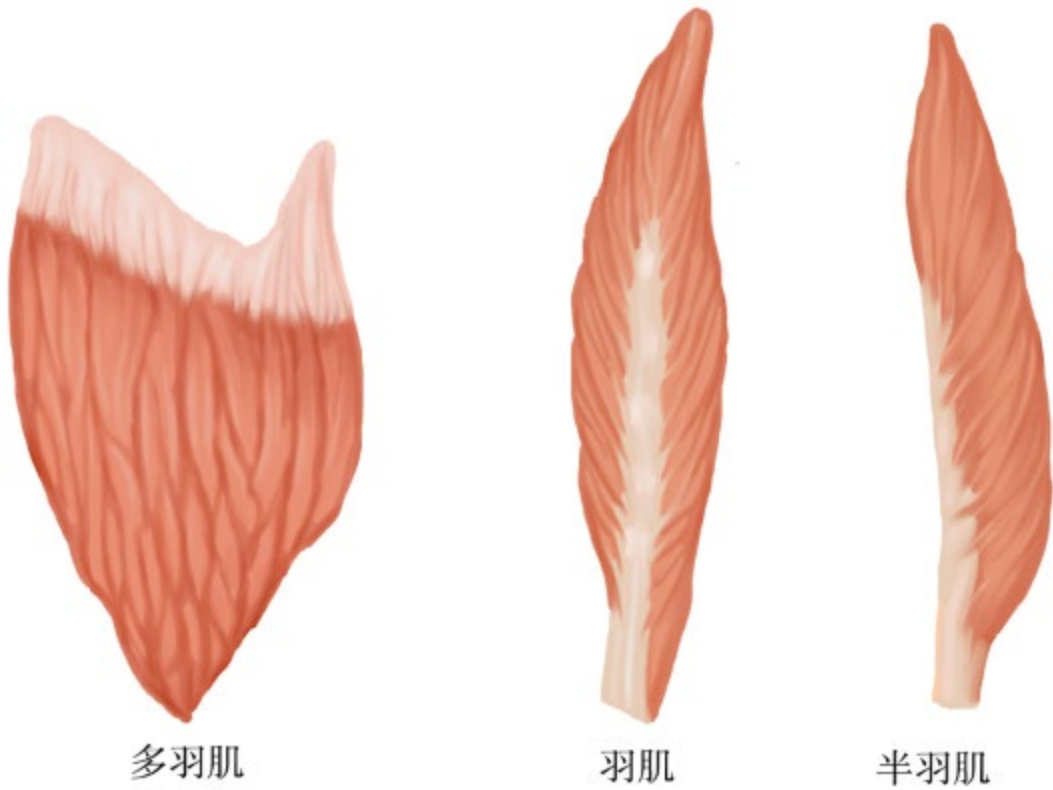
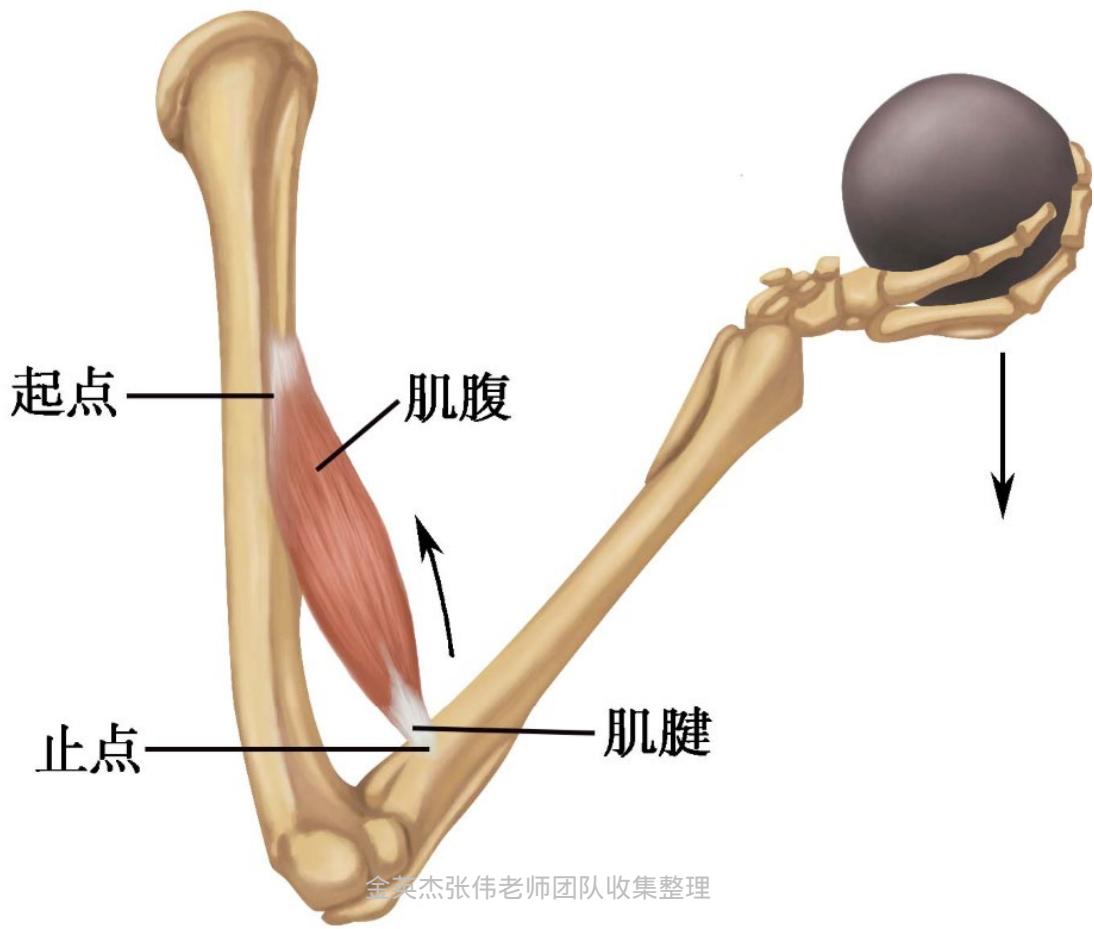
金英杰张伟老师团队收集整理



金英杰张伟老师

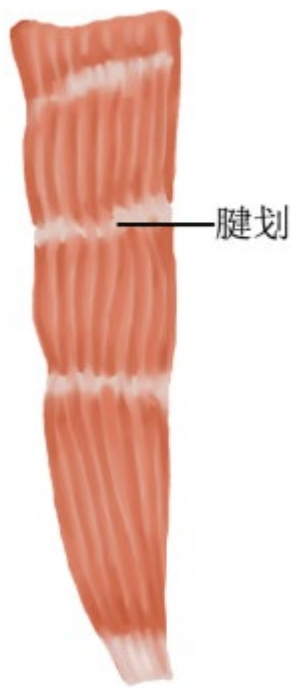
获取更多医考资料请关注



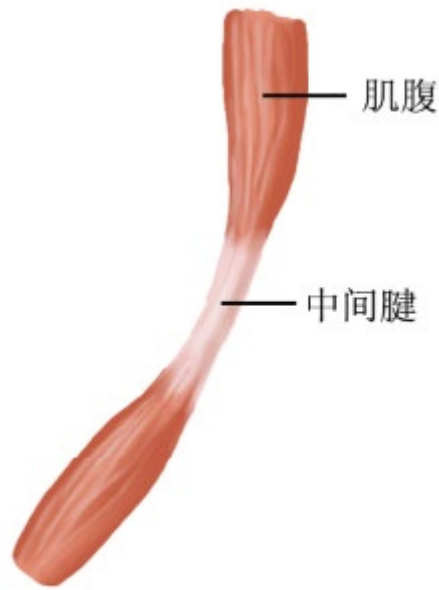


获取更多医考资料请关注

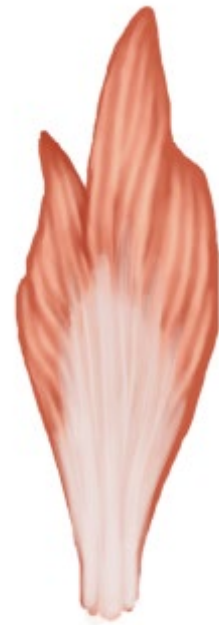



多腹肌

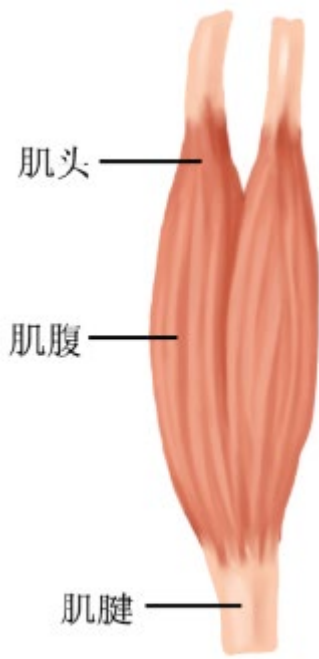


二腹肌



三头肌

金英杰张伟老师团队收集整理



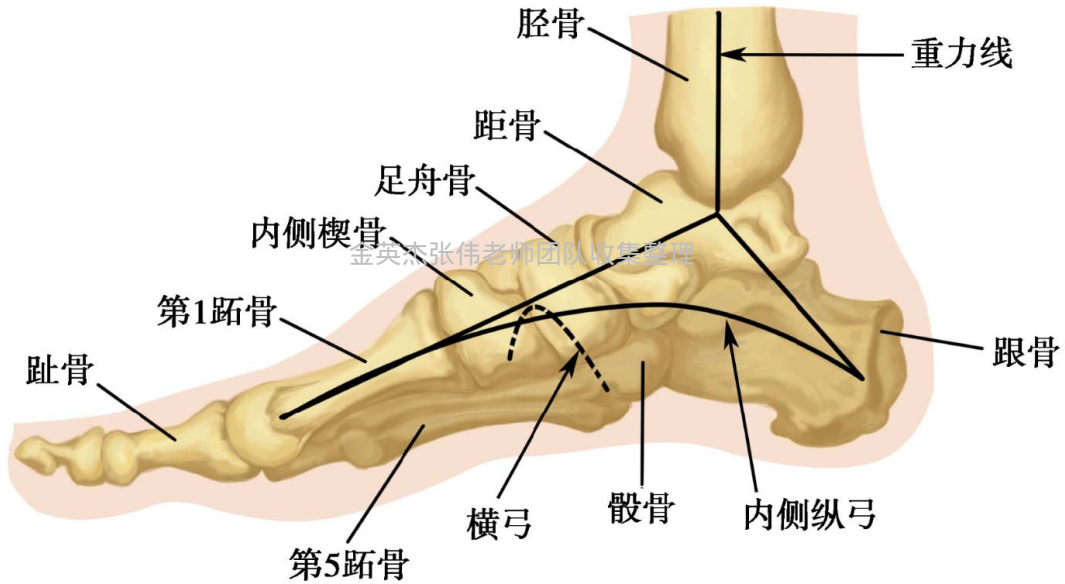
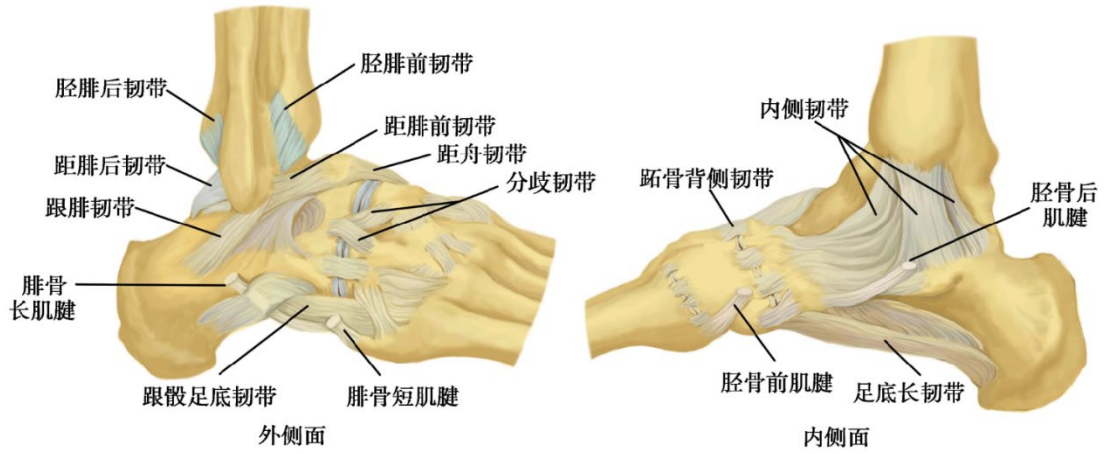
二头肌



获取更多医考资料请关注



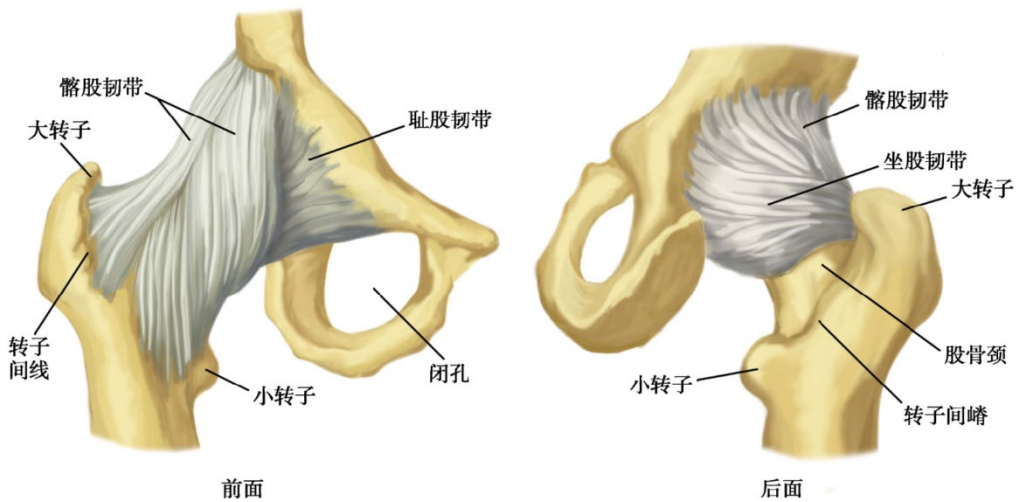
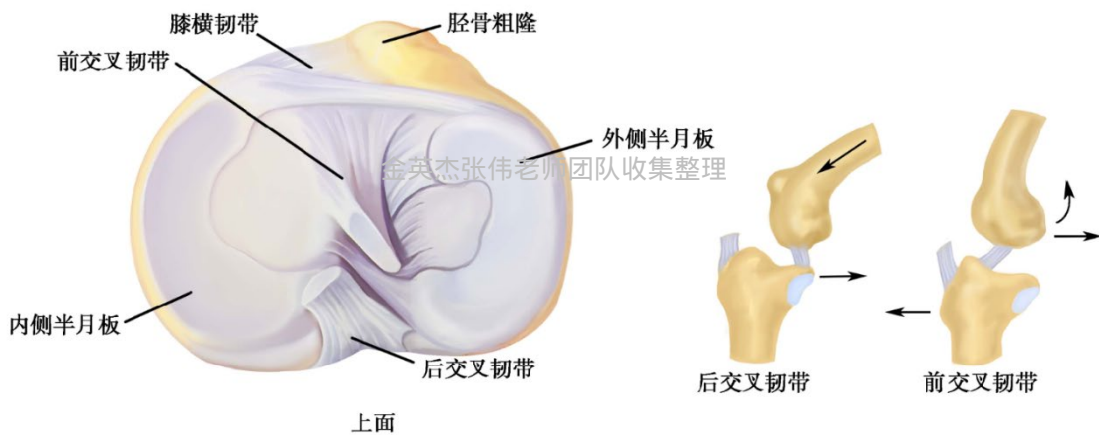
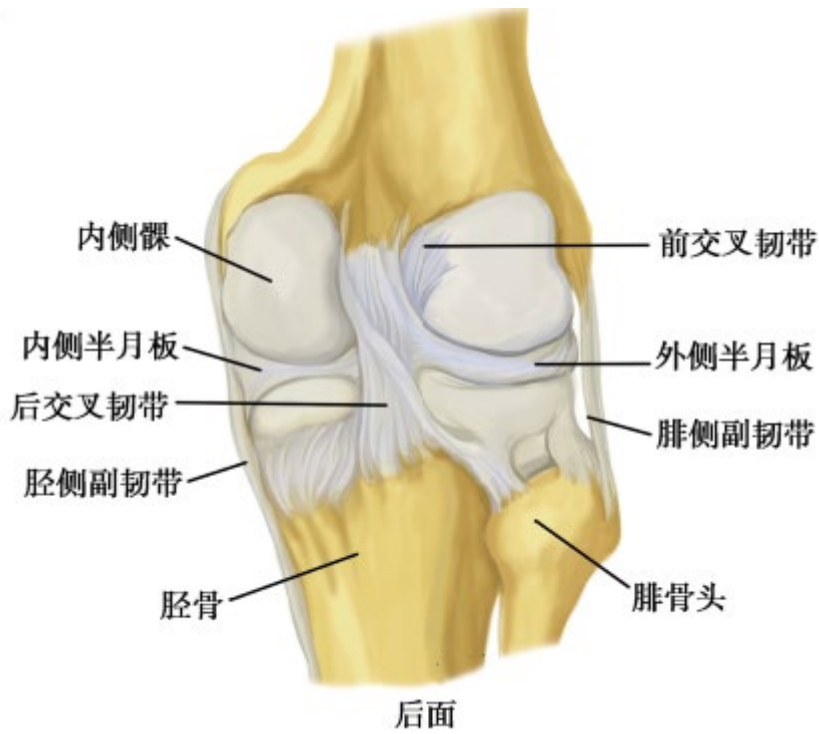
关节学



金英杰张伟老师

获取更多医考资料请关注

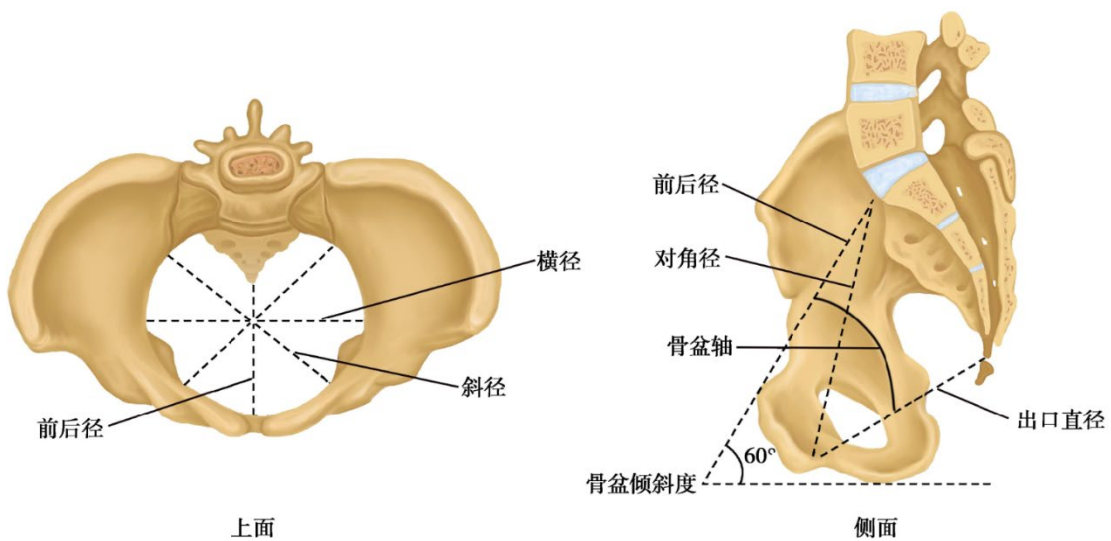
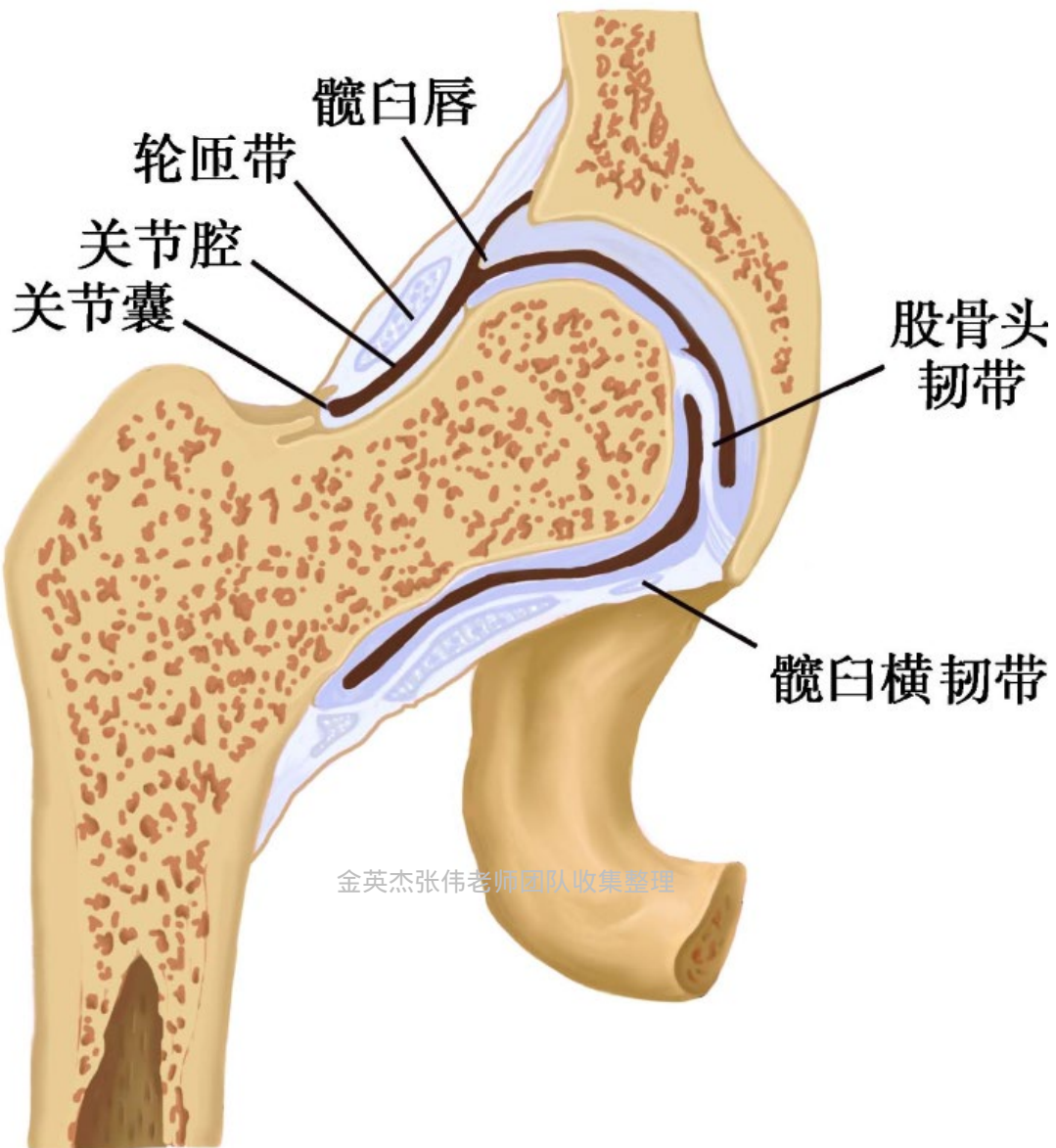




金英杰张伟老师

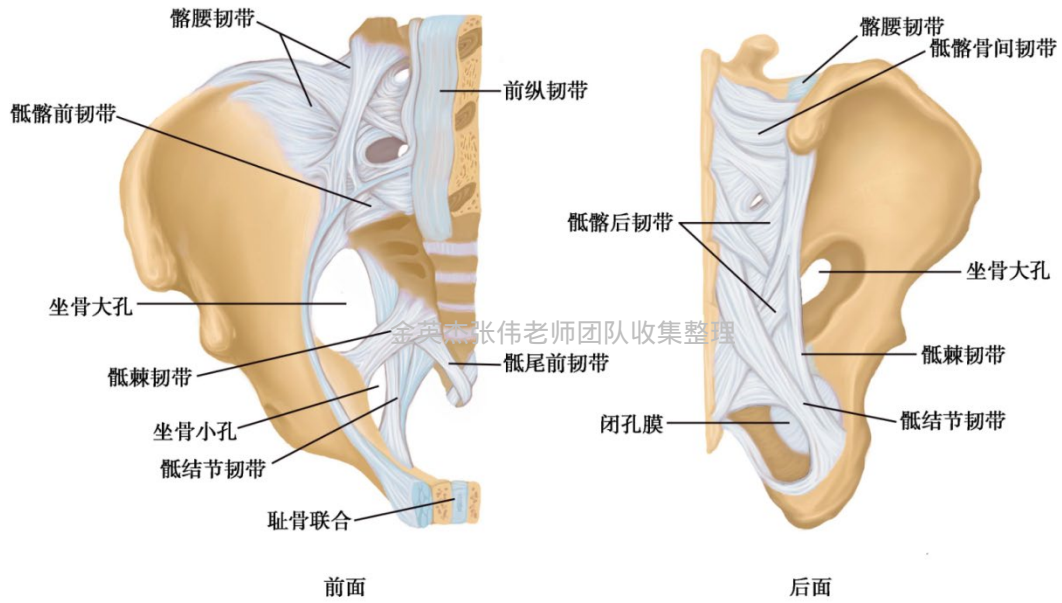
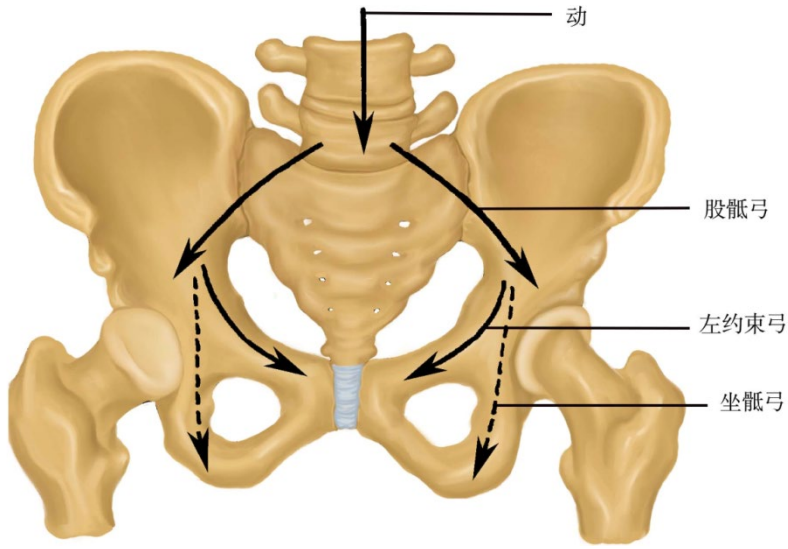
获取更多医考资料请关注





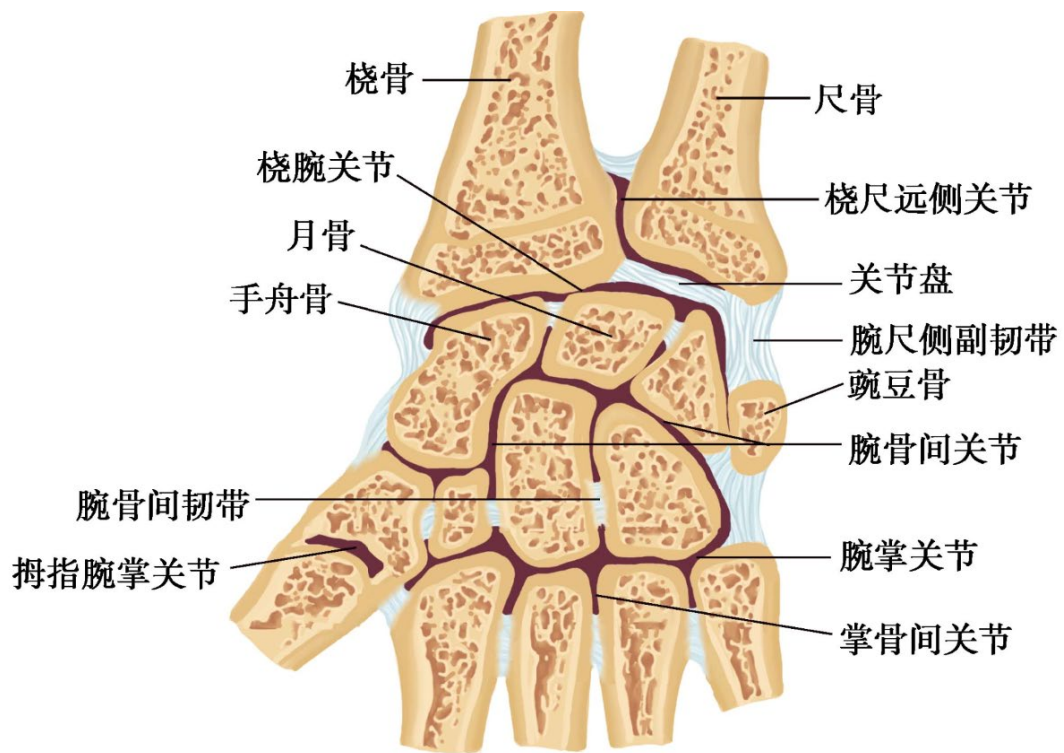
获取更多医考资料请关注





获取更多医考资料请关注



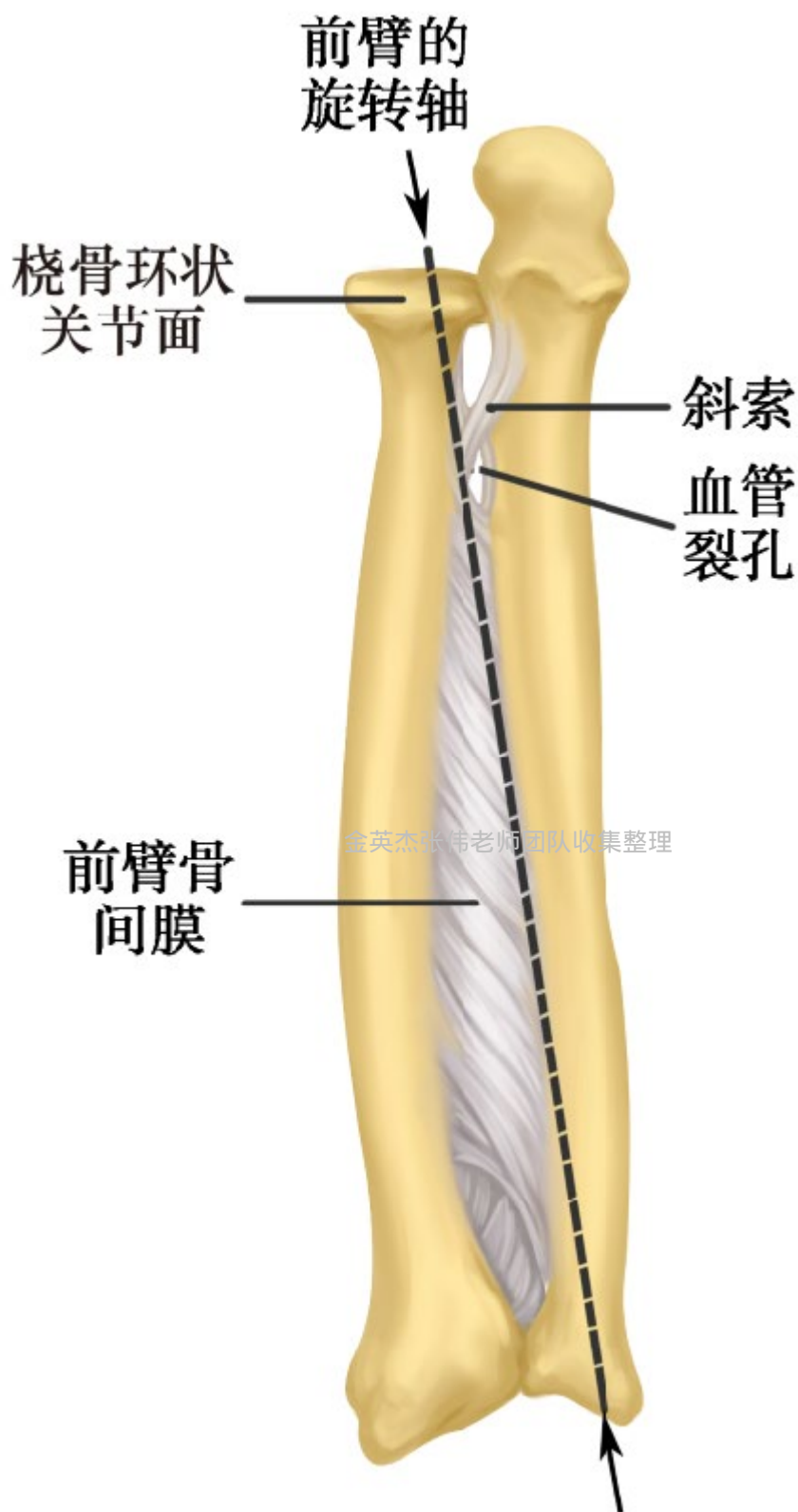


金英杰张伟老师团队收集整理



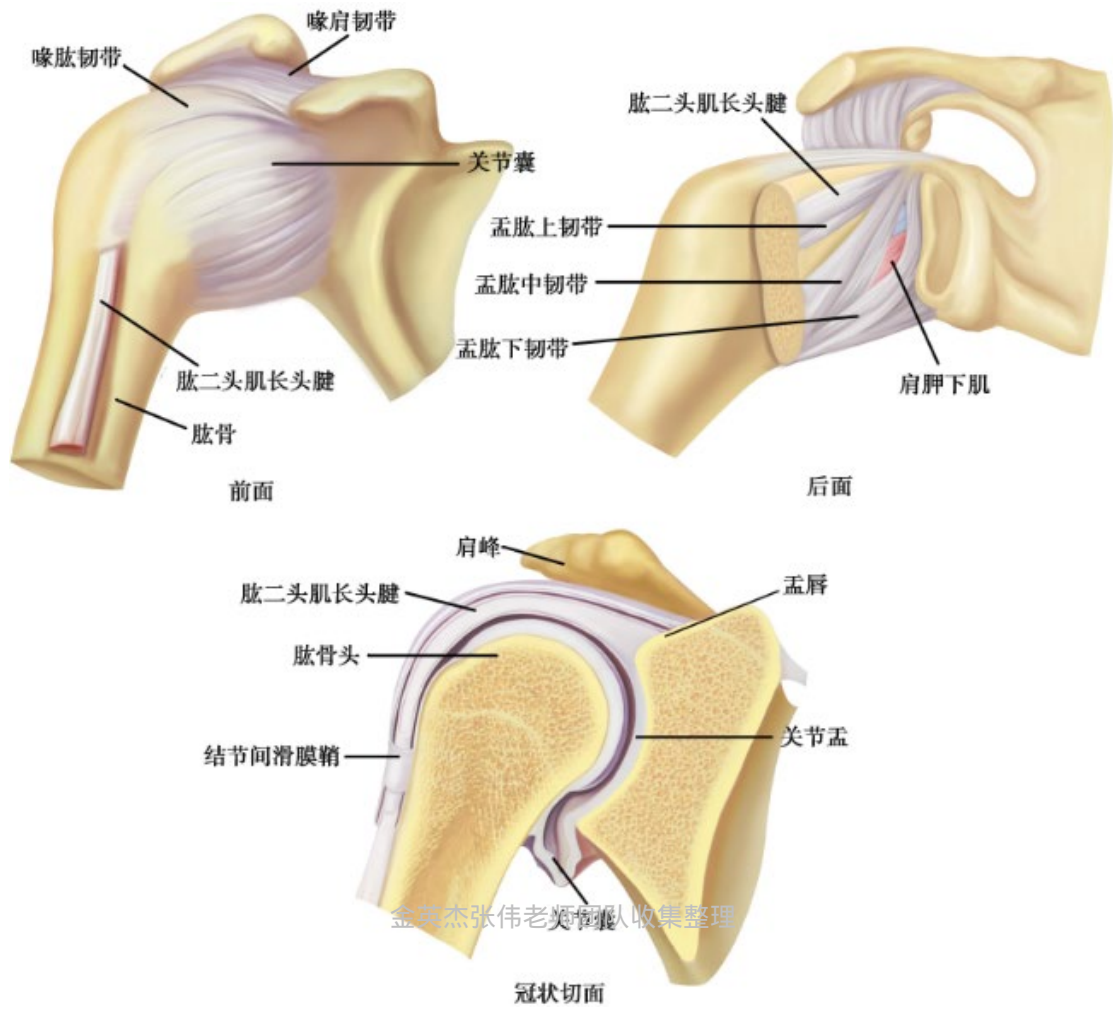
获取更多医考资料请关注





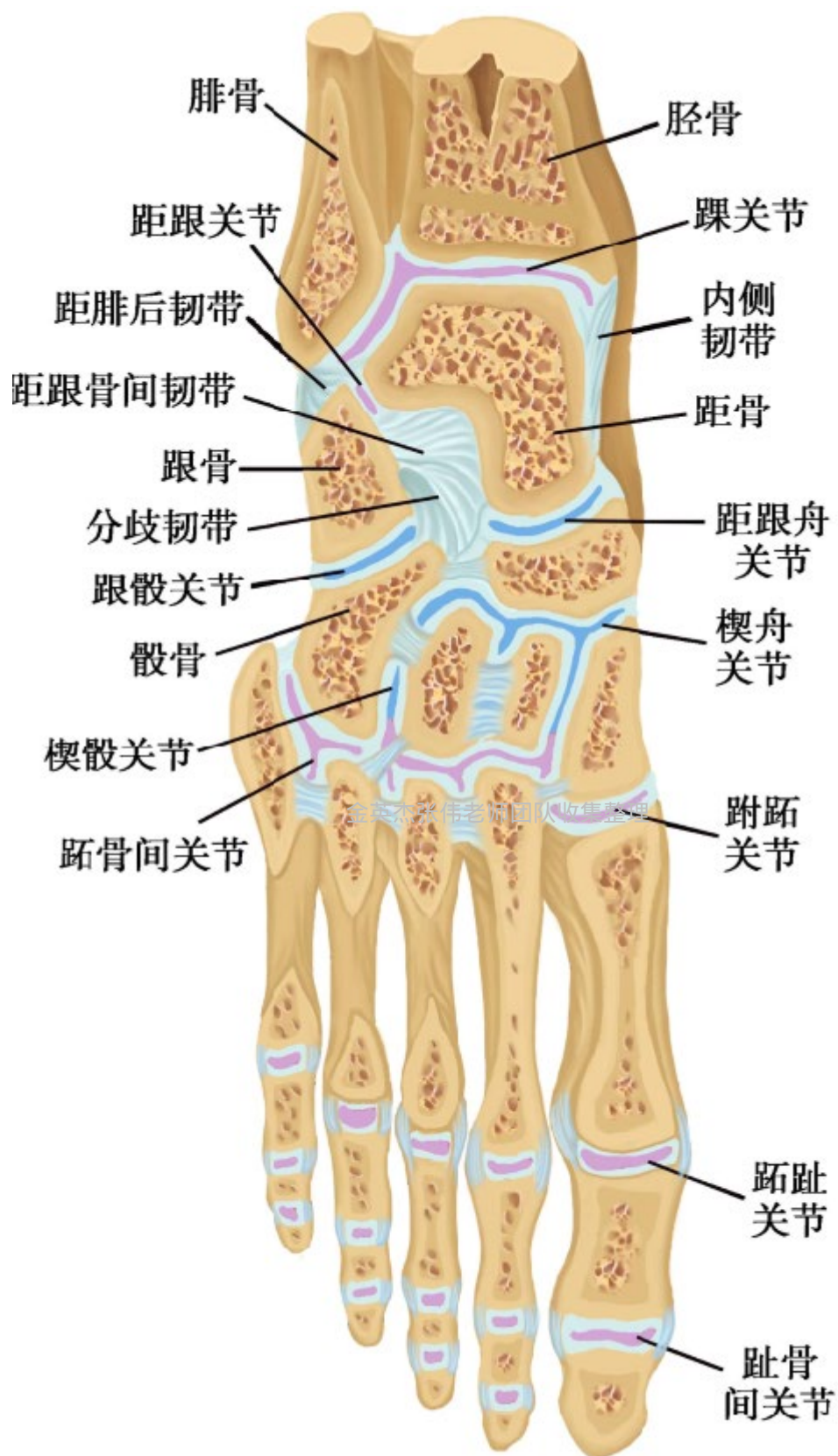
获取更多医考资料请关注





获取更多医考资料请关注

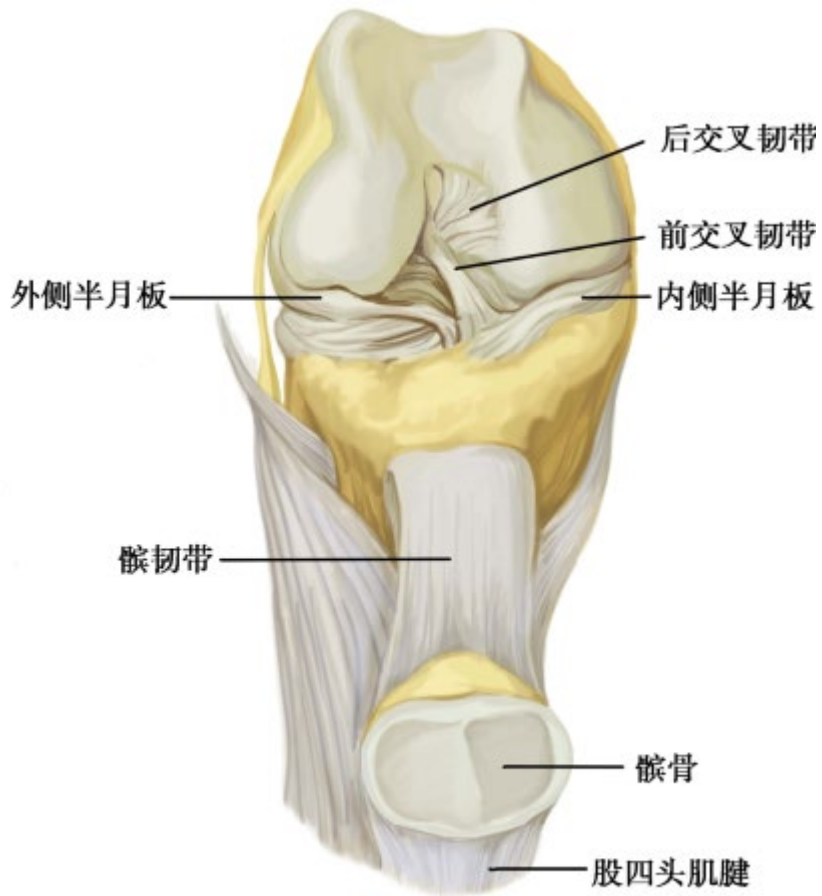




金英杰张伟老师

获取更多医考资料请关注





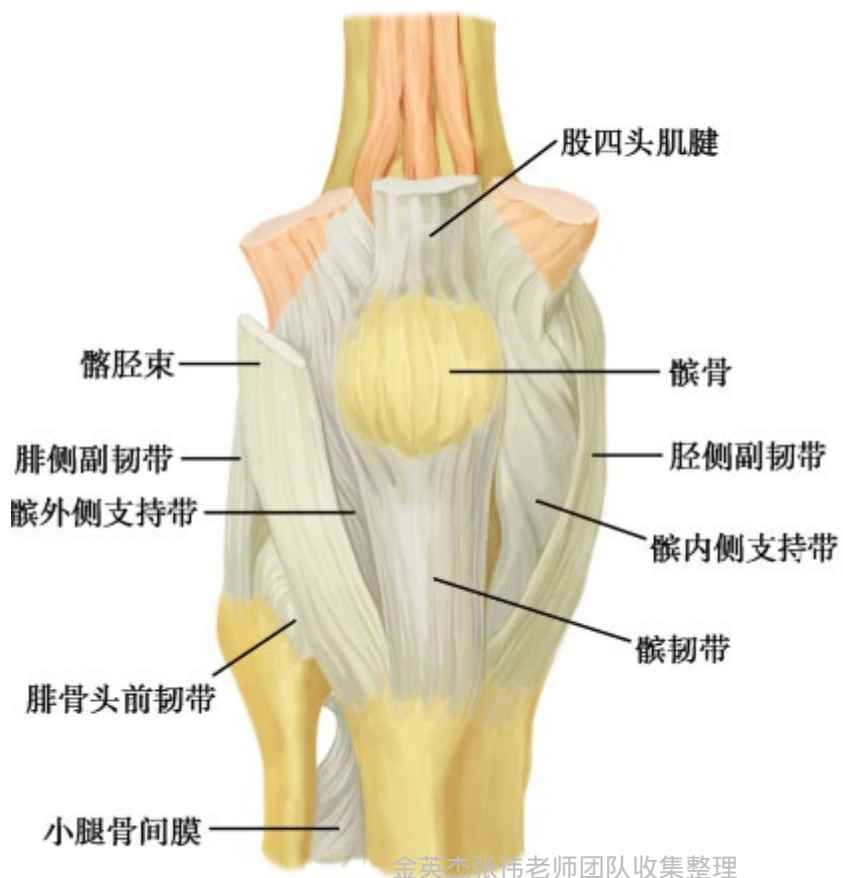
金英杰张伟老师团队收集整理

前面



获取更多医考资料请关注





股四头肌腱
 髌胫束
 腓侧副韧带
 髌外侧支持带
 腓骨头前韧带
 小腿骨间膜
 髌骨
 胫侧副韧带
 髌内侧支持带
 髌韧带

金英杰张伟老师团队收集整理

前面



金英杰张伟老师

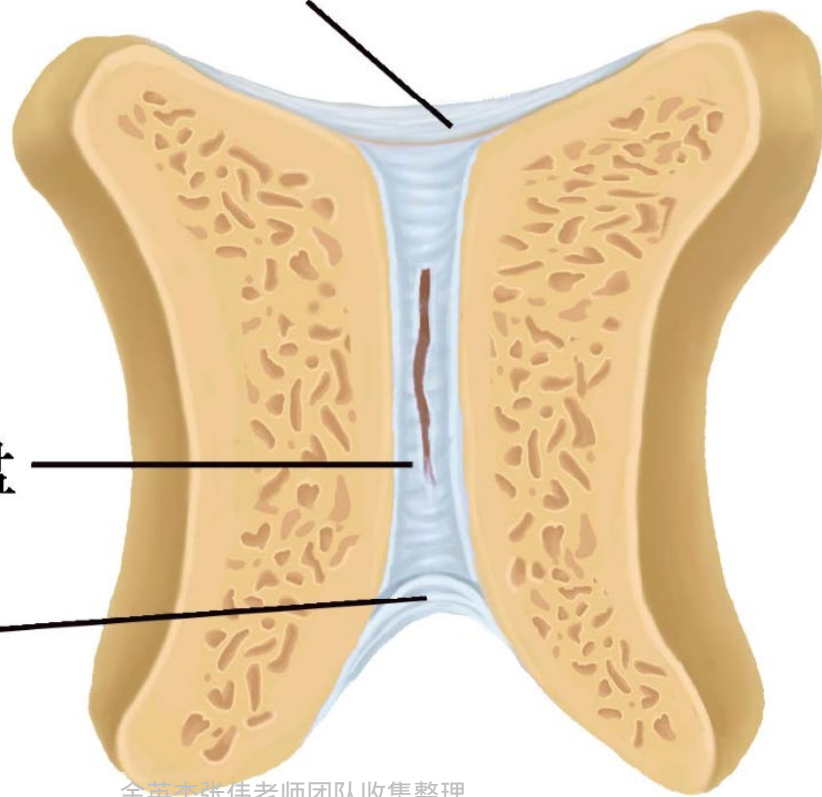


获取更多医考资料请关注

耻骨上韧带

耻骨间盘

耻骨弓状韧带



金英杰张伟老师团队收集整理



金英杰张伟老师

肱骨

肱骨外上髁

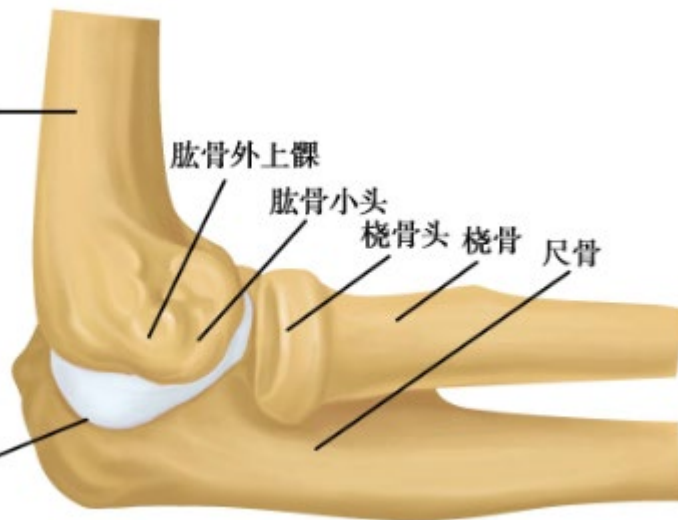肱骨小头

桡骨头

桡骨

尺骨

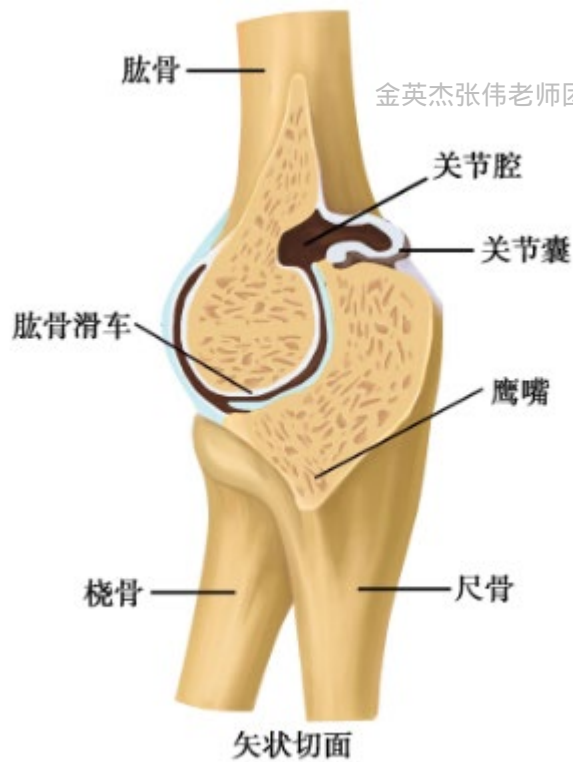
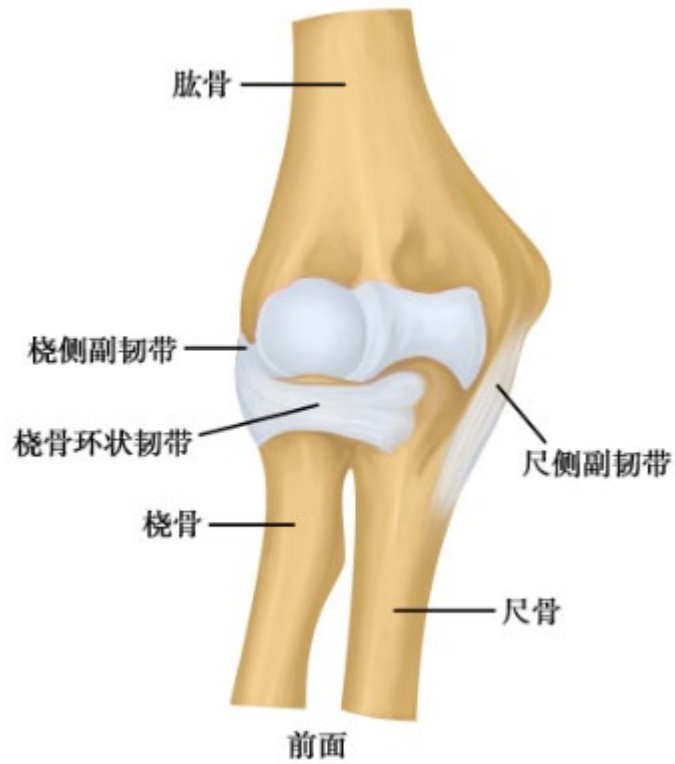
滑车切迹



侧面

获取更多医考资料请关注





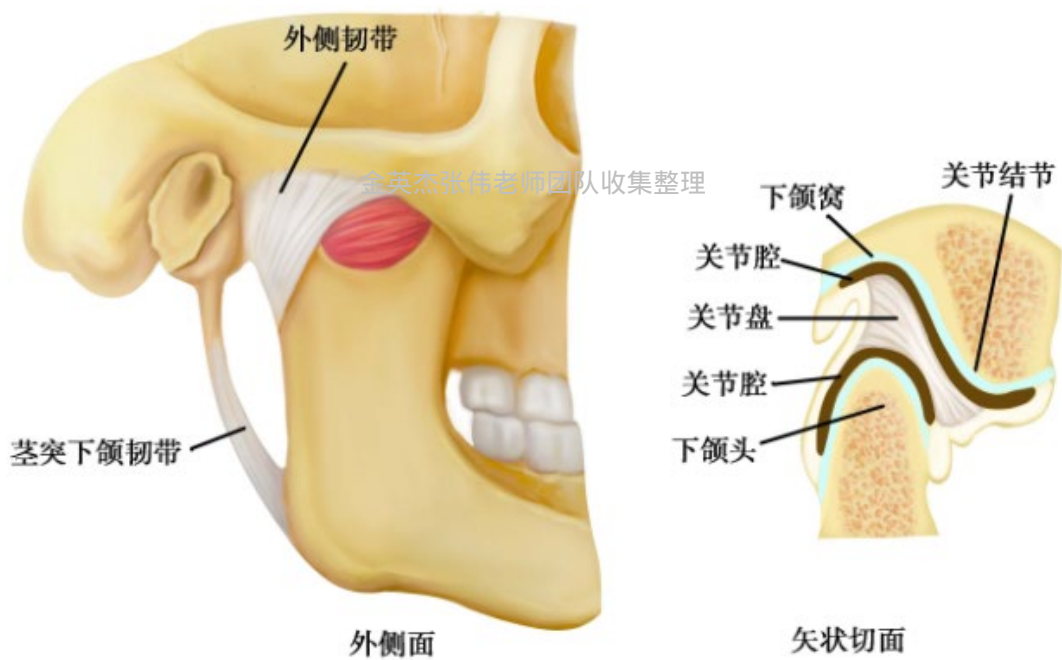
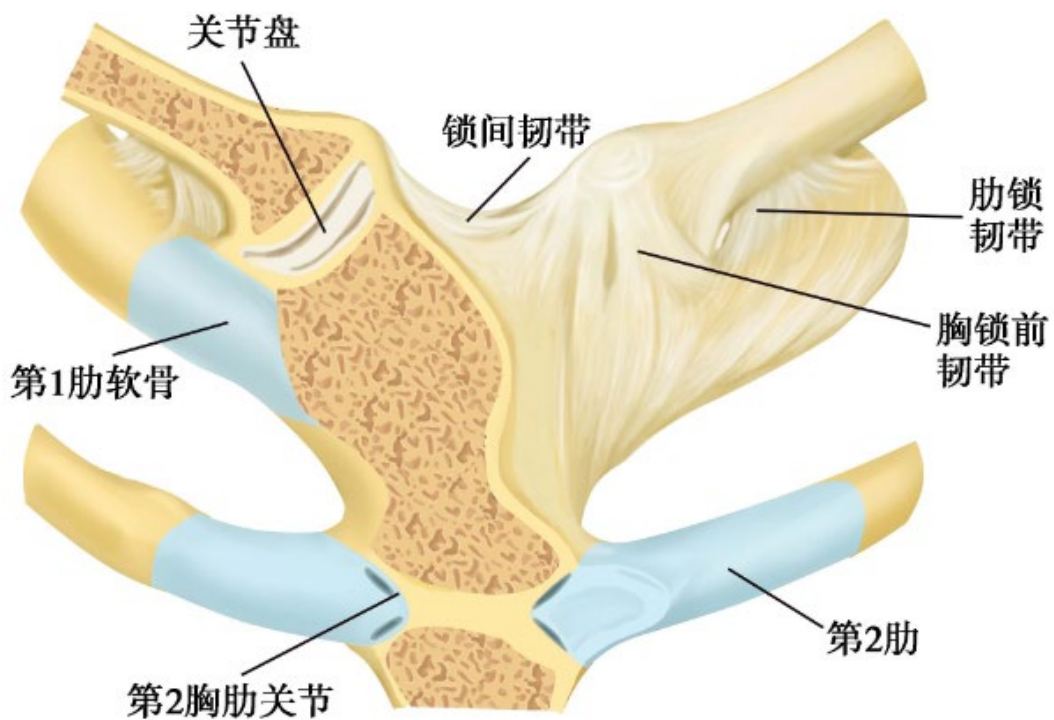
金英杰张伟老师团队收集整理



金英杰张伟老师

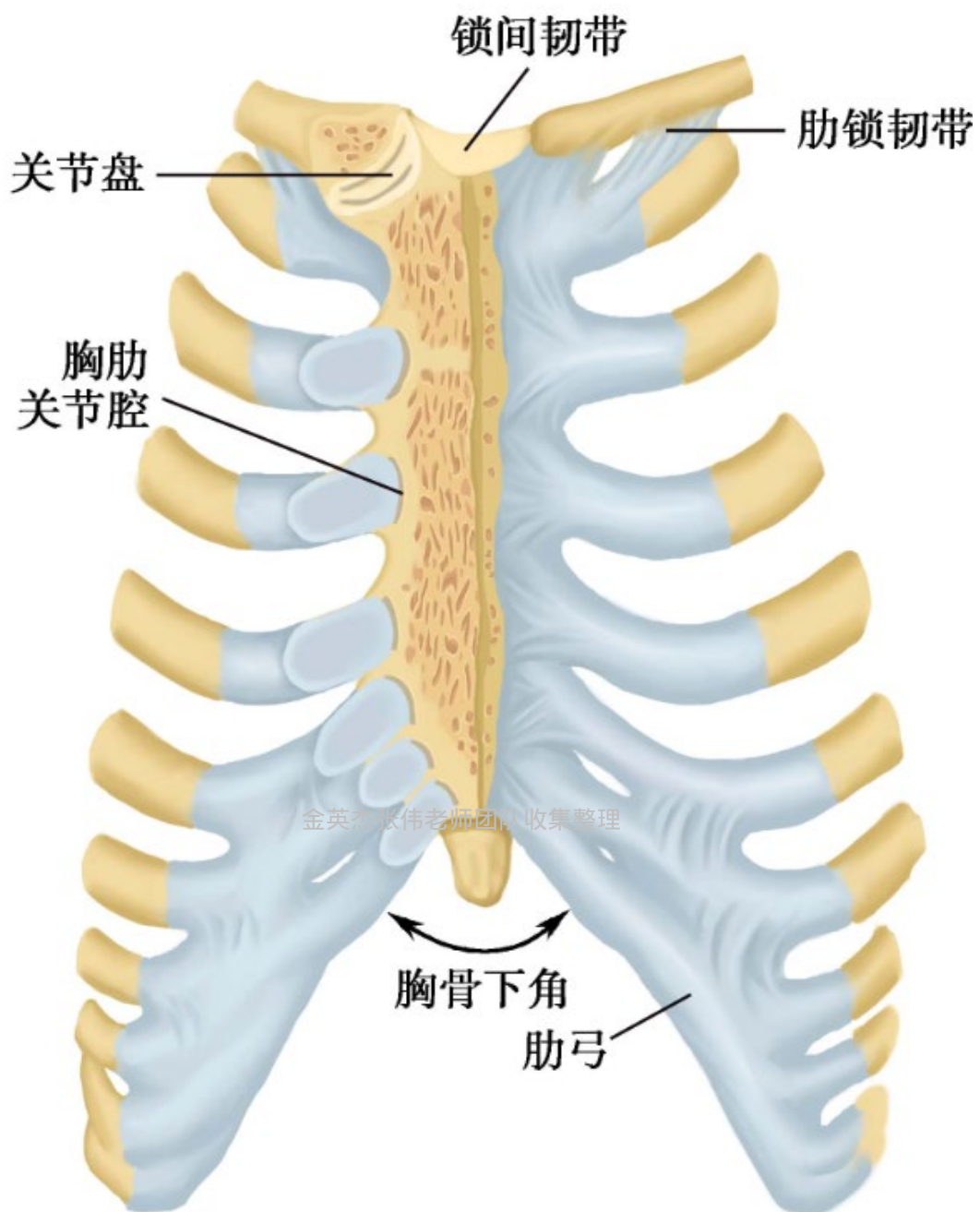
获取更多医考资料请关注





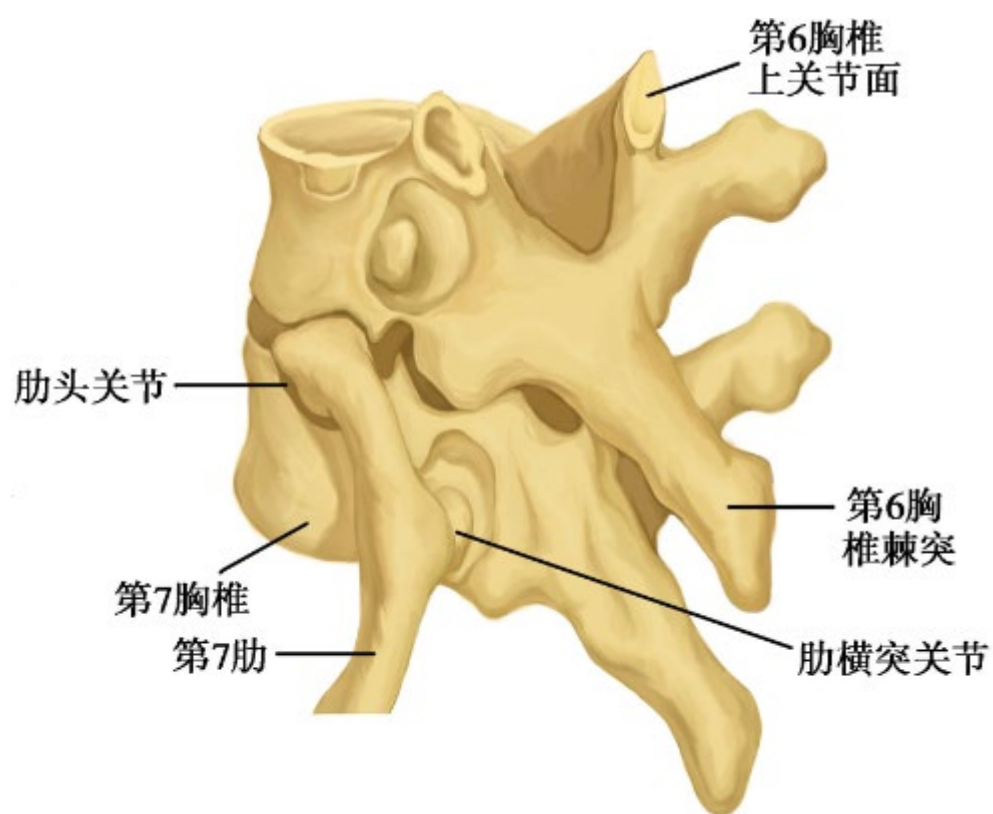
获取更多医考资料请关注



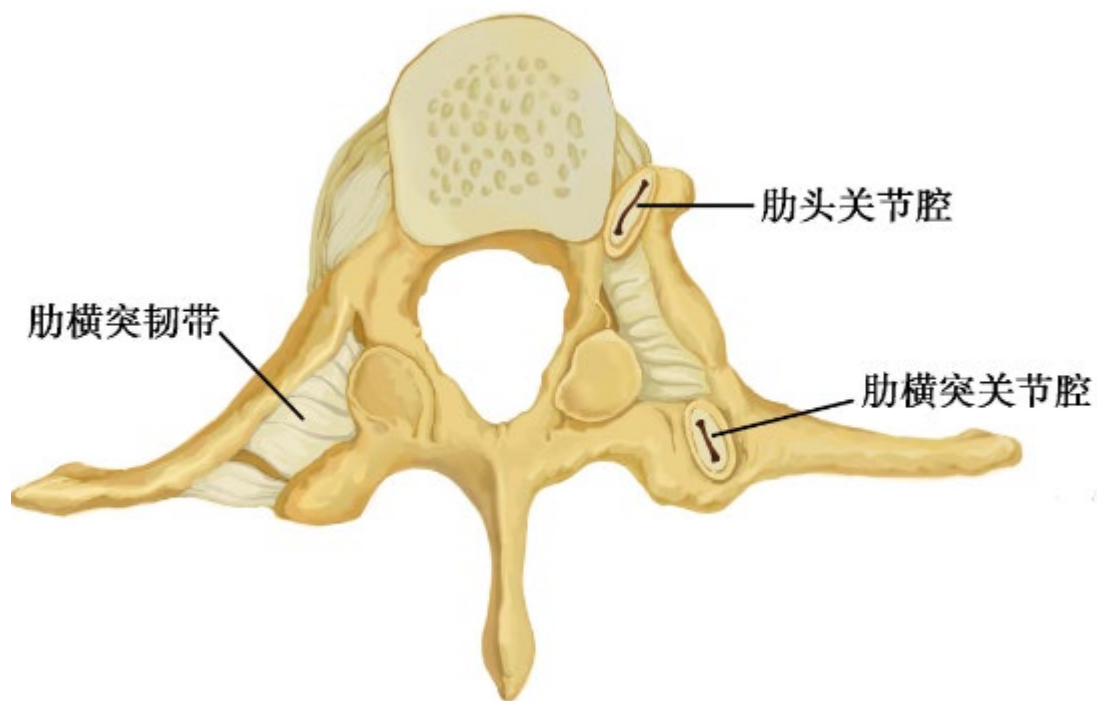


获取更多医考资料请关注

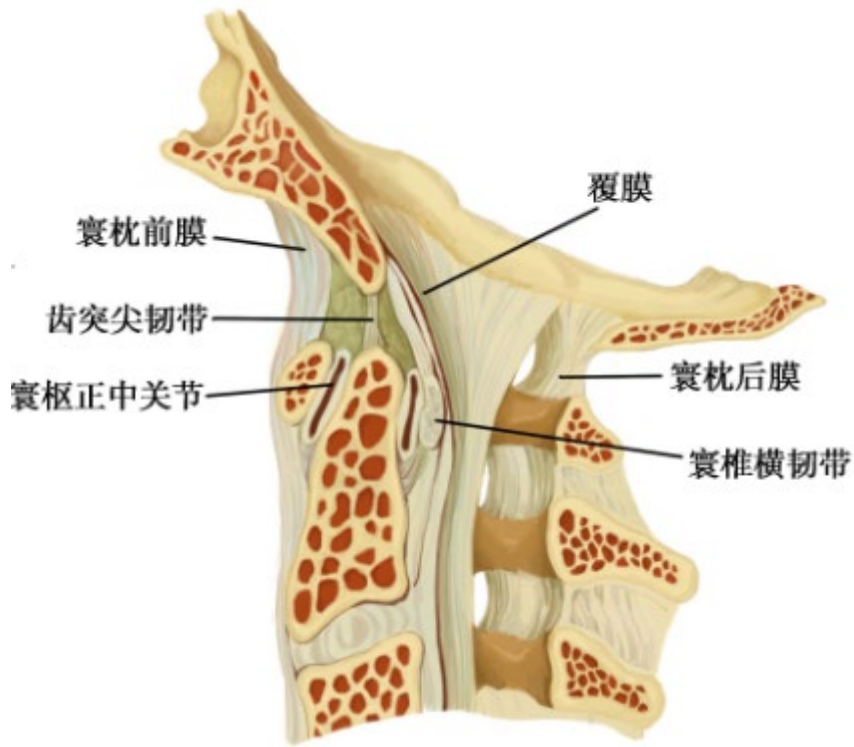
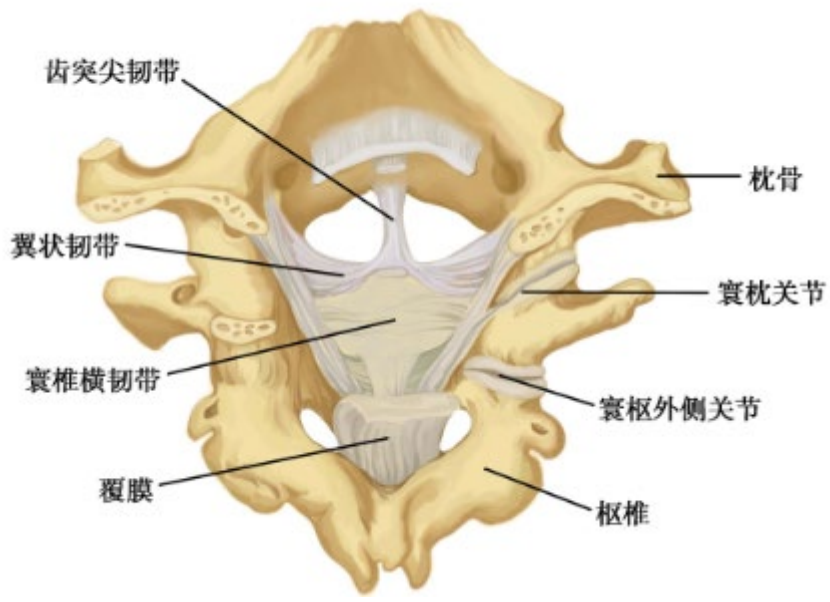


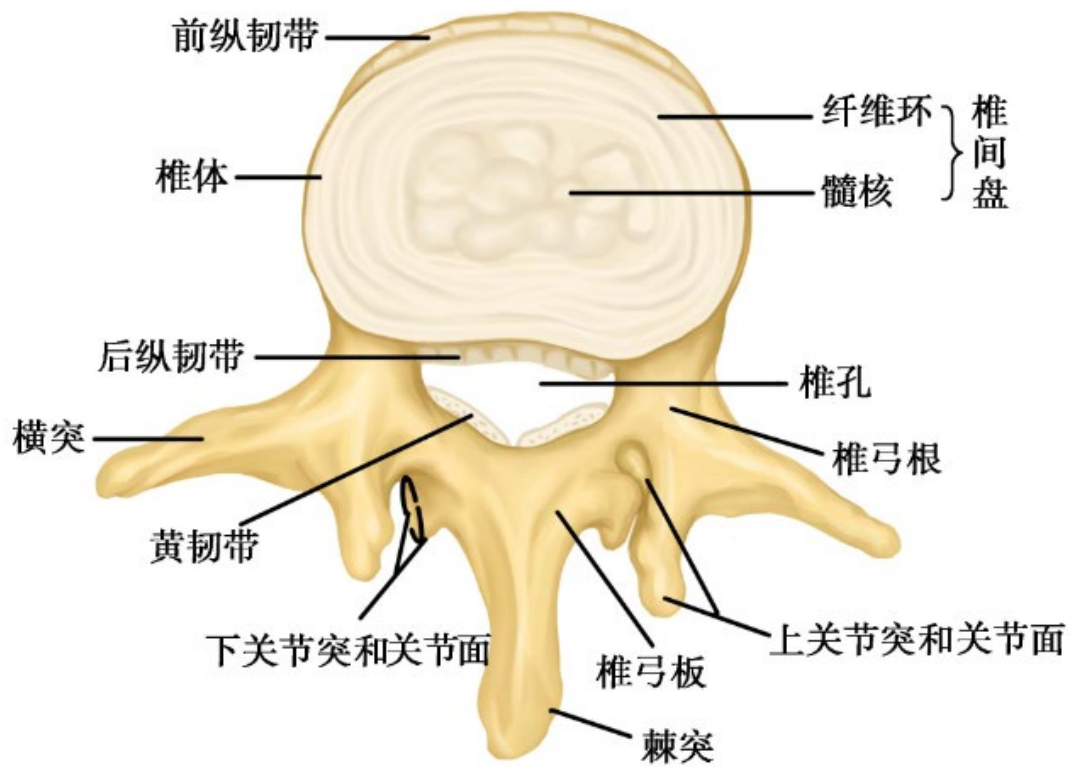
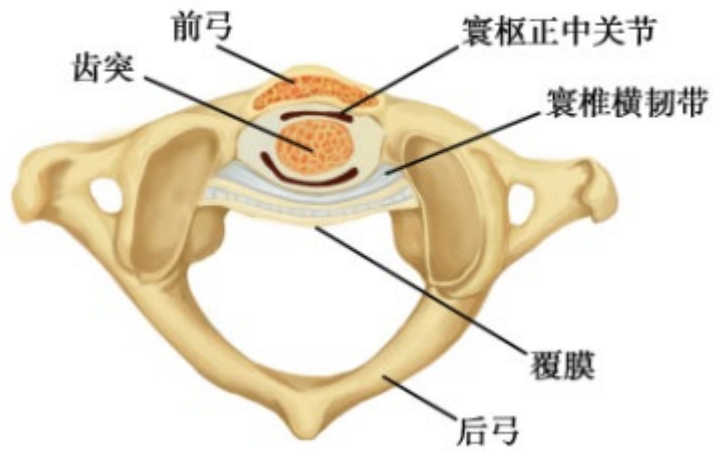


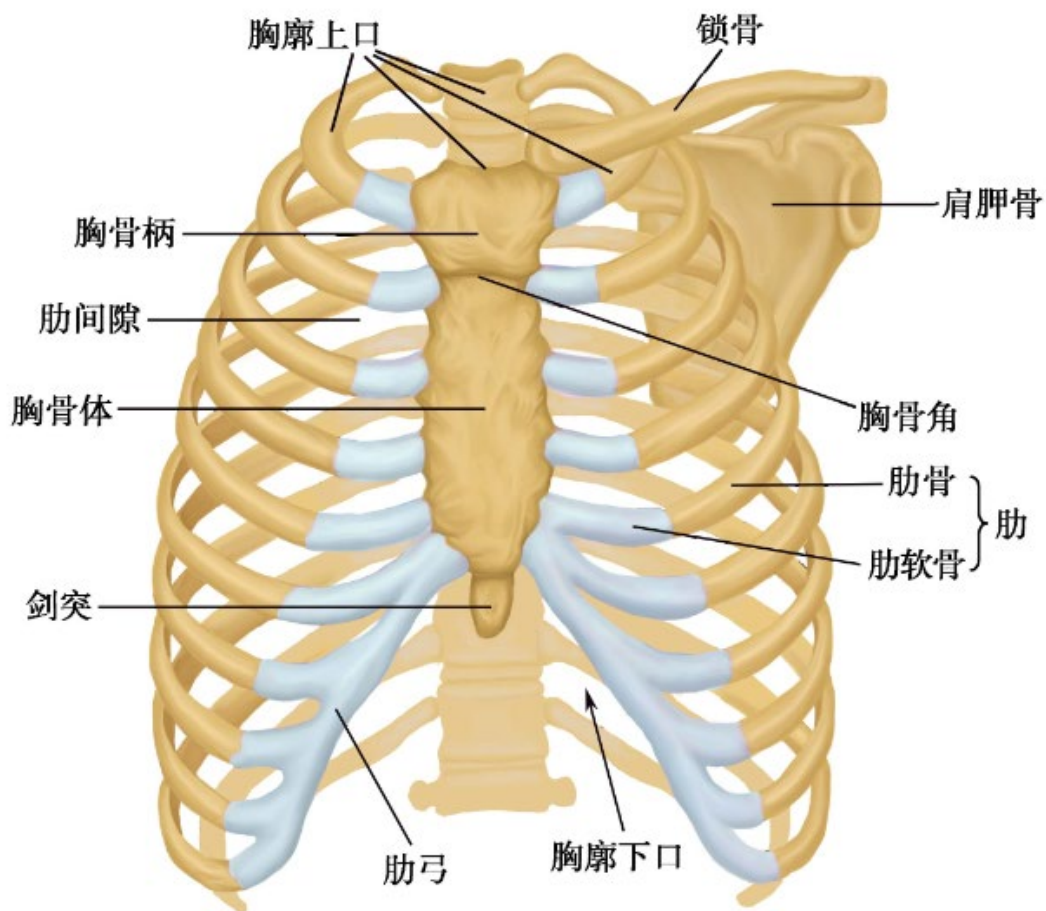
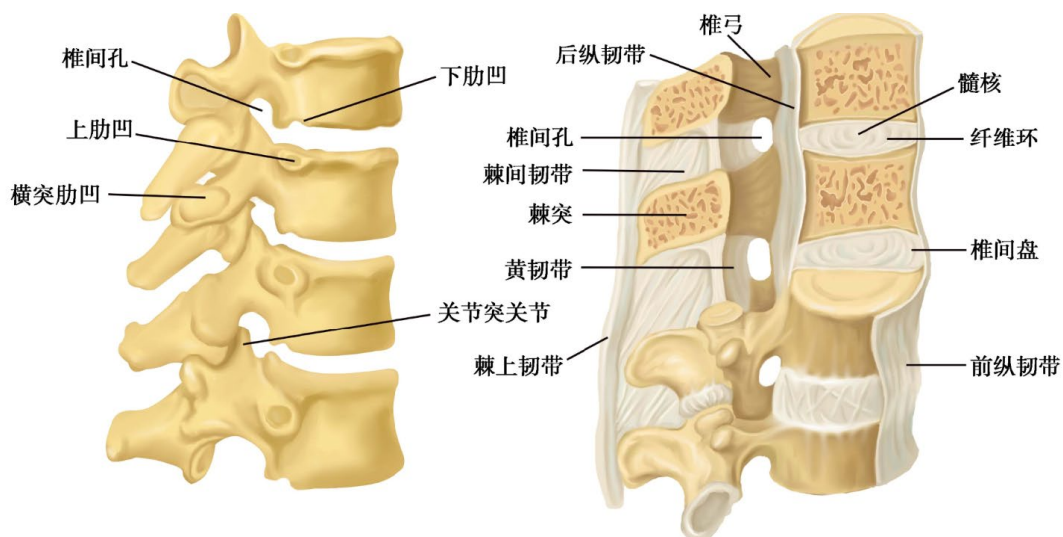
侧面

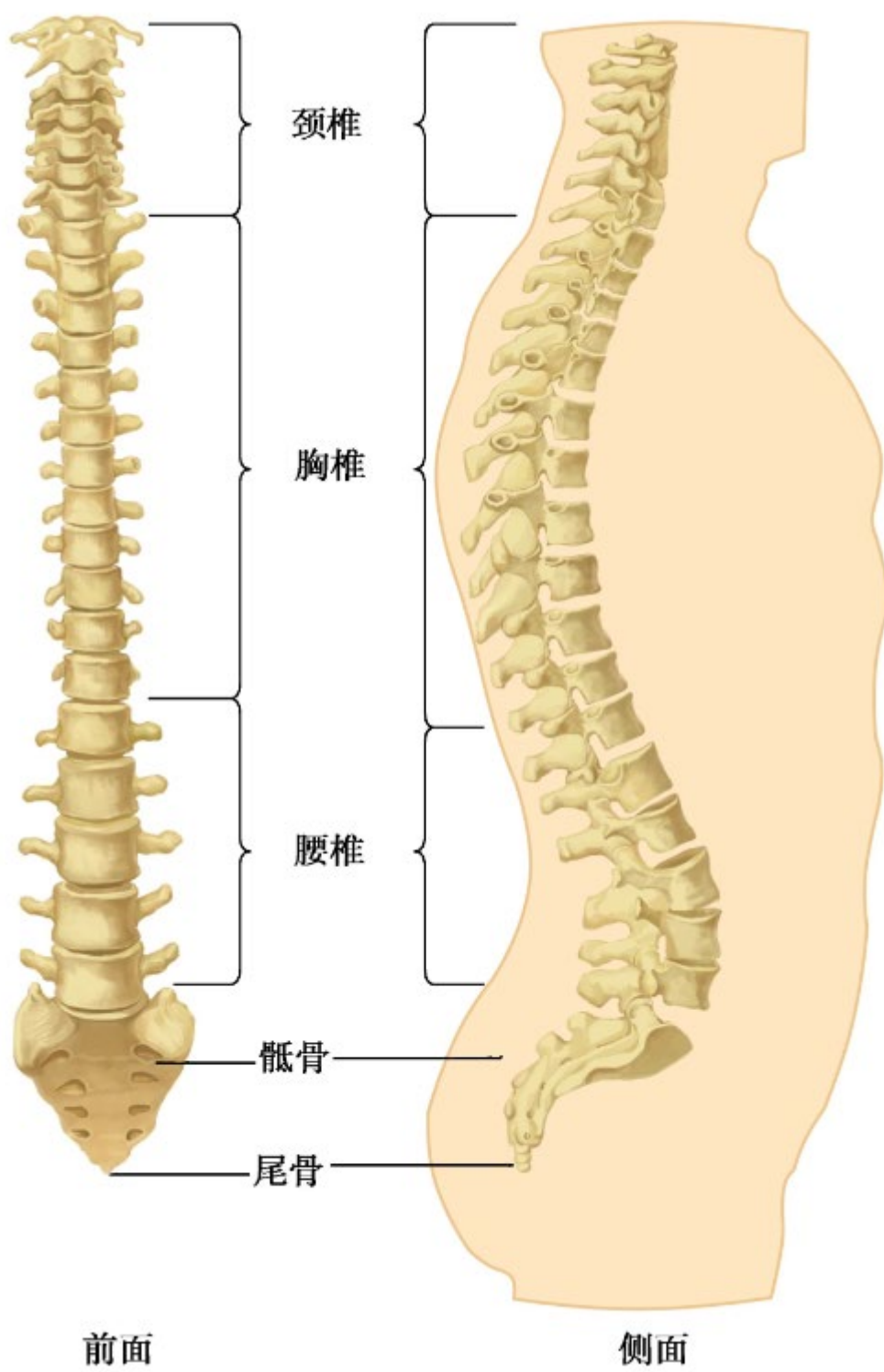


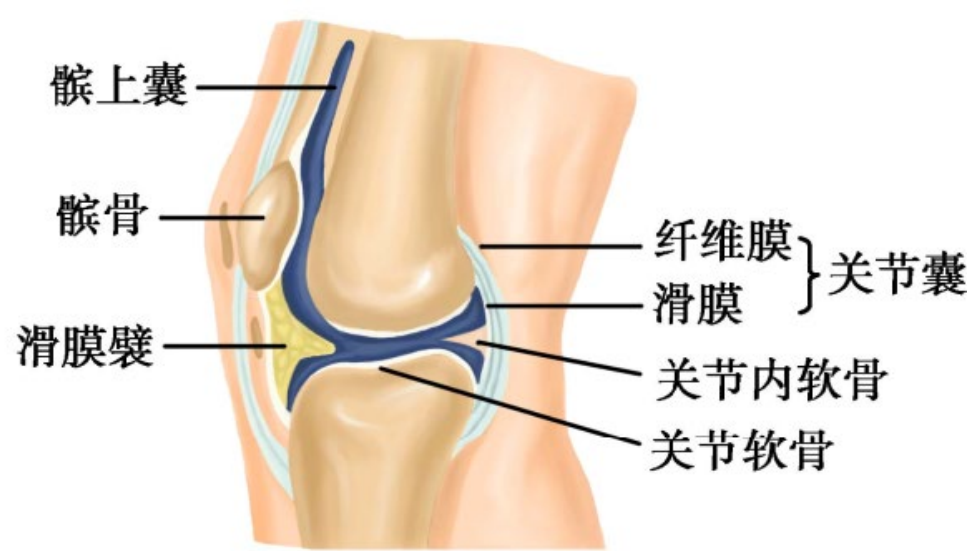
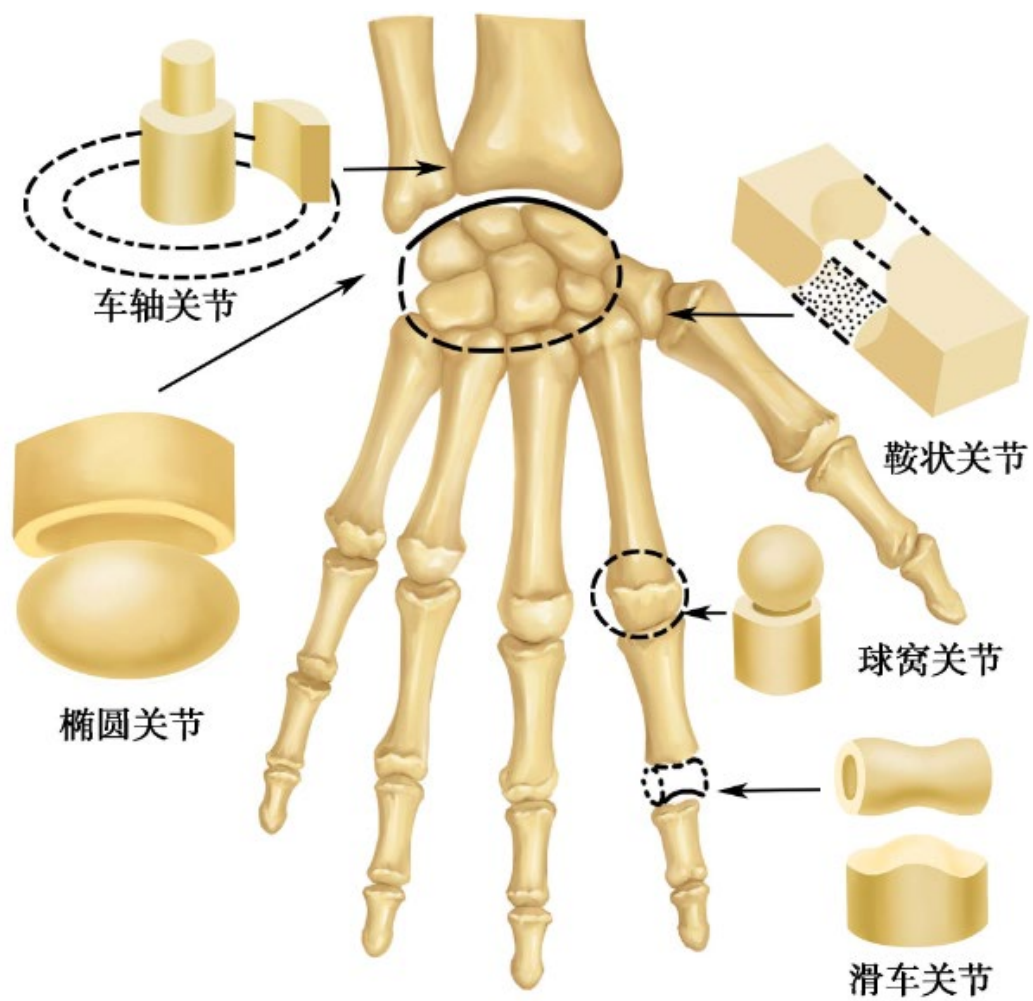
上面



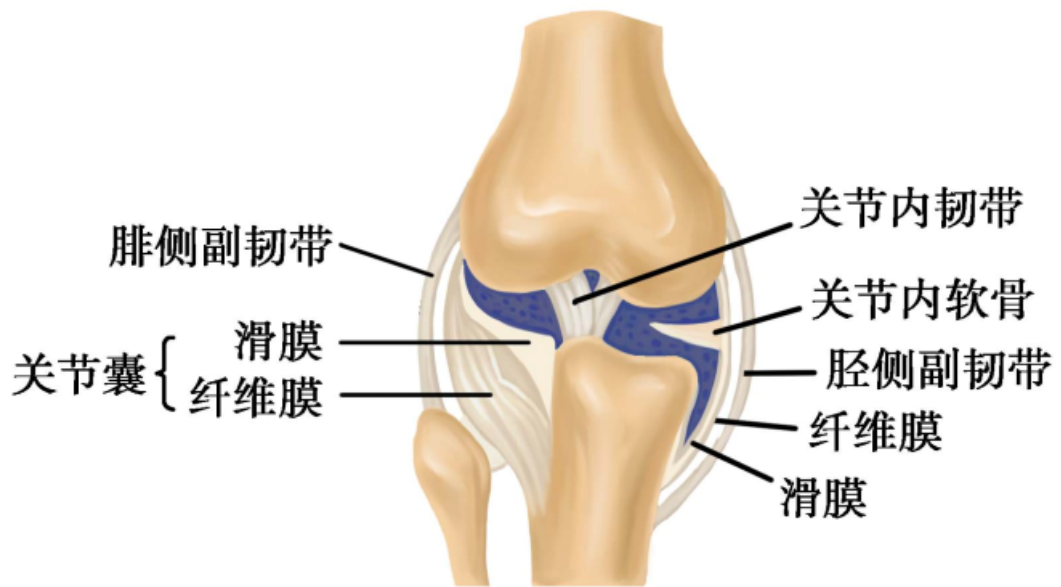
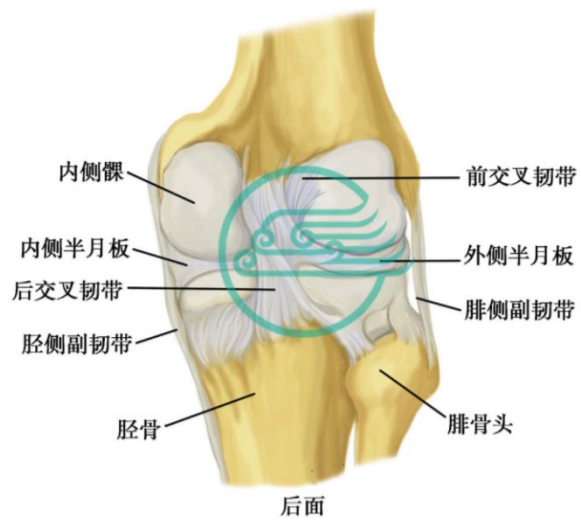


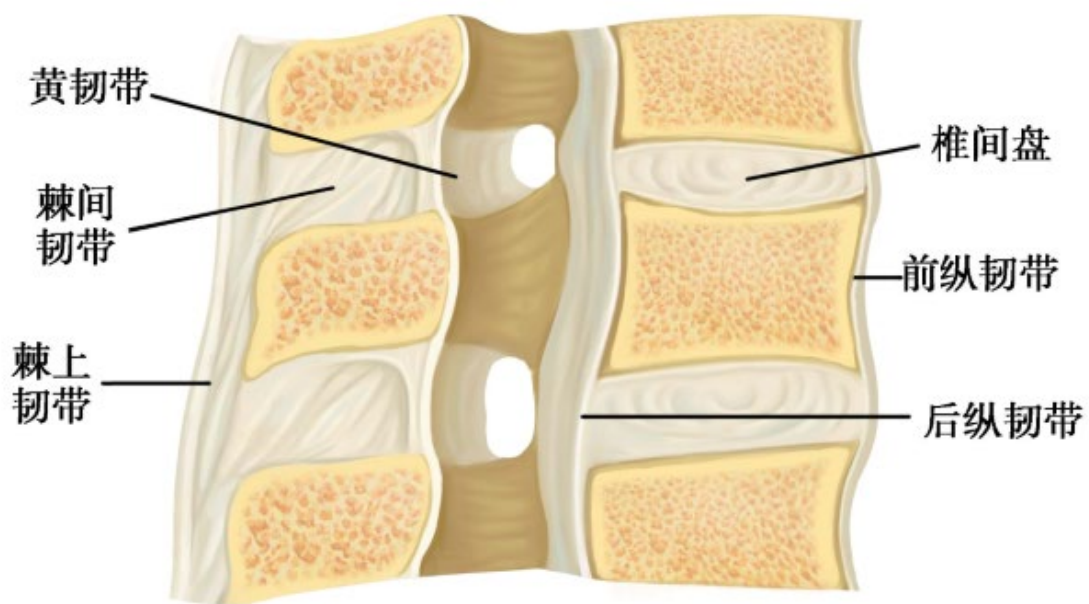




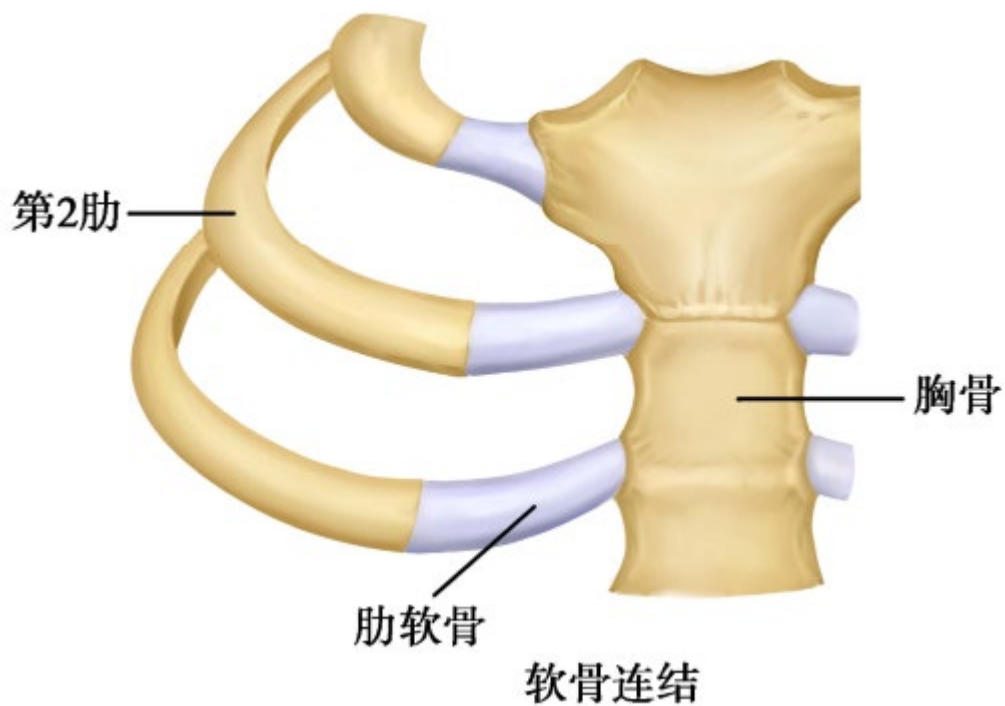


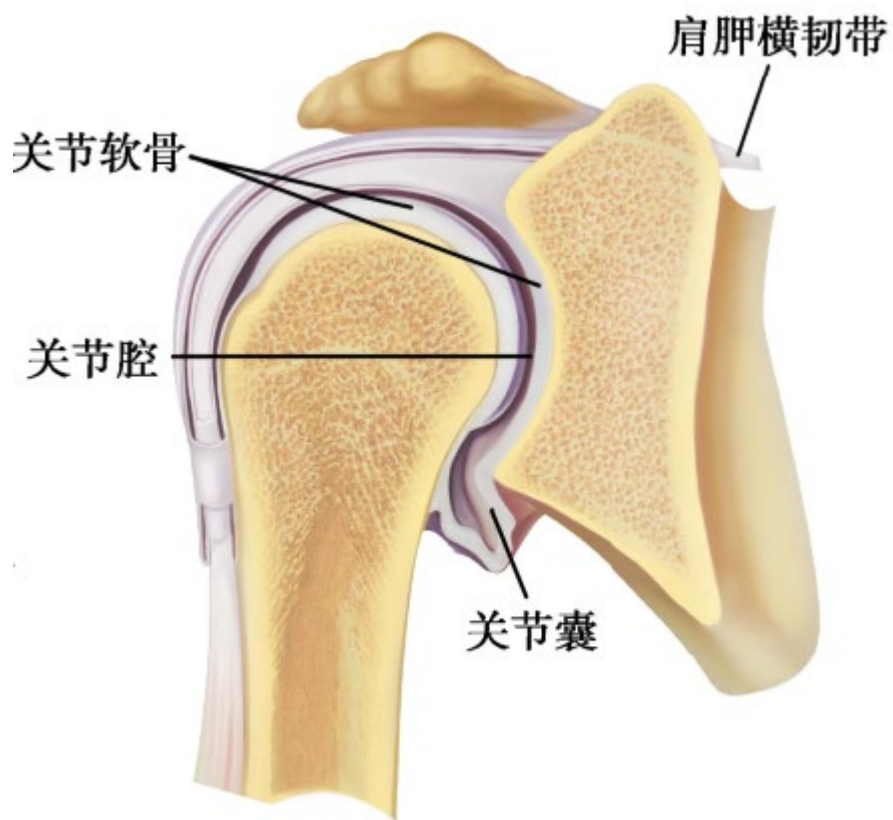
侧面



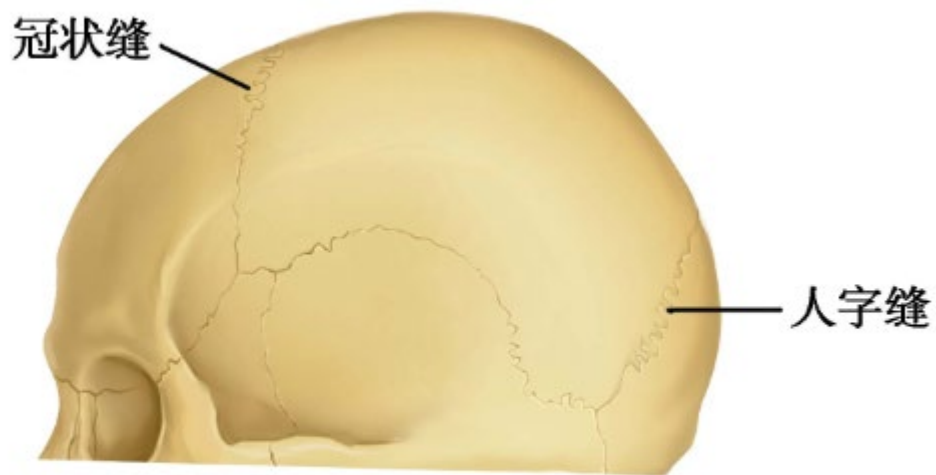


纤维连结





滑膜关节



缝

骨学

